

Multiple Cavernous Angiomas Located In The Cerebral Hemispheres And The Posterior Fossa: A Case Report And Review Of The Literature

CANAN AYKUT, SEVİNÇ AKTAN, ÖNDER US,

Department of Neurology, Marmara University, School of Medicine İstanbul, Türkiye.

Abstract : A case of multiple intracerebral cavernous angioma with brain stem and cerebellar lesions is presented with a six-year follow-up. Cerebral cavernous angiomas are rarely multiple and it is unusual to find in the brain stem and cerebellum. Lesions were demonstrated with computed tomography (CT) and magnetic resonance imaging (MRI.) No significant changes were seen in the radiological ap-

pearance of the lesions after six years. The clinical presentation and radiographic features of cerebral cavernous angiomas are discussed, along with a review of the literature.

Key Words : Cavernous angioma, Computed tomography, Magnetic resonance imaging, Posterior fossa.

INTRODUCTION

Cerebral cavernous angiomas are rare lesions; they constitute 3% to 13% of intracranial vascular malformations (6). Cavernous angiomas may affect any part of the central nervous system and usually present with seizures, focal signs or haemorrhage (1,8). These lesions may bleed, calcify or thrombose (8). Although they may involve any part of the central nervous system, lesions located in brain stem and cerebellum are rarely encountered (9). We present a patient with multiple cavernous angioma in both hemispheres, cerebellum and brain stem with a six-year follow-up.

CASE REPORT

A 60-year-old man, complained of progressive gait and speech disturbances and urinary incontinence for one year. His family noticed mental deterioration for six months. His history revealed typical complex partial seizures for 20 years. He has been taking carbamazepine 400 mg/d and the seizures were well controlled.

Neurological examination revealed bilateral abduction impairment. Visual acuity was 20/20 in the right eye; 20/400 in the left. No paresis was evident, but the deep tendon reflexes were exaggerated on both upper and lower extremities. He had bilateral palmo-mental, Hoffmann reflexes, extensor plantar responses and dysarthria, gait and left limb ataxia. In the mental state examination, there was a moderate deficit in recall and a few gaps in his recent past memory.

On the EEG, there was mild generalized background slowing activity and paroxysmal spike bursts projected to the frontotemporal regions. CT scans in 1984 and 1990 showed multiple hyperdense lesions with numerous coarse punctate calcifications, no mass effect and no surrounding edema (Fig. 1 a,b,c,d). The largest lesion located in the brain stem had hypodense irregular areas. There was slight enhancement after contrast administration. The size of the lesions slightly increased in 6 years. In MRI in 1990, we detected multiple lesions with decreased signal intensity compatible with calcifications, and lesions in the brain stem and left temporal region were

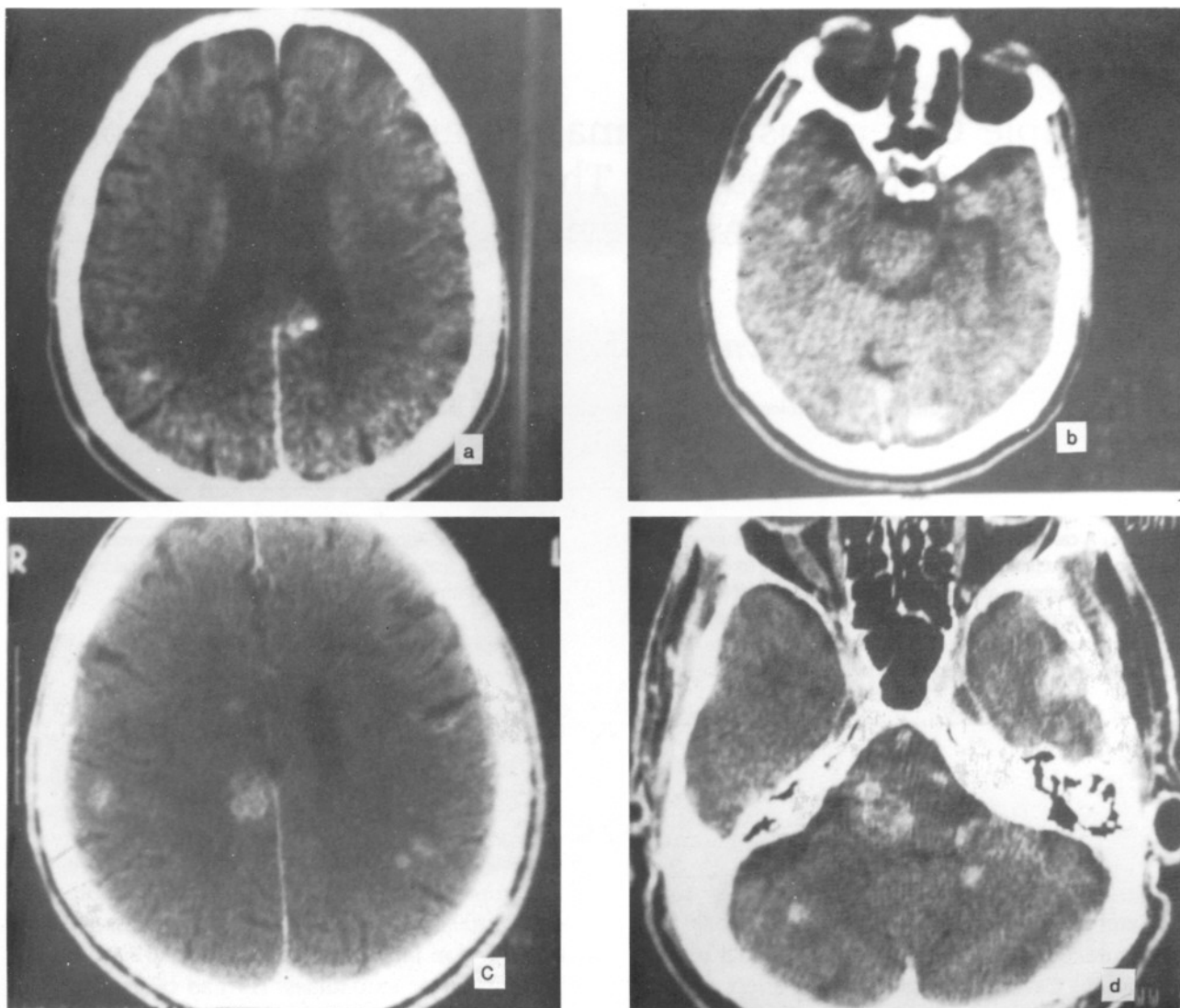


Fig. 1: Computed tomography scans in 1984 (a,b) and in 1990 (c,d) showed multiple hyperdense lesions with numerous coarse punctate calcifications, no mass effect and no surrounding edema. There was slight enhancement after contrast administration.

well circumscribed with a core of mixed signal intensity surrounded by a rim of decreased signal intensity on T2-weighted images (Fig. 2). The Ct and MRI findings suggested cavernous angioma and the step-wise deterioration of clinical findings suggested subsequent haemorrhages from the lesions.

DISCUSSION

Cavernous angioma is a congenital blood-vessel hamartoma consisting of thin-walled sinusoids with no intervening brain parenchyma (5). Essentially, all cavernous angiomas show histological evidence of haemorrhage (6). Thrombosis and calcifications are commonly seen because of the poor blood flow

calcifications are commonly seen because of the poor blood flow (6). Calcification is present in 30% of cases (4). Cavernous malformations are commonly seen within the intracerebral hemispheres, particularly the subcortical regions (7,4). The most commonly involved areas of the brain are frontal, temporal, parietal, and occipital lobes, in that order (1). Cases involving the brain stem and cerebellum are relatively rare. Simard et al presented 138 cases, 20 with posterior fossa and the others with supratentorial lesions. Eleven of Simard's cases had multiple lesions (10). Savaïorda et al reported 36 cases, of which 33 were supratentorial and 3 were in the posterior fossa (9). In our patient, there were multiple supratentorial

angiomas with few lesions in the posterior fossa, two in the brain stem and three in the cerebellum.

The clinical manifestations of cavernous angiomas include seizures, intraparenchymal bleeding and progressive neurological deficits (1,5). Symptoms and signs tend to be progressive due to recurrent haemorrhages (8). Cosgrove et al pointed out that stepwise deterioration is characteristic for cavernous angioma (2). In this patient, the first symptom, diplopia, might be due to the brain stem lesion which appeared 50 years ago; in subsequent years, complex partial seizures had started and were controlled by adequate medication. In recent years, gait and speech disturbances, bladder dysfunction and mental deterioration were added. We observed bilateral ophthalmoplegia, corticospinal tract signs, cerebellar and bladder dysfunctions.

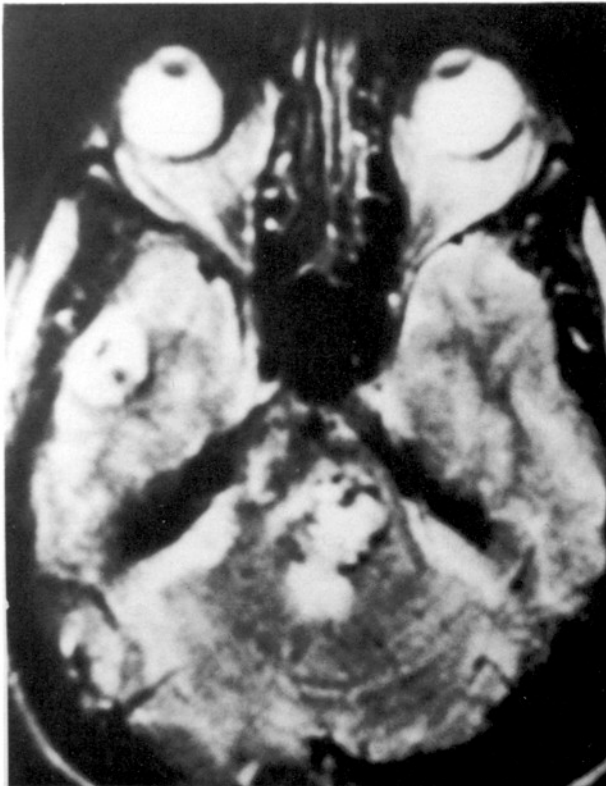

Fig. 2 : Axial magnetic resonance scan in 1990; there are multiple lesions with decreased signal intensity compatible with calcifications and lesions in the brainstem and left temporal region are well circumscribed with a core of mixed signal intensity on T2-weighted image.

Cerebral angiography is normal in approximately one third of patients with verified cavernous angioma (6). Prolonged injection angiography may demonstrate feeding arteries, a capillary blush and slight

neovascularity (6,4). Typical CT findings in cavernous angiomas are irregular hyperdense and partially calcified lesions with fairly homogenous enhancement (6,4). There is usually no mass effect or surrounding edema unless recent haemorrhage is present (4). MRI appears to be a more useful procedure for demonstration and diagnosis of cavernous angiomas particularly for posterior fossa lesions (6,8,1). There are well circumscribed lesions with a core of mixed signal intensity surrounded by a rim of decreased signal intensity representing hemosiderin deposits on T2 weighted images (6,8,5). It is believed that more cavernous angiomas will be diagnosed with the use of MRI (8). Follow-up CT and MRI studies should be evaluated to see recurrent haemorrhages and identify newly emerging lesions. Although our patient had progressive neurological deficits, there was no significant difference in the appearance of his lesions of CT scans taken in 1984 and 1990.

Multiple cavernous angiomas should be considered as a cause of complex partial seizures, ophthalmoplegia, stepwise mental and neurological deterioration as in our patient. As angiography is often unrevealing, CT scan and especially MRI examinations should be carried out and appropriate management should then be provided.

Correspondence : Dr. Canan AYKUT,
Nöroloji Anabilim Dalı,
Marmara Üniversitesi Hastanesi,
81190. İstanbul

REFERENCES

1. Bicknell JM: Familial cavernous angioma of the brain stem dominantly inherited in Hispanics. *Neurosurgery* 24:102-105, 1989
2. Cosgrave GR, Bertrand G, Fontine S, Rabitaille Y, Melanson D. Cavernous angioma of the spinal cord. *J Neurosurg* 68:31-36, 1988
3. Kirkpatrick JB: Comment on Simard JM: Cavernous angioma: A review of 126 collected and 12 clinical cases. *Neurosurgery* 18:172, 1986
4. Lee SH, Rao KCVG: Cerebral vascular anomalies. *Cranial computed tomography and MRI*. Second Edition. McGraw Hill 1987, p:622
5. Pozzati E, Giuliani G, Nuzzo G, Poppi M: The growth cerebral cavernous angiomas. *Neurosurgery* 25:92-97, 1989
6. Quattrocchi KB, Kissel P, Ellis WG, Frank EH: Cavernous angioma of the tentorium cerebelli. *J Neurosurg* 71:935-937, 1989
7. Roda JM, Alvarez F, Isla A, Blazquez MG: Thalamic cavernous malformation. *J Neurosurg* 647-649, 1990
8. Saito N, Yamakawa K, Sasaki T, Saito I, Takakura K: Intramedullary cavernous angioma with trigeminal neuralgia: A case report and review of the literature. *Neurosurgery* 1989; 25:97-101, 1989
9. Savoiardo M, Strada L, Passerini A: Intracranial cavernous angiomas: Neuroradiological review of 36 operated cases. *AJNR* 4:945-949, 1983
10. Simard JM, Garcia-Bengochea F, Ballinger WE, Mickel JP, Quishing RG: Cavernous angiomas: A review of 126 collected and 12 new clinical cases. *Neurosurgery* 18:162-172, 1986