

# Multilevel Laminotomy in the Treatment of Children With Spinal Dysraphism and Associated Mild Spinal Deformity

## Hafif Spinal Deformite ile Birlikte Ortaya Çıkan Spinal Disrafizimli Çocukların Tedavisinde Çok Seviyeli Laminotomi Uygulanması

ÇETİN REFİK KAYAOĞLU, YUSUF TÜZÜN, ERHAN TAKÇI, MAHMUT ARIK,  
PINAR POLAT, HAKAN HADİ KADIOĞLU, İSMAİL HAKKI AYDIN

Atatürk University, Medical Faculty, Departments of Neurosurgery (ÇRK, YT, ET, MA, HHK, İHA)  
and Radiology (PP), Erzurum, Turkey

Received : 16.11.1999 ⇔ Accepted : 19.1.2000

**Abstract:** Fourteen pediatric patients with spinal dysraphism and associated mild spinal deformities underwent multilevel laminotomy in the years 1993 through 1998. At the time of surgery, the 8 male and 6 female patients ranged from 0 to 2 years of age, and their mean age was 5.3 months. All were evaluated using the Spina Bifida Neurological Scale, and all except two individuals with minimal neurological deficits were in good neurological condition prior to surgery. Cervical meningocele was detected in two individuals, lipomyelomeningocele in six, dermal sinus tract in three, thoracic meningocele in two, and type II split cord malformation in one patient. Each individual was followed for at least 6 months after surgery. We obtained serial x-rays to track the patients' progress, taking the first films on day 1 postsurgery and the others monthly thereafter throughout follow-up. There were no operative deaths and only one patient developed a wound infection. The study showed that multilevel laminotomy is a very efficient means of realigning and healing the spine in children with mild spinal deformity.

**Key words:** Children, laminotomy, spinal dysraphism

**Özet:** Spinal disrafizimli ve hafif spinal deformiteleri olan 14 pediatrik hastaya 1993-1999 yılları arasında çok seviyeli laminotomi uygulandı. Sekizi erkek altısı kız ve ameliyat esnasında ortalama yaşları 5.3 ay olan hastaların hepsi Spina Bifida Nörolojik Skala'sına göre değerlendirildi. Minimal nörolojik defisiti olan iki hastanın dışında hepsinin operasyon öncesi nörolojik durumları iyi idi. Hastaların ikisinde servikal meningocele, altısında lipomeningocele, üçünde dermal sinus traktusu, ikisinde torakal meningocele ve bir hastada da tip-II split kord malformasyonu tespit edildi. Hastalar operasyon sonrası en az 6 aylık bir periyotta takip edildi. Cerrahiyi takiben birinci gün ve sonraki takip evresinde aylık direkt grafiler çekerek hastaların iyileşme durumu izlendi. Operasyona bağlı ölüm olmadı ve sadece bir hastada yara enfeksiyonu gelişti. Çalışmamız, hafif spinal deformiteli çocuklarda çok seviyeli laminotomi işleminin omurga dizilişi ve iyileşmesinde önemli etkiye sahip olduğunu gösterdi.

**Anahtar kelimeler:** Çocuklar, laminotomi, spinal disrafizm

### INTRODUCTION

It may seem intuitive that multilevel laminotomy would be superior to multilevel laminectomy for preventing the progression of

postoperative spinal deformities in children; however, very few studies have focused on this question to date, and only minimal related research has been done in patients with spinal dysraphism (1,2,4,7,8,9).

Treatment of tumors and congenital disorders of the spinal canal often requires extensive surgical exposure (4). Children with spina bifida are usually born with significant spinal deformities and inadequate soft tissue in the spinal area. Even though special care may be taken in planning the surgical approach for the primary lesion, most cases involve significant deformities that will require attention to the architecture of the spine (2). Even a limited laminectomy procedure can lead to kyphosis and scoliosis, serious problems that require reconstruction and vertebral fusion (7).

Some children with spinal dysraphism have only mild spinal deformities. In all cases, it is crucial that every effort be made to reconstruct and preserve the architecture of the spinal column, a structure that is intimately involved in, and essential for normal growth and development. The aim of this study was to analyze our recent experience in treating pediatric patients with spinal dysraphism and associated mild spinal deformity.

### PATIENTS

From 1993 through 1998, 68 pediatric patients underwent spinal canal surgery for spinal dysraphism. Fourteen of these children with spinal deformity underwent multilevel laminotomy. Eight of the 14 were males and 6 were females, and their ages ranged from 2 to 22 months (mean, 5.3 months). We evaluated the patients' neurological status at the time of presentation and throughout follow-up using the Spina Bifida Neurological Scale (SBNS), as described by Oi and Matsumoto (5). Of the 14 total, only two of the six patients with lipomyelomeningocele exhibited neurological deficits. We radiographically assessed each spine with plain radiography, myelography, computerized tomography (CT) and magnetic resonance imaging (MRI) (Figure 1). The patients underwent multilevel laminotomy procedures during which we repaired the dysraphic anomalies and, when necessary, incised the filum terminale to release the spinal cord.

### OPERATIVE TECHNIQUE

The laminotomy performed was similar in many respects to the technique that Raimondi described in 1976. In each case, the initial phase of surgery started in the defective section of spine and extended superiorly to the point where the spine was normal. At each level operated, laminar osteotomy was carried out using a high-speed drill to penetrate

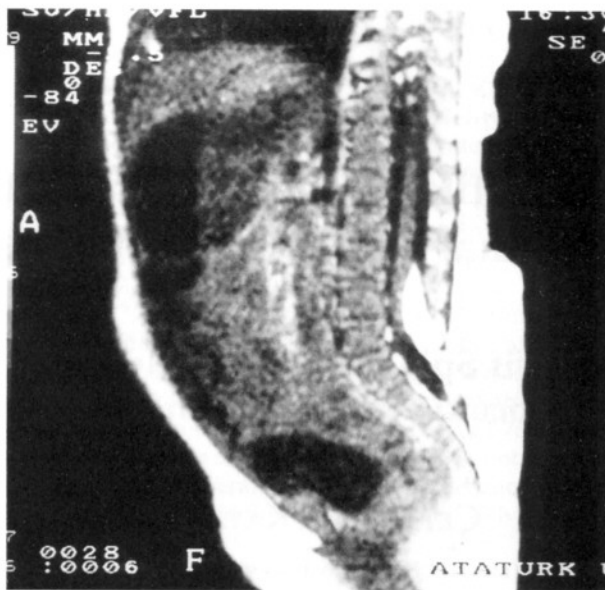


Figure 1: A midsagittal T1-weighted MR image of a dorsally inserting lipoma.

the vertebral bone where the pedicles meet the laminae on both sides of the dorsal part of the vertebral arch. After one side was drilled, a curved dissector was inserted beneath the lamina in order to preserve the integrity of the epidural vessels and the neural tissue. After the process was completed for the lamina on one side, the same procedure was done on the other side. Once both laminae were detached, we carefully raised the laminar flap and placed cotton pads along the ventral surface of the dorsal part of the vertebral arch to facilitate dissection and protect the dura and epidural vessels. Different from Raimondi's technique, we did not completely remove the laminar flap but only partially lifted it. Also, we did not sever the interspinous ligament between the most superior portion of spine to be removed and the spine that would be left intact.

In the second phase of surgery, once the work on the superior section of spine was complete, another laminar flap was lifted in the defective region and the same steps were carried out in the inferior direction, leaving the interspinous ligament intact between the most inferior portion of spine to be removed and the spine that would remain (Figure 2).

After the surgical procedure was completed in both directions, the laminar flaps were returned to their original anatomical positions. Similar to Raimondi's method, we drilled symmetrical burr

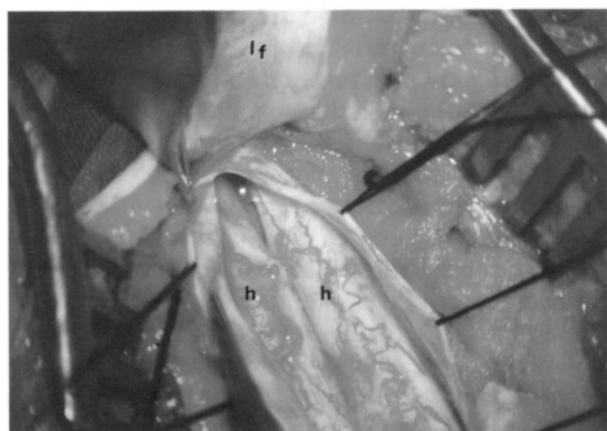


Figure 2: The surgical appearance of the split cord and the septum. h: hemicord, lf: laminar flap

holes on both sides of the laminotomy incision, positioning the drill holes across from one another beginning with the most inferior laminae and progressing superiorly. We then passed a length of

suture material through the hole in each laminar flap and tried the ends together, thus reconstructing the dorsal part of each vertebral arch.

## RESULTS

In almost all of our cases, the noted features of spina bifida were cutaneous masses or stigmata. Listed in descending order, the most common stigmata were lumbosacral subcutaneous lipoma, lumbar hypertrichosis and dermal sinus. Follow-up time ranged from 6 months to 5 years (mean, 29 months). Our assessments of the patients' orthopedic and neurological status at the time of presentation and throughout follow-up are presented in Table 1. Preoperatively, plain radiographs revealed a variety of bony anomalies, and patients had the characteristic mild abnormalities of bifid vertebrae and laminar defects. During follow-up, none of the patients developed problems with spinal instability or any spinal deformity such as scoliosis or kyphosis, and

Table 1: Features of the patients with spinal dysraphism at presentation and during follow-up.

Patient No	Lesion	Gender	Age at Diagnosis (months)	Number of Laminotomies Performed	Cutaneous findings	SBNS Score (preoperatively)	Follow-up time (months)	SBNS Score (postoperatively)
1	Lipomyelomeningocele	M	4	4	Subcutaneous lipoma, hyperpigm.	11	18	11*
2	Lipomyelomeningocele	F	3	3	Subcutaneous lipoma	11	38	15
3	Lipomyelomeningocele	M	7	3	Subcutaneous lipoma	11	40	15
4	Lipomyelomeningocele	F	5	4	Subcutaneous lipoma, hypertrich.	8	31	13
5	Lipomyelomeningocele	M	8	3	Subcutaneous lipoma	9	32	11*
6	Lipomyelomeningocele	M	22	3	Subcutaneous lipoma	11	10	11*
7	Dermal sinus tract	M	3	2	Dimple, hypertrich.	11	55	15
8	Dermal sinus tract	M	3	2	Dimple	11	40	15
9	Dermal sinus tract	F	4	2	Dimple	11	14	11*
10	Cervical meningocele	M	2	2	Cervical cystic mass	11	50	15
11	Cervical meningocele	F	3	2	Cervical cystic mass	11	40	15
12	Thoracic meningocele	F	3	2	Thoracic cystic mass	11	25	15
13	Thoracic meningocele	F	4	2	Thoracic cystic mass	11	6	11*
14	Type II split cord malf.	M	3	3	Lumbar meningocele	11	8	11*

F: Female, M: Male, \*: As an infant

x-rays indicated that the reconstructed bone was healthy in all cases.

Three of the six patients with lipomyelomeningocele had lumbosacral lesions that occupied more than one-third of the canal diameter, and two of these individuals had low-lying conus medullaris. As mentioned, two of the patients in the lipomyelomeningocele group had exhibited neurological deficits on presentation. One showed unilateral foot weakness and weak Achilles tendon reflex at 5 months of age, and the total SBNS score in this case was 8 (motor:5, reflex:2, bladder-bowel:1, as an infant). Postoperatively the patient's neurological status improved, and by 3 years of age the total SBNS score had risen to 13. The other patient with lipomyelomeningocele accompanied by neurological signs had no motor weakness and the patellar and Achilles tendon reflexes were intact bilaterally, but there was no anal reflex at 8 months of age. In this case, the total SBNS score on presentation was 9 (motor:6, reflex:2, bladder-bowel:1, as an infant). This patient's neurological status and ambulatory function were normal at the final follow-up exam, and the total SBNS score had reached 11 by 40 months of age. The results of the other 12 patients' neurological examinations on admission were normal, so all had maximum SBNS scores. Since all 14 patients were under 2 years of age when they were first seen, we did not assess voluntary control of bladder and bowel function in the initial assessments. Overall, the total SBNS scores on the first exam ranged from 8 to 11 (the maximum score for infants).

The spinal defects in the group included the six lipomyelomeningocele cases, two cases of simple cervical meningocele, two thoracic meningocele, three lumbosacral dermal sinus tract and one case of type II split cord malformation associated with lumbosacral meningocele and fatty tight filum terminale. There were no operative deaths. One patient developed a superficial wound infection that was successfully treated with intravenous antibiotics and local wound care.

## DISCUSSION

Compared to adults, children are more likely to develop spinal deformities after multisegmental laminectomy (10). A child's vertebrae are more delicate and still in the developing stages, and balanced mechanical stimulation is necessary to ensure normal growth. Laminectomy disrupts the

neuromuscular balance in that some of the supporting structures of the spine are removed (2,7). Kyphosis, anterior subluxation and spinal instability are some of the reported postoperative complications of multilevel laminectomies in children (6,10). Laminectomy has also been reported to further weaken the spinal column in patients with benign neoplastic or a congenital malformations and traumatic lesions. In addition, lumbosacral laminectomy for selective posterior rhizotomy in cerebral palsy has also been known to lead to spondylolysis and spondylolisthesis (6). Due to the potential for such problems, careful preoperative planning of the surgical approach is extremely important.

Yasuoka et al. (10) analyzed the cases of 58 patients who underwent multilevel laminectomy for conditions that normally do not cause spinal deformity on their own. They found that spinal deformity developed in 46% of these individuals, and all those affected were younger than 15 years of age. Peter and colleagues (6) performed five-level lumbosacral laminectomy to treat selective posterior rhizotomy in 163 children, and followed 99 of the cases. Incidental isthmic spondylolysis or grade I spondylolisthesis developed in 20% (19/99) of these individuals. In contrast, in the early 1990s, Abbott and coworkers (1) and Steinbok et al. (9) reported two large series on the treatment of spastic cerebral palsy in children in which all patients underwent multilevel laminotomy as opposed to laminectomy. These authors noted complete or partial bridging of the lamina roof in every case. Krauspe et al. (4) and Behnke and coauthors (2) also reported satisfactory results with multiple laminotomy in pediatric patients.

As early as 1976, Raimondi and colleagues (7) had emphasized the risk of kyphoscoliosis and instability as sequelae to laminectomy procedures for intraspinal lesions in children, and they were the first to suggest multilevel laminotomy as an alternative to laminectomy. In recent years, several attempts have also been made to develop a simple laminoplasty technique using titanium miniplates, a procedure that would offer another option for reconstructing the spinal canal (3).

## CONCLUSION

Our study is one of very few clinical investigations that have been done on multilevel laminotomy in patients with spinal dysraphism and

associated mild spinal deformities. Our experience, and that of others, confirms that multilevel laminotomy is the most appropriate operative technique for treating children with spinal lesions. We found that the procedure was well tolerated by patients, there were no postoperative complications, and radiological studies showed satisfactory bone union in all cases. Also, in 6 months to 5 years of follow-up, none of the children who underwent laminotomy developed problems with scoliosis or kyphosis.

#### Acknowledgement:

*The authors thank Assoc. Professor Ibrahim Yerebakan for his linguistic assistance.*

**Correspondence:** Assis. Prof. Dr. Çetin Refik Kayaoğlu  
Department of Neurosurgery  
Atatürk University Medical School  
Research Hospital  
25240, Erzurum  
Fax: 0 442 3171711  
Phone: 0 442 3166333  
E-mail: c.refik@superonline.com

#### REFERENCES

1. Abbott R, Feldstein N, Wisoff JH, Epstein FJ: Osteoplastic laminotomy in children. *Pediatr Neurosurg* 18;153-156,1992
2. Behnke J, Rama B, Markakis E: Laminotomy: a growth-conforming procedure in childhood. *Child's Nerv Syst* (abstr) 8;151,1992
3. Frank E, Keenen TL: A technique for cervical laminoplasty using mini plates. *Br J Neurosurg* 8;197-199,1994
4. Krauspe R, Sörensen N, Collmann H: Multilevel laminotomy in children. *Child's Nerv Syst* (abstr) 8;149,1992
5. Oi S, Matsumoto S: A proposed grading and scoring system for spina bifida: Spina Bifida Neurological Scale (SBNS). *Child's Nerv Syst* 8;337-342,1992
6. Peter JC, Hoffman EB, Arens LJ: Spondylolysis and spondylolisthesis after five-level lumbosacral laminectomy for selective posterior rhizotomy in cerebral palsy. *Child's Nerv Syst* 9;285-288,1993
7. Raimondi AJ, Gutierrez FA, De Rocco C: Laminotomy and total reconstruction of the posterior spinal arch for spinal canal surgery in childhood. *J Neurosurg* 45;555-560,1976
8. Rama B, Markakis E, Kolenda H, Jansen J: Reconstruction instead of resection: laminotomy and laminoplasty. *Neurochirurgia* 33;36-39,1990
9. Steinbok P, Reiner A, Beachamp RD, Cochrane DD, Keyes R: Selective functional posterior rhizotomy for treatment of spastic cerebral palsy in children. Review of 50 consecutive cases. *Pediatr Neurosurg* 18;34-42,1992
10. Yasuoka S, Peterson HA, MacCarty CS: Incidence of spinal column deformity after multilevel laminectomy in children and adults. *J Neurosurg* 57;441-445,1982