Turk Neurosurg, 2022

Original Investigation

DOI: 10.5137/1019-5149.JTN.37564-22.2

Received: 12.01.2022
Accepted: 24.05.2022

Published Online: 02.11.2022

Comparative Analysis of Clipping and Endovascular Therapy Outcomes in the Treatment of Ruptured Distal Anterior Cerebral Artery Aneurysms

Vikas Chandra JHA, Shahnawaz ALAM, Vivek Saran SINHA

Department of Neurosurgery , All India Institute of Medical Sciences, Patna, India

Corresponding author: Vikas Chandra JHA ✉ drvikaschandrajha@aiimspatna.org

ABSTRACT

AIM: To compare the outcomes of distal anterior cerebral artery (DACA) aneurysm treatment using endovascular therapy (EVT) and surgical clipping, and to assess their risk factors.

MATERIAL and METHODS: We retrospectively sampled and analyzed 31 patients treated for ruptured Distal anterior cerebral artery (DACA) aneurysms from a larger sample of 250 patients treated for ruptured aneurysms between July 2018 and July 2021. The outcomes of patients who underwent clipping and EVT were compared using chi-square tests. T-tests were used for univariate analysis and a logistic regression analysis was used to determine the risk factors affecting outcomes.

RESULTS: Of the 31 patients, 20 were treated with clipping and 11 with EVT. Patients treated with EVT had a mean age of 35.45 ± 6.66. The mean age of the clipping group was 44.4 ± 6.94 years (p=0.002). Intraoperative rupture was significantly more common in the clipping group (p=0.025). There were no significant differences in the postoperative incidence of vasospasm or hydrocephalus (p=0.12). Modified Rankin Scale scores (p=0.017) and Glasgow Outcome Scale scores (p=0.02) both at discharge and 6-month follow-ups were significantly better in the EVT group than in the clipping group. Length of stay in the Intensive Care Unit (ICU) was 9.27 ± 2.6 days following EVT and 23.60 ± 6.29 following clipping (p=0.001). Age (p=0.0136), Hunt and Hess grade (p=0.02), and the occurrence of intraprocedural rupture (p=0.009) were found to significantly affect outcomes.

CONCLUSION: The outcomes of EVT were better than those for clipping and required a shorter stay in the ICU and the hospital. This may be partially attributable to the dual-trained neurovascular surgeon who performed the procedures. Older age, poorer Hunt and Hess grades, and intraoperative aneurysm rupture adversely affected outcomes.

KEYWORDS: Distal anterior cerebral artery aneurysm, Clipping vs. coiling, Dual-trained neurovascular surgeon, Outcome analysis

ABBREVIATIONS: ACA: Anterior cerebral artery, **ACom:** Anterior communicating artery, **CT:** Computed tomography, **DACA:** Distal anterior cerebral artery, **DSA:** Digital subtraction angiography, **EVD:** External ventricular drain, **EVT:** Endovascular therapy, **GOS:** Glasgow Outcome Scale, **ICA:** Internal carotid artery, **ICU:** Intensive care unit, **IEC:** Institutional ethics committee, **mRS:** Modified Rankin Scale, **NCCT:** Non-contrast computed tomography, **SAH:** Subarachnoid hemorrhage, **VP:** Ventriculoperitoneal

INTRODUCTION

Distal anterior cerebral artery (DACA) aneurysms constitute 1%–9% of all cerebral aneurysms (13,15). This type has been reported to be more fragile than other aneurysms (2,16). When they are approached microsurgically, one faces the fundus first and proximal access is often difficult, leading to intraoperative rupture and vasospasm and increasing the chances of postoperative brain edema, infarct, and hydrocephalus. Because of the distal location, these aneurysms can be difficult to access through

Vikas JHA : 0000-0002-0080-061X Shahnawaz ALAM : 0000-0002-0656-3571 Vivek Saran SINHA : 0000-0003-1451-948X

a microcatheter and the need for coiling by balloon or stent in wide-necked cases creates challenges in endovascular therapy (EVT). Previous studies have reported better outcomes with microsurgical clipping than EVT (13,16). However, these lesions have become more accessible with the development of better angio hardware and newer techniques, which can provide good distal access up to the supraclinoid segment of the internal carotid artery. This, in turn, allows microcatheter stability for coiling (2). Few comparative studies have reported better results with EVT and there have been few comparative analyses of outcomes when these lesions are managed by dual-trained neurovascular surgeons (2). In the present study, we compared the outcomes of microsurgical clipping and EVT for the treatment of DACA aneurysms. We also endeavored to identify factors affecting the outcomes in such patients.

MATERIAL and METHODS

This study was approved by the local institutional ethical committee (IEC No. 543/21). We retrospectively analyzed patients treated for DACA aneurysms between July 2018 and July 2021. From a pool of 250 patients who had undergone treatment for ruptured aneurysms at our center, we identified 31 with DACA aneurysms. This number is higher than one would expect because our institute is the only center in this region with the facilities to treat patients with microsurgical clipping and EVT. All such procedures in our department were performed by surgeons trained in microsurgical clipping and endovascular interventions.

We included all patients with DACA aneurysms treated by either clipping or coiling. We excluded patients having features of dissecting aneurysms, and those with infectious and traumatic etiologies that may have interfered with outcomes.

Patients' demographic details such as age and sex; and clinical data, including Hunt and Hess grades, pre and postoperative modified Rankin Scale (mRS) scores, the time between the onset of symptoms and treatment, comorbid conditions, treatment type (microsurgical clipping or coiling), and the occurrence of perioperative events such as intraoperative rupture, vasospasm, brain edema, postoperative infarct, and hydrocephalus were obtained from the medical records of our institution.

The risks and benefits of both procedures were explained to the patients, or their relatives, where applicable, and they chose their preferred option. After obtaining their consent the treatment was planned. We also obtained the permission of patients or their relatives to use their data for teaching and clinical research.

Patients having a fundus to neck ratio greater than 1.5 and those with comorbidities were advised to undergo EVT. Those having hematoma with mass effect and branches arising from the fundus, and those with a fundus to neck ratio less than 1.5 were advised to undergo clipping.

All patients were initially evaluated with computed tomography (CT) angiography and 3D image reconstructions followed by digital subtraction angiography (DSA) to evaluate the blood flow, collateralization, and configuration of aneurysms. Postoperative CT angiography and DSA were also conducted with each patient and follow-up DSAs were performed at 6-month and 1-year follow-ups.

Raymond-Roy classification of aneurysm occlusion was used to assess the angiography aneurysm obliteration results for both clipping and EVT. Complete obliteration with no visualization of the sac and neck of the aneurysm was classed as type 1; the presence of a small residual neck was classed as type 2; visible dye in the sac of the aneurysm was classed as type 3.

Clinical outcomes were assessed by postoperative mRS scores and Glasgow Outcome Scale (GOS) scores. Outcomes were classes as good if the mRS score was either 1 or 2 and bad if it was 3. Similarly, outcomes were classed as good if the GOS score was 4 or 5 and bad if it was less than 4.

Statistical analyses of baseline characteristics were performed using chi-square tests, Fisher's exact tests, and standard t-tests. All factors affecting outcome were analyzed by univariate analysis, followed by logistic regression analysis. A p-value<0.05 was considered statistically significant. Statistical analysis was performed using SPSS software for Windows, version 22 (IBM Corp., Armonk, NY, USA).

RESULTS

Angiographic findings: In this study, 20 DACA aneurysms were clipped. Of these, 15 were located on the A2–A3 junction, three were distal to the A2–A3 junction in a callosomarginal location, and two were proximal to the A2–A3 junction near the origin of the frontopolar artery. Eleven aneurysms were coiled, of which, eight were at the A2–A3 junction, two were distal to the A2–A3 junction, and one was proximal to the A2–A3 junction. Twelve of the clipped aneurysms were filling from the left A1 as the right A1 was in spasm and aneurysms were not visualized upon right internal carotid artery (ICA) injection. Four of the 11 coiled aneurysms were filling from the left A1, with severe spasms in the right A1. There were two azygos anterior cerebral arteries (ACAs) in the clipping group and one in the EVT group. Three patients in the clipping group and two in the EVT group had multiple anterior and posterior aneurysms. Eight of the clipped aneurysms and five of the coiled aneurysms were wide-necked with an A3 branch arising from the dome. Three of the clipped aneurysms were smaller than 5 mm, 11 were 5–10 mm, and six were larger than 1 cm. Eight of the coiled aneurysms were 5–10 mm and three were larger than 1 cm. Follow-up DSA identified 15 of the 20 clipped aneurysms as Raymond-Roy occlusion type 1, four as type 2, and one as type 3 (Figure 1). Seven of the coiled aneurysms were type 1 (Figure 2), and three were type 2. One of the coiled DACA aneurysms was type 3 but a repeat DSA after 7 days found it had recoiled, achieving a type 2 classification (Figure 3). Classifications observed on follow-up DSA are shown in Table I and Figure 4.

Surgical Approaches

All endovascular procedures were performed through a right

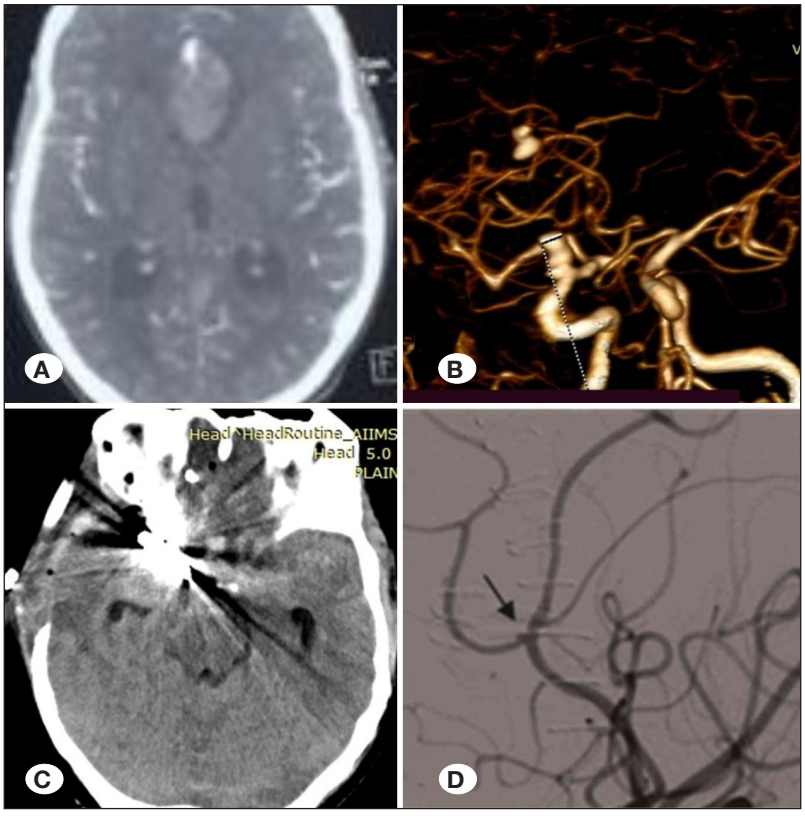

Figure 1: A) Preoperative CT angiography revealing bleed in the interhemispheric fissure.
B) CT angiography with 3d reconstruction revealing one distal anterior cerebral artery aneurysm at the A2-A3 junction and another at the Right internal carotid artery bifurcation. **C)** Postop CT angiography revealing clipped aneurysm with no infarct or brain edema. **D)** Postop DSA suggests complete obliteration of the aneurysm.

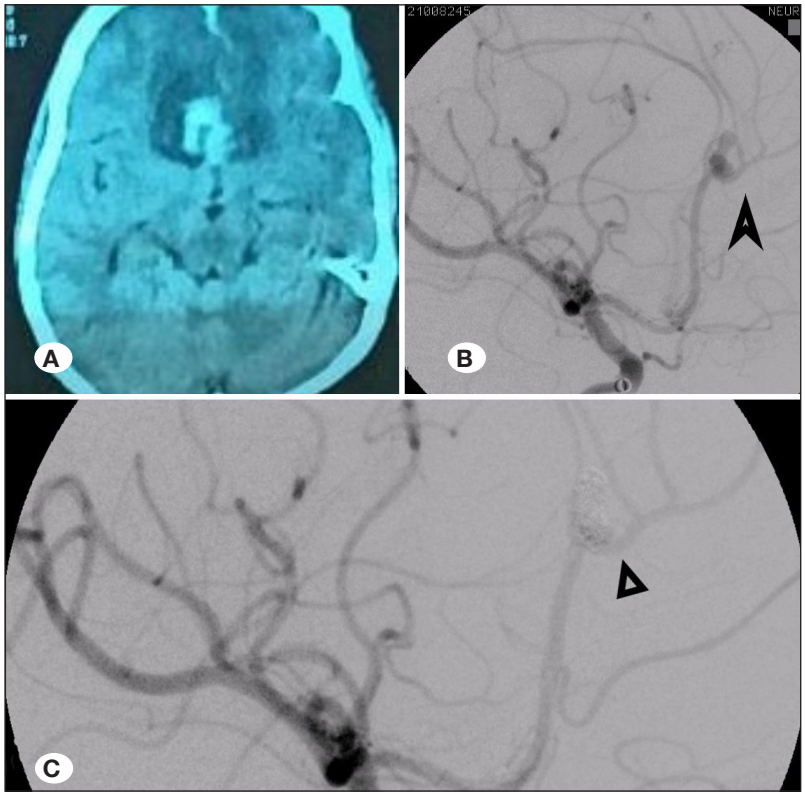

Figure 2: A) NCCT head suggests bleed in interhemispheric fissure by ruptured DACA aneurysm. **B)** Preoperative DSA revealed a wide-based aneurysm at the A2-A3 junction. (marked by arrowhead). **C)** Postoperative DSA suggests complete obliteration of the aneurysm. (marked by arrowhead).

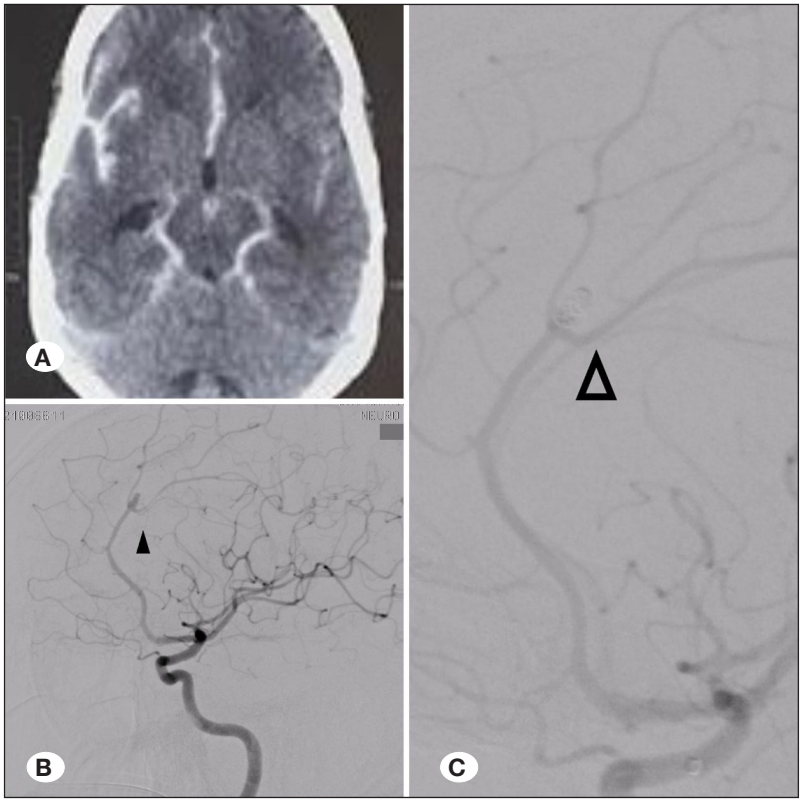

Figure 3: A) NCCT head suggests diffuse SAH in the interhemispheric fissure, Sylvian fissures, and perimesencephalic cisterns. **B)** Preoperative DSA suggests a narrow neck of DACA aneurysm at the A2-A3 junction(marked by arrowhead). **C)** Postop DSA suggests complete obliteration of the neck of the aneurysm (marked by arrowhead).

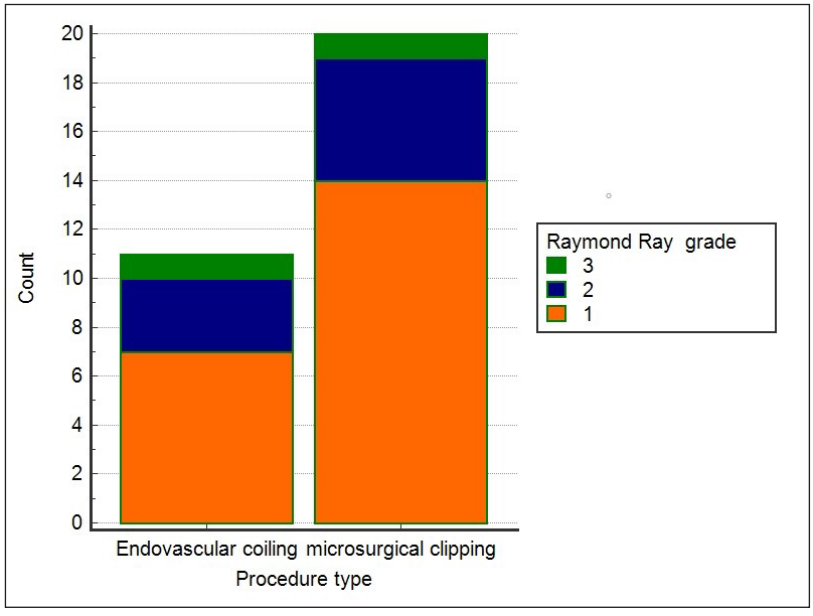

Figure 4: Stacked column shows the post-procedural Raymond-Roy classification of angiographic results.

femoral artery puncture. In 17 of the clipped aneurysms, an interhemispheric surgical approach was adopted. A pterional approach was used with three as these patients had an anterior communicating artery (Acom) aneurysm, ICA bifurcation, and an ophthalmic segment aneurysm in addition to their DACA aneurysms (Figure 1).

Intraoperative and Postoperative Complications

Intraoperative aneurysm rupture occurred in one EVT and 10 clipping cases (p=0.025). Aneurysms that were inferiorly and laterally directed with associated intraparenchymal hematoma and brain edema ruptured during dissection of the interhemispheric fissure. Vascular manipulation to achieve proximal control led to infarctions in the region of the ACA in

Table I: Demography and Clinical Profile of Patients Who Underwent Microsurgical Clipping and Endovascular Therapy

		Clipping	Coiling	p
No.of cases		20	11	
Sex	Male	8	4	
	Female	12	7	
Age(yrs)-(mean)		44.4 ± 6.94	35.45±6.66	**0.002**
Duration to treat after onset		8.25 ± 4.57	7.63±3.85	**0.042**
Intracerebral haemorrhage		6	2	
Intraventricular haemorrhage		4	2	
SAH		15	9	
Hunt &Hess Grade				0.685
1		8	2	
2		3	5	
3		6	2	
4		3	2	
5			-	
Fischer grade				0.806
1		2		
2		3	5	
3		12	4	
4		3	2	
mRS Score				0.290
1		1		
2		6	3	
3		10	8	
4		2	-	
Location				0.496
Infracallosal		2	2	
Genu		13	7	
Supracallosal		5	2	
Aneurysm size				0.583
<5 mm		3	-	
5-10 mm		11	9	
>10 mm		6	2	
Fundus: neck				
<1.5				
>1.5				
Branch arising from fundus		2	-	
Morphology				
Saccular		20	11	
Fusiform		-	-	
Dissecting		-	-	
Multiple		3	2	
Azygous		1	1	

six of the 20 clipping patients, while hardware manipulation led to vasospasm and subsequent infarction in one of the 11 patients who underwent EVT (p=0.19). Six patients in the clipping group and two in the EVT group developed hydrocephalus, for which an external ventricular drain (EVD) was inserted. Subsequently, five patients in the clipping group and one in the EVT group required permanent shunts (p=0.12). Coil compaction in the aneurysm neck and partial obliteration of the lumen occurred in two of the 11 patients who underwent EVT. These patients were treated with an antiplatelet agent as they refused further surgical intervention (Table II).

Postoperative Outcomes

The mRS scores in the immediate postoperative period were 1.45 ± 0.68 in the EVT group and 2.3 ± 0.97 in the clipping group, suggesting significantly better postoperative recovery in the EVT group (p=0.017) (Table III and Figure 5). The mRS scores at 6-month follow-ups were 1.13 ± 0.4 in the EVT group and 2.3 ± 0.68 in the clipping group, with a p-value of 0.017, suggesting good ongoing improvement in the EVT group (Table IV). Five patients in the clipping group and one in the EVT group required a ventriculoperitoneal (VP) shunt as they did not respond to EVD for hydrocephalus and raised

Table II: Perioperative Events

	Clipping	Coiling	p
Intraoperative complications			
Intraprocedural rupture/Bleeding	10	1	**0.025**
Spasm	3	3	-
Coil compaction	-	1	-
Coil migration	-	1	-
Postoperative complications			
Rebleeding	1	-	-
Spasm	5	4	0.221
Infarction	7	2	0.229
Hydrocephalus	6	1	0.126

Table III: Treatment Results at Discharge

	Clipping	Coiling	p
mRS score			
1	4	8	**0.017**
2	8	2	
3	6	1	
4	-	-	
Glasgow outcome score			
5	4	6	**0.021**
4	6	2	
3	6	2	
2	2	1	
1	-	-	
Length of stay in ICU	23.60 ± 6.29	9.27 ± 2.6	**0.001**
Length of stay in hospital	33.6 ± 7.9	18.72 ± 2.19	**0.001**
Mortality	2	-	

ICU: *Intensive Care Unit,* ***mRS:*** *Modified Rankin Scale.*

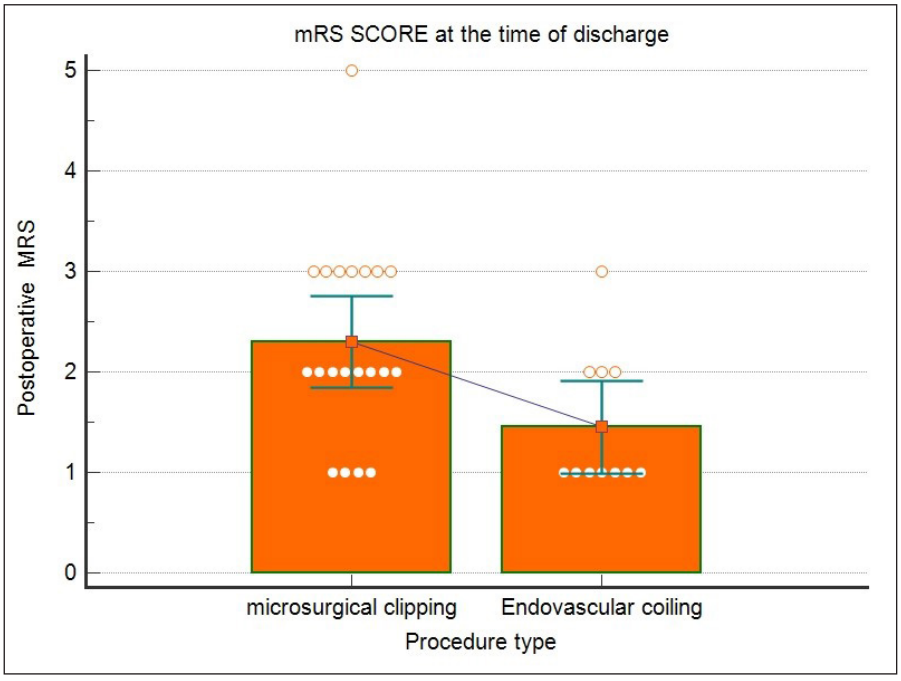

Figure 5: Barchart with box &whisker pattern suggests MRS score is better in coiling group than clipping group at discharge, MRS at 6 months followed the similar trend as at the time of discharge.

Table IV: Treatment Results After 6 Months

	Clipping	Coiling	p
MRS score			
1	4	8	**0.0107**
2	8	2	
3	8	1	
4	-	-	
Glasgow Outcome Score			
5	4	6	**0.0267**
4	8	4	
3	4	-	
2	2	1	
1	-	-	
Mortality	2	-	

mRS: *Modified Rankin Scale.*

intracranial pressure following aneurysm rupture (p=0.12). Although 25% of patients in the clipping group, compared to 10% in the EVT group, required a VP shunt, the difference was not found to be significant (p=0.12). The length of stay in the intensive care unit (ICU) was 23.6 ± 6.29 days after clipping and 9.27 ± 2.16 days after EVT (p=0.001), suggesting earlier recovery following EVT (Fig. 6). Similarly, the average length of hospital stay was longer in the clipping group. A logistic regression analysis of the factors predicting poor outcomes found that age (p=0.0136), Hunt and Hess grades p=0.02), and intraprocedural rupture (p=0.009) significantly affected outcomes in both groups. The type of procedure performed to treat the patient with DACA aneurysm was not found to significantly affect outcomes (Table V).

DISCUSSION

DACA aneurysms are difficult to treat and previous research has reported variable outcomes in treating these aneurysms with EVT (13). Although their reported incidence is 1%–9% of all aneurysms, the incidence in the present study was 12% because our center is the major referral hospital in the region (2,15).

DACA aneurysms occur in the narrow interhemispheric passage between the falx cerebri and the medial frontal lobe. In the majority of the patients, they present initially with bleeding in the interhemispheric fissure, which is followed by bleeding in intraparenchymal and intraventricular locations. Intracranial bleeding occurs in 80%–90% of patients with DACA aneurysms (2,3,10,15,16). In 10%–46% of cases, they co-occur with other aneurysms (2,3,9,10,15,16).

The most prevalent locations of DACA aneurysms are the A3 segment (69%–89%), the A2 segment below the genu of the corpus callosum (around 9%), and the A4–A5 segment (5%–20%,). In our study, the incidences of DACA aneurysms in these locations were 74%, 10%, and 16%, respectively (2,6).

The mean size of DACA aneurysms has been previously reported as 5–8 mm, with around 50% smaller than 8 mm (17,18). The incidence of aneurysms with wide necks and a fundus to neck ratio less than 1.5 has been reported as around 30%–40%, with a branch arising from fundus in 10% (17,18). This configuration presents a major surgical challenge for both clipping and EVT procedures.

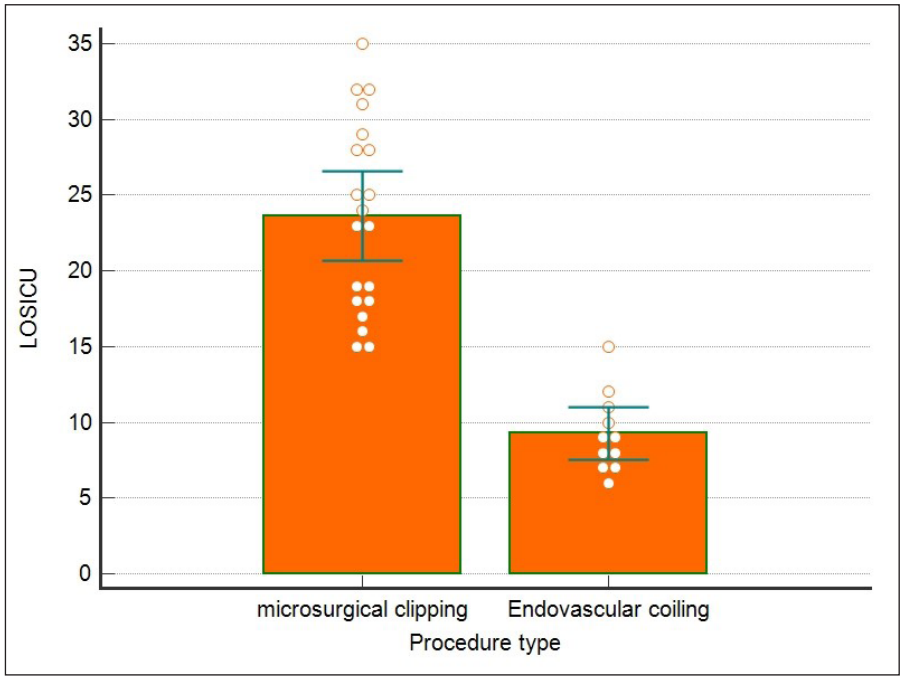

Figure 6: Barchart with box &whisker pattern suggests shorter ICU stay inpatient who underwent coiling as compared to clipping.

Table V: Logistic Regression Analysis of Factors Affecting Outcome Following the Procedure for Treatment of DACA Aneurysms

Variable	Coefficient	P
Age	190161759.43744	**0.0136**
Hunt and Hess grades	122497340.95764	**0.0245**
Intraprocedural rupture	149681721.95662	**0.0410**
Constant	73102604.56119	**0.0098**

The presence of vascular anomalies like azygos DACA, triplication of the A2 segment, bihemispheric DACA, and associated arteriovenous malformations can influence surgical outcomes. Different studies have reported the presence of an azygos artery in 3%–22% of patients with DACA aneurysms (2,6). In the present study the incidence was 6.5%. However, none of the other associated anomalies were observed in our study.

With advances in medical technology and the use of guiding catheters, surgeons can now achieve good distal access to the supraclinoid ICA, which provides sufficient stability to microcatheters for coiling DACA aneurysms. As a result, current outcomes using EVT to treat these lesions are much improved. Previously, EVT was only considered for such aneurysms with poor Hunt and Hess grades but the treatment is now possible with all DACA aneurysm patients. In our patient population, we were unable to perform EVT in four patients because of difficult proximal access and these patients underwent microsurgical clipping. Of these four, two had anomalous loops in the proximal ICA and two had type 3 aortic arches that could not support the distal access catheter and microcatheter. Previous studies have reported complete occlusion of DACA aneurysms in 78%–97% of patients who underwent EVT (4,17,18). In the present study, we achieved Raymond-Roy type 1 occlusion in 74% and type 2 occlusion in 26% of the patients who underwent EVT. All of the patients in whom complete occlusion was not achieved had an arterial branch arising from the fundus and what appeared to be a small residual neck. However, no further enlargement of the residual neck was observed on the 6-month follow-up DSAs (14).

In the clipping group, total obliteration of the aneurysm was achieved in 80% and near-total obliteration in 20% of the patients in our study. Lehecka et al. conducted a large study of 501 microsurgically clipped DACA aneurysms. They reported complete obliteration in 91% and near-total occlusion in 5% (6). Shukla et al. reported complete occlusion in 93% of patients with DACA aneurysms treated by microsurgery (16). Carvi et al. reported better microsurgery results in patients with infra-callosal and peri-callosal distal branches, with an occlusion rate > 90% (1). None of these studies indicate the number of patients with a residual aneurysm neck on follow-up DSAs.

DACA aneurysms are very fragile with a higher incidence of intraoperative rupture compared to aneurysms in other locations. Intraoperative rupture during microsurgical clipping has been reported in 10%–26% of patients (1,2,6,7,14). In the present study, the incidence was 50% in patients who underwent clipping and 10% in those treated with EVT, which is slightly higher than the rates reported in other studies (4,7,8,14,17,18). One reason for this may have been a greater number of patients with intraparenchymal hematoma with surrounding edema, which makes dissection in an already

narrow corridor more difficult. Another contributing factor may have been a higher incidence of inferiorly and laterally directed aneurysms, which make visualization of the neck more challenging and requires more dissection to achieve proximal control. A third reason may have been poorer Hunt and Hess grades and higher Fisher grades in our patients who underwent clipping. These are known to be associated with a higher incidence of intraoperative rupture (5,11,12).

Infarction in the immediate postoperative period after surgical clipping has been reported in 9%–22% of patients (1,2,4,10,13,17). Intraoperative rupture requires vascular manipulation in the immediate vicinity and this increases the risk of postoperative vasospasm and infarction in the ACA region. This was treated in our patients with arterial spasmolysis by injection of nimodipine and placement of a microcatheter in the distal ACA. In the majority of cases, this relieved vasospasm and reduced infarction. In patients who developed hydrocephalus following the procedure, we inserted EVD. These were later changed to VP shunts as the patients did not respond to EVD weaning. These timely interventions helped to improve our results, demonstrating the importance of dual training in both microsurgery and EVT.

Previous research has found better functional recovery in DACA aneurysm patients treated with EVT than those treated with clipping, evidenced by a higher proportion of patients achieving a postoperative mRS score < 3 (2,5,11,12). This was also observed in the present study. Mortality rates of 9%–12% have been reported in previous research, which is slightly higher than that seen in the present study. Other studies have found no significant difference between the outcomes of DACA aneurysm treatment with these two procedures (19,20). In the present study, we observed shorter durations of ICU and hospital stays in EVT patients than in clipping patients. In a neurosurgical setup like ours, patients cannot always afford the treatment required. This is a serious concern and should be addressed through the evaluation of the most cost-effective means of delivering optimum treatment. We found intraoperative rupture to be the greatest contributor to postoperative complications. These included operative site edema, vasospasms, infarction, and hydrocephalus. Timely intervention to treat these complications may have reduced the length of stay in ICU and hospital but this would have been true for both procedures so should not have significantly affected the comparison of surgical approaches.

Limitations

Patients in our clipping group were found to have higher Hunt and Hess grades and higher Fisher grades than patients treated with EVT on non-contrast computed tomography (NCCT) of the head. Higher grades on both these scales indicate subarachnoid hemorrhage of greater severity. Therefore, the clipping group in this study was more susceptible to intraoperative complications such as aneurysm rupture, intraoperative bleeding, vasospasm, and infarction. It would also have contributed to poorer outcomes in the clipping group than in the EVT group. Patients were not randomly assigned to the two groups but selected their preferred procedure after the two options were explained to them, including the risks and probable outcomes of each. There were fewer patients in the EVT group and the small sample size in this group is likely to have weakened the validity and reliability of our findings. It is possible that there would have been more significant differences between the groups if this had been a randomized prospective study with a larger sample.

CONCLUSION

DACA aneurysms are more vulnerable to rupture than other aneurysms in the circle of Willis and this leads to a high incidence of intraoperative rupture. Postoperative recovery in our EVT group was found to be better than that of our clipping group, both during the immediate postoperative period and on subsequent follow-up. The length of ICU and hospital stay was significantly shorter in patients treated with EVT than those treated with clipping. The dual training of our surgical staff in both of these procedures may have helped to improve our outcomes in both treatment modalities. However, overall, outcomes were found to be better in patients treated with EVT.

AUTHORSHIP CONTRIBUTION

Study conception and design: VCJ

Data collection: VCJ, SA, VSS

Analysis and interpretation of results: VCJ, SA, VSS

Draft manuscript preparation: VCJ, SA, VSS

All authors (VCJ, SA, VSS) reviewed the results and approved the final version of the manuscript.

REFERENCES

1. Carvi y Nievas MN: The influence of configuration and location of ruptured distal cerebral anterior artery aneurysms on their treatment modality and results: Analysis of our casuistry and literature review. Neurol Res 32(1):73-81, 2010
2. Furtado SV, Jayakumar D, Perikal PJ, Mohan D: Contemporary management of distal anterior cerebral artery aneurysms: A dual-trained neurosurgeon's perspective. J Neurosci Rural Pract 12(4):711-717, 2021
3. Hernesniemi J, Tapaninaho A, Vapalahti M, Niskanen M, Kari A, Luukkonen M: Saccular aneurysms of the distal anterior cerebral artery and its branches. Neurosurgery 31:998-999, 1992
4. Huang Q, Shen J, Xu Y, Liu J: Endovascular treatment of ruptured distal anterior cerebral artery aneurysm. Neurol India 58(02):259-263, 2010
5. Hui FK, Schuette AJ, Moskowitz SI, Spiotta AM, Lieber ML, Rasmussen PA, Dion JE, Barrow DL, CawleyCM: 38 Microsurgical and endovascular management of pericallosal aneurysms. J Neurointerv Surg 3:319-323, 2011
6. Lehecka M, Lehto H, Niemela M, Juvela S, Dashti R, Koivisto T, Ronkainen A, Rinne J, Jääskeläinen JE, Hernesniemi JA: Distal anterior cerebral artery aneurysms: Treatment and outcome analysis of 501 patients. Neurosurgery 62:590-601, 2008

7. Miyazawa N, Nukui H, Yagi S, Yamagata Z, Horikoshi T, Yagishita T, Sugita M: Analysis of factors affecting the outcome of patients with ruptured distal anterior cerebral 24 artery aneurysms. Acta Neurochir 142:1241-1246, 2000
8. Nguyen TN, Raymond J, Roy D, Chagnon M, Weill A, Iancu-Gontard D, Guilbert F: Endovascular treatment of pericallosal aneurysms. J Neurosurg 107:973-976, 2007
9. Ohno K, Monma S, Suzuki R, Masaoka H, Matsushima Y, Hirakawa K: Saccular aneurysms of the distal anterior cerebral artery. Neurosurgery 27:903-907, 1990
10. Orz Y: Surgical strategies and outcomes for distal anterior cerebral arteries aneurysms. Asian J Neurosurg 6(01):13-17, 2011
11. Park KY, Kim BM, Lim YC, Chung J, Kim DJ, Joo JY, Huh SK, Kim DI, Lee KC, Lee JW: The role of endovascular treatment for ruptured distal anterior cerebral artery aneurysms: Comparison with microsurgical clipping. J Neuroimaging 25(1):81-86, 2015
12. Peschillo S, Cannizzaro D, Caporlingua A, Missori P: A systematic review and meta-analysis of treatment and outcome of blisterlike aneurysms. AJNR Am J Neuroradiol 37(05):856-861, 2016
13. Petr O, Coufalová L, Bradáč O, Rehwald R, Glodny B, Beneš V: Safety and efficacy of surgical and endovascular treatment for distal anterior cerebral artery aneurysms: A systematic review and meta-analysis. World Neurosurg 100:557-566, 2017
14. Roy D, Milot G, Raymond J: Endovascular treatment of unruptured aneurysms. Stroke 32(9):1998-2004, 2001
15. Sekerci Z, Sanlı M, Ergün R, Oral N: Aneurysms of the distal anterior cerebral artery: A clinical series. Neurol Neurochir Pol 45(2):115-120, 2011
16. Shukla D, Bhat DI, Srinivas D, Somanna S, Pandey P, Chandramouli BA, Sastry KV, Das BS: Microsurgical treatment of distal anterior cerebral artery aneurysms: A 25 year institutional experience. Neurol India 64(6):1204-1209, 2016
17. Sturiale CL, Brinjikji W, Murad MH, Cloft HJ, Kallmes DF, Lanzino G: Endovascular treatment of distal anterior cerebral artery aneurysms: Single-center experience and a systematic review. AJNR Am J Neuroradiol 34(12):2317-2320, 2013
18. Suzuki K, Yatomi K, Yamamoto M, Oishi H, Arai H: Endovascular therapy of distal anterior cerebral artery aneurysms: Single-institution clinical experience with 47 patients (49 aneurysms). J Neuroendovascular Therapy 13:329-335, 2019
19. Zanaty M, Chalouhi N, Starke RM, Daou B, Todd M, Bayman E, Torner J, Hasan D: Short-term outcome of clipping versus coiling of ruptured intracranial aneurysms treated by dual-trained cerebrovascular surgeon: Single-institution experience. World Neurosurg 95:262-269, 2016
20. Zhai XD, Li CJ, Yu JX, He C, Ye M, Hu P, Geng JW, Xiang SS, Ma YJ, Zhang HQ: Microsurgical and endovascular treatment outcomes in pericallosal artery aneurysms: A single center retrospective analysis. Turk Neurosurg 30(2):285-292, 2020