

Tenosynovial Giant Cell Tumor in the Cervico-Thoracic Junction

Servikotorasik Bileşkedeki Tenosinovyal Dev Hücreli Tümör

Ozerk OKUTAN¹, Ihsan SOLAROGLU², Ozlem OZEN³, Baris SAYGILI⁴, Ethem BESKONAKLI⁴

¹Medicana Konya Hospital, Department of Neurosurgery, Konya, Turkey

²Koc University, Faculty of Medicine, Department of Neurosurgery, Istanbul, Turkey

³Baskent University, Faculty of Medicine, Department of Pathology, Ankara, Turkey

⁴Ankara Atatürk Education and Research Hospital, Department of Neurosurgery, Ankara, Turkey

Presented in: 21. Annual Meeting of Turkish Neurosurgery Society, 20-24 April 2007, Antalya, Turkey

Correspondence address: Ozerk OKUTAN / E-mail: ozerkokutan@hotmail.com

ABSTRACT

Tenosynovial giant cell tumor (TGT) rarely arises from the posterior coloumn of the cervical spine. Most lesions of TGT involve the tendon sheath and joint lining of the small joints of the fingers and hands, and consecutively the knee, ankles and feet, and hips. Rate of extra-articular presentation is about 5-15% in all cases. In this report, a case with paraparesis caused by TGT in the cervico-thoracic junction is presented. The clinical manifestations, diagnosis, and treatment of this unusual condition are discussed. In the treatment of TGT of the vertebral column, the main aim should be total surgical excision of the tumor.

KEYWORDS: Tenosynovial giant cell tumor, Spine, Vertebra, Diagnosis, Treatment

ÖZ

Tenosinovyal dev hücreli tümör (TDHT) nadiren servikal omurganın arka elemanlarından nadiren köken alır. TDHT en çok el ve parmakların küçük eklemlerinin tendon kılıfı ile eklem kapsülünde ve sırasıyla diz, ayak bileği, ayak ve kalça eklemlerinde görülür. Tüm vakaların yaklaşık % 5-15'i eklem dışı yerleşimlidir. Bu raporda, parapareziye neden olan servikotorasik bileşkedeki tenosinovyal dev hücreli tümör olgusu sunulmuştur. Hastanın klinik, radyolojik ve tedavi şekli tartışılmıştır. Servikal omurgadaki tenosinovyal dev hücreli tümör tedavisinde, ana amaç tümörün total eksizyonu olmalıdır.

ANAHTAR SÖZCÜKLER: Tenosinovyal dev hücreli tümör, Omurga, Vertebra, Tanı, Tedavi

INTRODUCTION

Tenosynovial giant cell tumor is slowly progressive lesion that arises from the bursa, synovial lining of joint spaces and synovial membrane of the tendon sheath (2, 3, 9). About 90% of lesions of TGT involve the small joints of the fingers and hands, and most of the remaining 10% occur at the elbow and knees (1, 9). In rare cases, TGT appears to arise from the synovial membranes of the joints accessory to the vertebral column (2, 3, 5).

In this report, a case with paraparesis caused by TGT in the cervico-thoracic junction is presented.

CASE REPORT

A 65-year-old man presented with a 2-year history of neck pain and progressive weakness of both lower extremities. Neurological examination revealed paraparesis with hyper-reflexia on the lower extremities and an inconsistent sensory loss below the Th5 level. Laboratory investigations revealed normal hematological and biochemical parameters. Serum tumor markers were normal. Plain X-ray of cervical spine showed a destructive lesion that affected the lamina and

spinous process of C7 vertebra (Figure 1). Contrast-enhanced T1-weighted magnetic resonance (MR) image showed a lobulated mass extending superiorly and inferiorly between C6-Th2 vertebral levels (Figure 2).

The lesion was totally resected from the paraspinal muscles and eroded lamina of C7 vertebra in the sitting position under general anesthesia. The eroded lamina and attached ligamentum flavum were also removed during the operation. The patient was discharged with remarkable improvement of his neurological condition on postoperative day 3.

Histological examination revealed a thin collagenous capsule that penetrates the tumor and giving appearance of a vague lobular pattern. The tumor was cellular and composed of sheets of round or polygonal mononuclear cells. Cleft like spaces and focal collections of xanthoma cells were also present. Paucity of multinucleated giant cells and mitotic figure was noted (Figure 3A). Immunohistochemical analysis of the tumor cells demonstrated diffuse expression of vimentin and focal areas of CD68 (Figure 3B). The histopathological and immunohistochemical findings were compatible with a diagnosis of TGT.

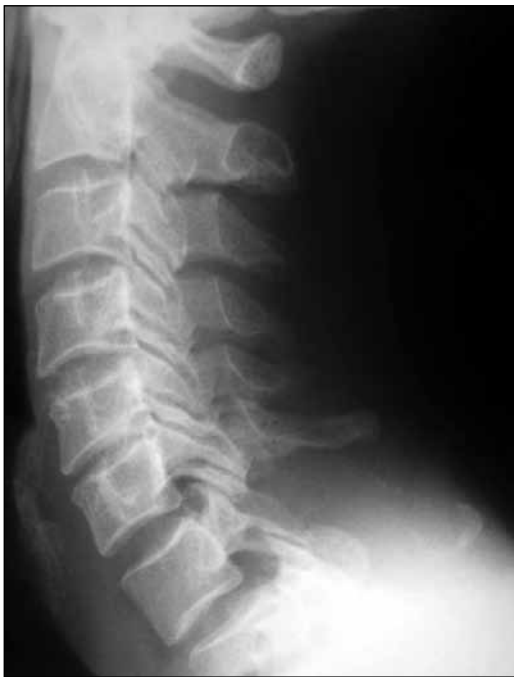

Figure 1: Plain X-rays of cervical spine showed a destructive lesion that affected the lamina and spinous process of C7 vertebra.

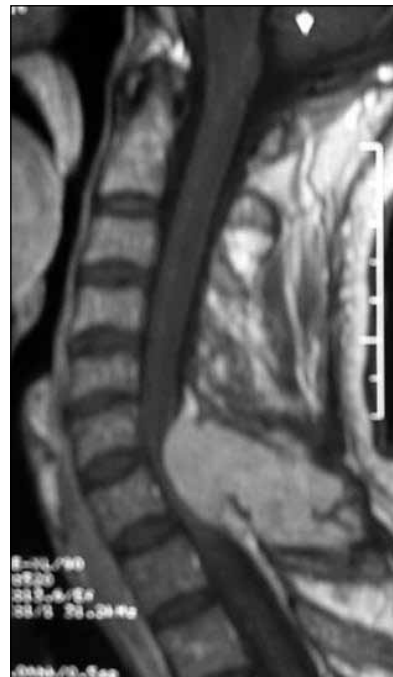

Figure 2: T1-weighted image of contrast-enhanced magnetic resonance imaging (MRI) showed lobulated mass that extended superiorly and inferiorly between C6-Th2 vertebral levels.

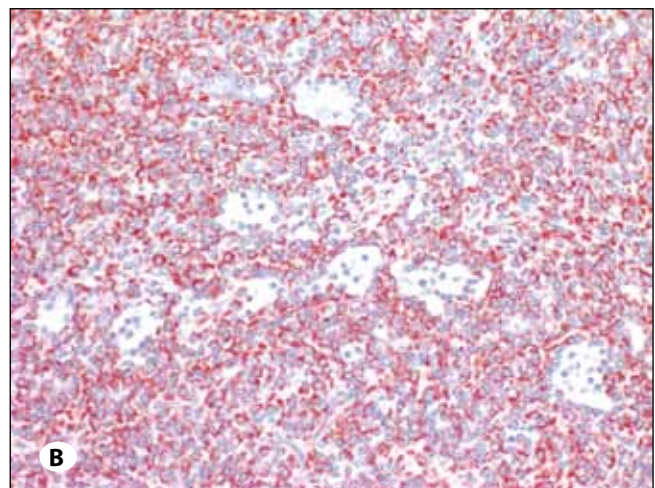
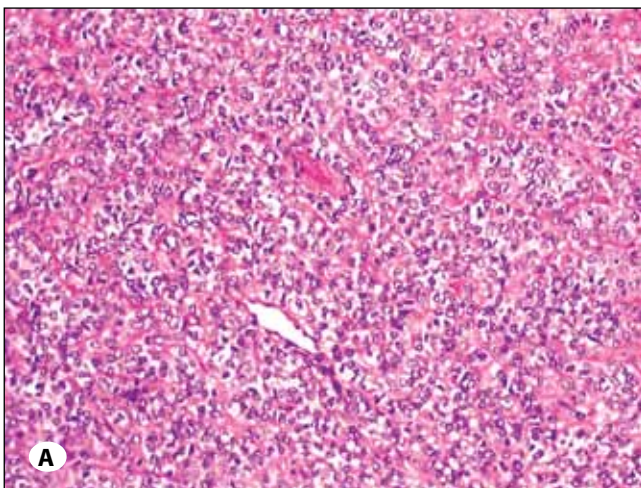


Figure 3: A) Photomicrograph of the specimen showed high power view of tumor cells with a paucity of giant cells (H&E x 20). **B)** Tumor cells showed diffuse vimentin staining (immunoperoxidase x 20).

At 6 months follow-up, control MRI revealed no evidence of tumor recurrence (Figure 4).

DISCUSSION

The rate of extra-articular presentation of TGT is 5-15% (5, 8). TGT rarely arises in the region of the axial skeleton, and up to 5.6% of cases have been noted to occur in the mobile spine (2, 5, 7). Furlong et al. reported that 52% involved the cervical spine, 29% involved the lumbar spine, and 7% involved the thoracic spine (2). As in our case, TGT typically involved the posterior aspects of the vertebrae, especially in the region of the facet joints (2). Destruction and scalloping of the bone and epidural extension were present in at least 70% of the cases (1, 2, 9). The majority of patients present with a pain localized

to the spinal region, paresthesia, and muscle weakness. Myers and Masi reported that on average the interval between the onset of symptoms and the diagnosis ranges from 10 to 19 months (6). The symptoms of our patient had been present for 24 months before surgery which suggests these tumors grow in a slow pattern.

The best treatment for TGT is surgical removal (3, 5, 9). We suggest that the aim of surgical removal must be gross total excision at the first operation. Subtotal excision may provide adequate tumor control. Most authorities agree that early recurrence was seen when gross total excision was not possible (2-4, 9). In addition, TGT of the spinal region has a propensity for local recurrence. Giannini et al reported that

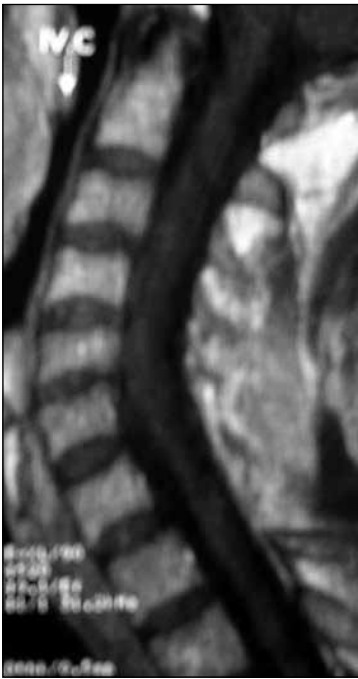

Figure 4: At 6 months post-operative, control MRI revealed there was no evidence of tumor's recurrence.

the local recurrence rate after initial gross total excision was 18% (4). The effectiveness of radiotherapy to prevent recurrence after initial gross total tumor excision is unclear (2). Furlong et al suggested that radiotherapy should be reserved for inoperable cases, thereby avoiding the potential for radiation-induced neurological damage and the smaller risk of post-radiation sarcoma (2). In our case, we were able to remove the tumor totally, and we did not carry out radiotherapy. There was no evidence of recurrence after 6 months (Figure 4).

In summary, TGT of the spine is rare and may present with symptoms of spinal cord compression. In the treatment of

TGT of the vertebral column, the main aim should be total surgical excision of the tumor.

REFERENCES

1. Bui-Mansfield LT, Youngberg RA, Coughlin W, Chooljian D: Case report. MRI of giant cell tumor of the tendon sheath in the cervical spine. *J Comput Assist Tomogr* 20: 113-115, 1996
2. Furlong MA, Motamedi K, Laskin W, Vinh TN, Murphey M, Sweet DE, Fetsch JF: Synovial-type giant cell tumors of the vertebral column: A clinicopathologic study of 15 cases, with a review of the literature and discussion of the differential diagnosis. *Hum Pathol* 34: 670-679, 2003
3. Gezen F, Akay KM, Aksu AY, Bedük A, Seber N: Spinal pigmented villonodular synovitis: A case report. *Spine* 21: 642-645, 1996
4. Giannini C, Scheithauer BW, Wenger DE, Unni KK: Pigmented villonodular synovitis of the spine: A clinical, radiological, and morphological study of 12 cases. *J Neurosurg* 84: 592-597, 1996
5. Hansen MA, Harper C, Yiannikas C, McGee-Collett M: A rare presentation of pigmented villonodular synovitis. *J Clin Neurosci* 14: 386-388, 2007
6. Myers BW, Masi AT: Pigmented villonodular synovitis and tenosynovitis: A clinical epidemiologic study of 166 cases and literature review. *Medicine* 59: 223-238, 1980
7. Samartzis D, Foster WC, Padgett D, Shen FH: Giant cell tumor of the lumbar spine: Operative management via spondylectomy and short-segment, 3-column reconstruction with pedicle recreation. *Surg Neurol* doi:10.1016/j.surneu.2007.01.038
8. Somerhausen NSA, Fletcher CDM: Diffuse-type giant cell tumor; clinicopathologic and immunohistochemical analysis of 50 cases with extraarticular disease. *Am J Surg Pathol* 24: 479-492, 2000
9. Weidner N, Challa VR, Bonsib SM, Davis CH, Carroll TJ: Giant cell of synovium (Pigmented Villonodular Synovitis) involving the vertebral column. *Cancer* 57: 2030-2036, 1986