



Penetrating Gunshot Wound to the Head: Transotic Approach to Remove the Bullet and Masseteric-Facial Nerve Anastomosis for Early Facial Reanimation

Kafanın Penetran Ateşli Silah Yaralanması: Kurşunu Çıkarmak için Transotik Yaklaşım ve Erken Fasiyal Reanimasyon için Masseterik-Fasiyal Sinir Anastomozu

Pasquale DONNARUMMA¹, Roberto TARANTINO¹, Paolo GENNARO², Valeria MITRO², Valentino VALENTINI², Giuseppe MAGLIULO³, Roberto DELFINI¹

¹Sapienza University of Rome, Department of Neurosurgery, Rome, Italy

²Sapienza University of Rome, Department of Maxillofacial Surgery, Rome, Italy

³Sapienza University of Rome, Department of Otorhinolaryngology, Rome, Italy

Corresponding Author: Pasquale DONNARUMMA / E-mail: padonnarumma@hotmail.it

ABSTRACT

INTRODUCTION: Gunshot wounds to the head (GSWH) account for the majority of penetrating brain injuries, and are the most lethal. Since they are rare in Europe, the number of neurosurgeons who have experienced this type of traumatic injury is decreasing, and fewer cases are reported in the literature.

CASE: We describe a case of gunshot to the temporal bone in which the bullet penetrated the skull resulting in the facial nerve paralysis. It was excised with the transotic approach. Microsurgical anastomosis among the masseteric nerve and the facial nerve was performed.

CONCLUSION: GSWH are often devastating. The in-hospital mortality for civilians with penetrating craniocerebral injury is very high. Survivors often have high rate of complications. When facial paralysis is present, masseteric-facial direct neurotomy represent a good treatment.

KEYWORDS: Gunshot wound, Head trauma, Facial palsy, Masseteric-facial neurotomy

ÖZ

GİRİŞ: Kafanın ateşli silah yaralanmaları penetran beyin yaralanmalarının çoğunluğunu oluşturur ve en öldürücü olanlardır. Avrupa'da nadir olduklarından bu tür travmatik yaralanma konusunda deneyimli beyin cerrahı sayısı azalmaktadır ve literatürde giderek daha az olgu bildirilmektedir.

OLGU: Kurşunun kafatasından girip fasiyal sinir paralizisine yol açtığı bir temporal kemik ateşli silah yaralanması olgusunu bildiriyoruz. Kurşun transotik yaklaşımla çıkarıldı. Masseterik sinir ile fasiyal sinir arasında mikrocerrahiyle anastomoz yapıldı.

SONUÇ: Kafanın ateşli silah yaralanmaları genellikle kötü seyirlidir. Penetran kraniyoserebral yaralanması olan sivil şahıslarda hastanede ölüm oranı çok yüksektir. Yaşayanlarda genellikle komplikasyon oranı yüksektir. Fasiyal paralişi bulunduğu anda, masseterik fasiyal direkt nörorafi iyi bir tedavidir.

ANAHTAR SÖZCÜKLER: Ateşli silah yaralanması, Kafa travması, Fasiyal palsi, Masseterik fasiyal nörorafi

INTRODUCTION

Gunshot wounds to the head (GSWH) account for the majority of penetrating brain injuries, and are the most lethal injuries among them. About two thirds die at the scene, and they are the proximal cause of death in 52-95 % of victims (5). Survivors often have significant disability which may include hemiparesis, cranial nerve palsy and seizures (11).

Since GSWH are rare in Europe, the number of neurosurgeons who have experienced this type of traumatic injury is

decreasing (8), and fewer cases are reported in the literature.

In this paper, the authors describe a case in which the bullet which penetrated the skull damaged the temporal bone and also the facial nerve. The bullet was excised with the transotic approach. In order to resolve facial nerve paralysis, the patient was presented to the successive surgical operation of microsurgical anastomosis among the masseteric nerve, the branch of the trigeminal nerve and the facial nerve that was affected by paralysis.

CASE PRESENTATION

A 45-year-old man who was injured in suicide attempts with a gun was carried to the emergency room of our hospital. On observation, it was possible to pick out the bullet entrance hole which shaped the round form in front of the right tragus with otorrhagia and otoliquorrhea right anacusia and total

paralysis of the right facial nerve. TC scan showed the bullet in the right petrous bone (Figure 1). GCS on admission was 12. A surgical operation with the transotic approach was carried out. After subtotal petrosectomy, the bullet composed of two parts of lead and copper, which destroyed the wall of the external auditive duct, the tympanic membrane and the ossicular chain, was found. In its process, the bullet went through the mastoid segment and the tympanic segment of the facial nerve, which resulted in its destruction, and caused injury of the inner ear and the semicircular canals. The bullet stopped at the point close to the jugular gulf. Moreover, its fragment destroyed the tegmen tympani whilst penetrating and passing through the dura mater of the FCP in the temporal lobe. From such continuous transections, the patient had CSF leak. The bullet and its fragments are fully removed. The surgical incision is closed with abdominal fat after obliterating the Eustachian tube and the external auditive duct in dead-end.

The patient showed a regular post-operative progress. He carried out a cycle of prophylactic antibiotic therapy and was discharged after fifteen days of the post-operative stay in hospital.

As aftereffects of the injury, the patient was having a complete paralysis of the right facial nerve (Grade VI - House Brackmann - No movement, loss of tone, no synkinesis, contracture, or spasm) (4). About eight months after the trauma and neurosurgical operation, the patient underwent a surgical procedure consisting of the reanimation of the right facial nerve through a direct neurorrhaphy with the ipsilateral masseteric nerve. After superficial parotidectomy following a skin incision in the region preauricular pretragus, the operation was preceded to the dissection of the main

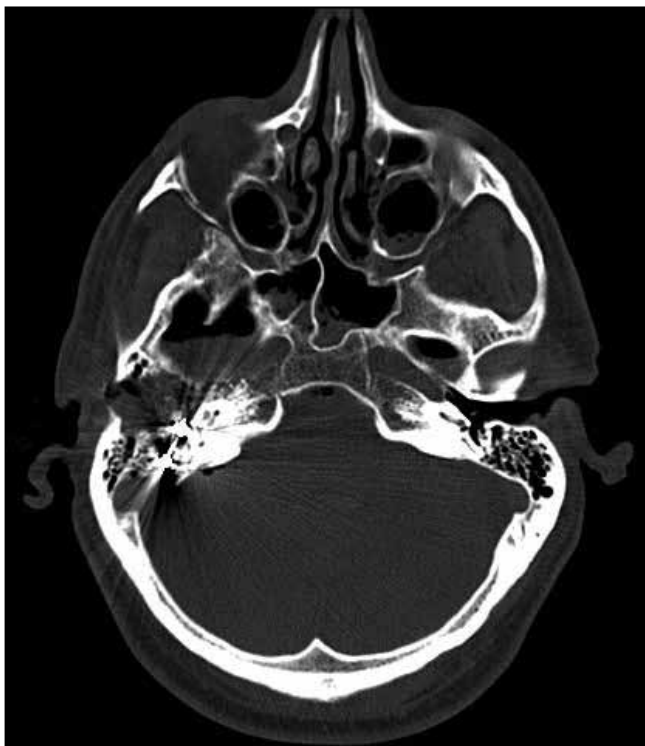

Figure 1: Preoperative CT scan.

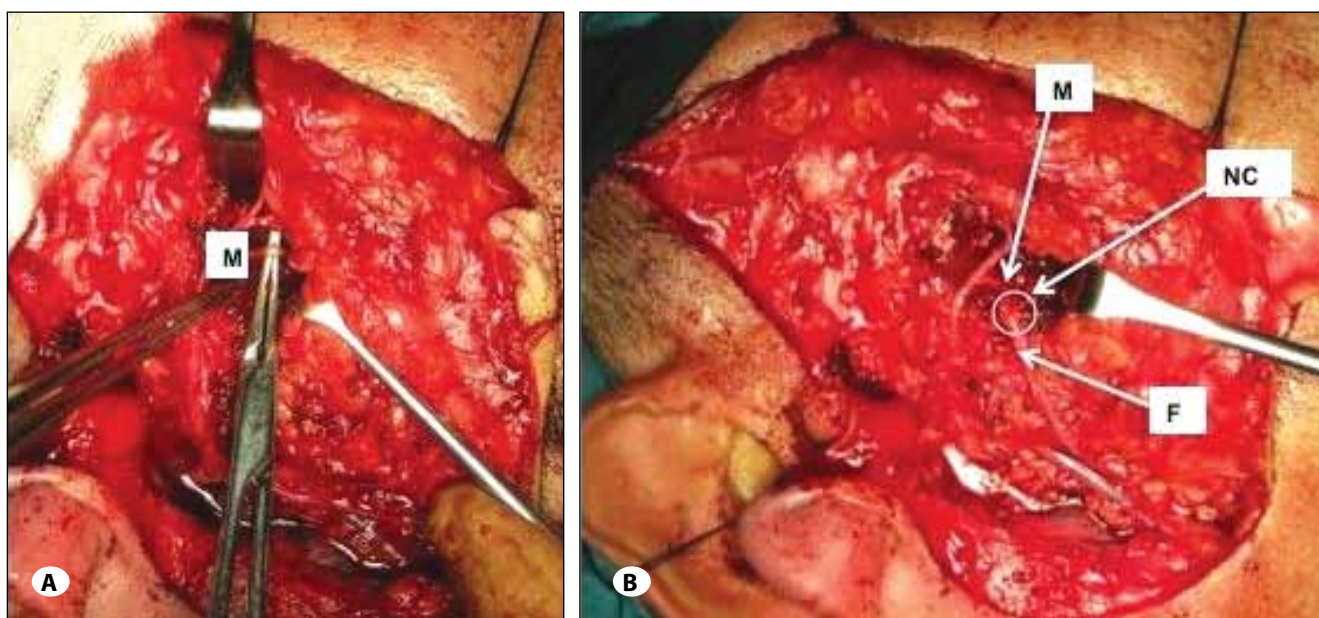


Figure 2: **A:** Intraoperative view of masseteric nerve (**M**). **B:** the main trunk of the facial nerve (**F**) has been sectioned and the distal segment anastomized in a microvascular nerve coaptation (**NC**) with the masseteric nerve.

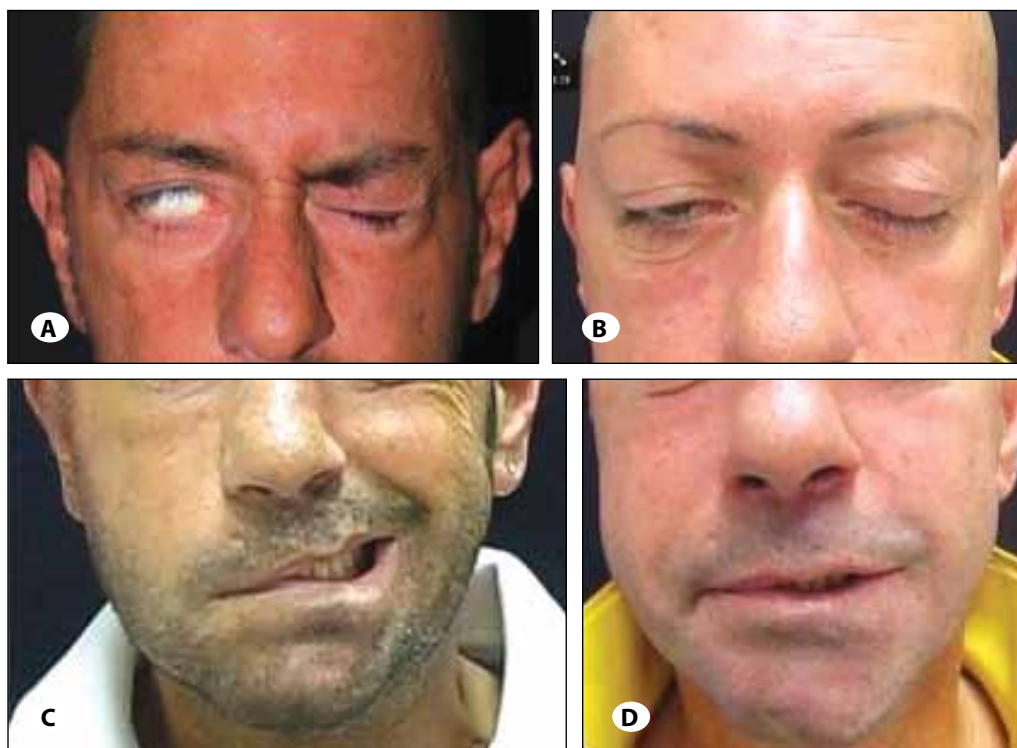

Figure 3: **A)** Preoperative and **B)** postoperative view of the face during eye closure. **C)** Preoperative view of the face during voluntary smile. **D)** Postoperative view of the face during masticatory movement.

branches of the facial nerve. Once identified, its main trunk was cut and folded. In the area outlined by the anterior border of the parotid gland, the posterior border of the masseter muscle, zygomatic arch cranially, and parotid duct inferiorly, the masseteric branch of the trigeminal nerve was exposed with blunt dissection of the masseter. The nerve was then sectioned as distally as possible to facilitate approximation of its stump to the facial nerve branches located more superficially, which were sectioned more proximally or distally depending on their distance from the masseteric nerve. Nerve coaptation was performed with a microscope and interrupted epineural sutures of 10-0 Nylon (Figure 2A,B). The post-operative follow-up was free from any complication. The patient underwent periodic clinical check-up for facial nerve restoration. Initial facial movements were observed three months after surgery.

The initial movements were evidently shown when the patient was clenching his teeth whilst activating the masseteric nerve. Finally at this point, the patient was sent to a Neurophysiologist for motor rehabilitation which brought progressive recovery of symmetry of the face, eyelid competence and active movements (Figure 3A-D).

DISCUSSION

Gunshot wounds to the head (GSWH) are rare in Europe. They could be due to assault/homicides, suicide attempts, or may be accidental. The incidence of suicide is significantly more common in Caucasian and varies considerably among the series from 5% to 88% (2, 9).

GSWH are often devastating. The in-hospital mortality for civilians with penetrating craniocerebral injury is 52-95%. The most important predictive factor is the Glasgow Coma Score (GCS). Survival is approximately 8.1% if GCS is 3-5, 35.6% if GCS is 6-8, and 90.5% if GCS is 9-15 (7,10). Survivors often have high rate of complications; motor deficits, brain abscess, epilepsy, vascular injuries (venous injury, traumatic aneurysm, arterial dissection, arterial occlusion, and arteriovenous fistulae), and CSF leak. CSF fistulas are a significant risk factor for infection. When a gunshot wound is present with signs of facial nerve paralysis it is always necessary to estimate the type of damage and possibility of recovery.

Important prognostic factors for an optimal recovery are the time passed from the onset and severity of paralysis (12). If there is a direct damage to the nerve and it is possible to recover its proximal and distal stumps the operation has to be precociously proceeded to the repair of damage by direct neurotaphy. If the proximal stump is not usable, as seen in the described case, it will have to be proceeded to nervous transposition.

The first attempts to use of the masseteric nerve as a donor motor nerve in facial reanimation were made in 1925 by Escat and Viela (3). Since then there have been anatomical studies by Brenner and Scholler (1), no large clinical series have been published yet. In 2000 Zuker et al. (13) popularized the use of the masseter motor nerve as donor source to reinnervate free gracilis flaps in patients affected by Moebius syndrome.

Our choice of the use of the masseteric nerve is motivated by the following three reasons: facility of finding, possibility

of direct neurography (without having necessity of using a nervous graft as used for the contralateral facial nerve) and rapidity of effective recovery. In addition to these, closeness of the cortical command to the masticator and mimic muscles makes what many authors define as cortical adaptation easier, which can restore not only tone and voluntary contractility but also spontaneous activation (6).

REFERENCES

1. Brenner E, Schoeller T: Masseteric nerve: A possible donor for facial nerve anastomosis? *Clin Anat* 11(6): 396-400, 1998
2. DuBose JJ, Barmparas G, Inaba K, Stein DM, Scalea T, Cancio LC, Cole J, Eastridge B, Blackbourne L: Isolated severe traumatic brain injuries sustained during combat operations: Demographics, mortality outcomes, and lessons to be learned from contrasts to civilian counterparts. *J Trauma* 70(1):11-16; discussion 16-18, 2011
3. Escat & Viela: Manuel operatoire de l'anastomose du nerf facial avec le nerf masseterin. *Ann Mal Oreille Larynx* 77:1149-1159, 1925
4. House JW, Brackmann DE: Facial nerve grading system. *Otolaryngol Head Neck Surg* 93(2):146-147, 1985
5. Kaufmann HH: Civilian gunshot wounds to the head. *Neurosurgery* 32: 962-964,1993
6. Lifchez SD, Matloub HS, Gosain AK: Cortical adaptation to restoration of smiling after free muscle transfer innervated by the nerve of masseter. *Plast Reconstr Surg* 115:1472-1479, 2005
7. Martins RS, Siqueira MG, Santos MT, Zanon-Collange N, Moraes OJ: Prognostic factors and treatment of penetrating gunshot wounds to the head. *Surg Neurol* 60(2):98-104,2003
8. Petridis AK, Doukas A, Barth H, Mehdorn M: Outcome of craniocerebral gunshot injuries in the civilian population. Prognostic factors and treatment options. *Cen Eur Neurosurg* 72(1):5-14, 2011
9. Pikus HJ, Ball PA: Characteristics of cerebral gunshot injuries in the rural setting. *Neurosurg Clin N Am* 6(4):611-620,1995
10. Rosenfeld JV: Gunshot injury to the head and spine. *J Clin Neurosci* 9(1):9-16,2002
11. Selden BS, Goodman JM, Cordell W, Rodman GH JR, Schnitzer PG: Outcome of self-inflicted gunshot wounds of the brain. *Ann Emerg Med* 17: 247-253, 1988
12. Ulug T, Arif Ulubil S: Management of facial paralysis in temporal bone fractures: A prospective study analyzing 11 operated fractures. *Am J Otolaryngol* 26(4):230-238,2005
13. Zucker RM, Goldberg CS, Manktelow RT: Facial animation in children with Moebius Syndrome after segmental gracilis muscle transplant. *Plast Reconstr Surg* 106:1-8,2000