

Technical Note

Endoscopic Endonasal Transclival Resection of the Upper Clival Meningioma

Omur GUNALDI, Hakan KINA, Osman TANRIVERDI, Uzey ERDOGAN, Lutfi Sinasi POSTALCI

Prof.Dr. Mazhar Osman Training and Research Hospital for Neurology, Neurosurgery and Psychiatry, Neurosurgery Clinic, Istanbul, Turkey



To watch the surgical videoclip, please visit <http://turkishneurosurgery.org.tr/images/17010-video.mp4>.

ABSTRACT

In recent years, endoscope use for the excision of brain stem lesions or those localized to the anterior part of the brain stem has started. In this paper, a case of upper clival meningioma resected through the endoscopic endonasal transclival route has been presented with illustrations, and live surgery videos demonstrating the surgery step-by-step.

A 35-year-old male patient presented with dysphagia and impaired consciousness. Magnetic resonance imaging (MRI) showed a mass lesion with a wide base located at the clivus and anterior part of brain stem. Following surgical preparations, the mass was resected through the endoscopic endonasal transclival route.

Presigmoid and lateral suboccipital approaches are the most popular methods for petroclival tumors. However, the disadvantages are restricted surgical corridor to reach the anterior lesions of the brain stem, and surgical manipulations that should be performed between the cranial nerves to gain access into the pathological structures. The alternative endoscopic endonasal transclival method, which is preferred to reach these lesions anteriorly, does not have these disadvantages. The endoscopic endonasal transclival route is suitable for meningiomas located in the retroclival area. With advances in endoscopic technology and surgical experience, full endoscopic endonasal transclival approach will be an alternative for the treatment of posterior circulation aneurysms, most of the extradural and intradural lesions of the ventral aspect of brain stem, and neuralgia secondary to vascular compression.

KEYWORDS: Endoscopic approach, Transclival route, Clival meningioma, Resection

■ INTRODUCTION

Surgical resection of intradural lesions of the upper clival region through the transclival route during endoscopic endonasal transsphenoidal (EET) surgery is an extreme point of this technique that challenges the limits of this method. This method encompasses serious risks, and requires advanced experience (3,8,12,13).

In this paper, we have presented a case of upper clival meningioma resected through the endoscopic endonasal transclival route. We discussed this case in the light of literature

with illustrations, and live surgery video demonstrating the surgery step-by-step.

■ SURGICAL TECHNIQUE

A 35-year-old male patient presented to the emergency service with complaints of hoarseness, dysphagia, impaired walking, and respiratory distress lasting for 2 months. On physical examination, no pathology other than wheezing or aspiration pneumonia was detected. On neurological examination the patient was oriented and cooperative and conscious with



Corresponding author: Omur GUNALDI

E-mail: omurgunaldi@gmail.com

normal upper cranial nerve examination findings. Wheezing and nasal speech were detected. Loss of strength involving the upper and lower extremity muscles was not present. The gag reflex (pharyngeal reflex) could not be elicited. Cranial computed tomography (CT) revealed a mass lesion in the anterior aspect of the pons and contrast-enhanced cranial magnetic resonance imaging (MRI) was requested (Figure 1). On MRI, a mass lesion, with dimensions of 3x4x3 cm resting on clivus with its large base that pushed the pons very strongly to the posterior and the basilar artery to the right side, was observed. The mass lesion, with homogenous contrast

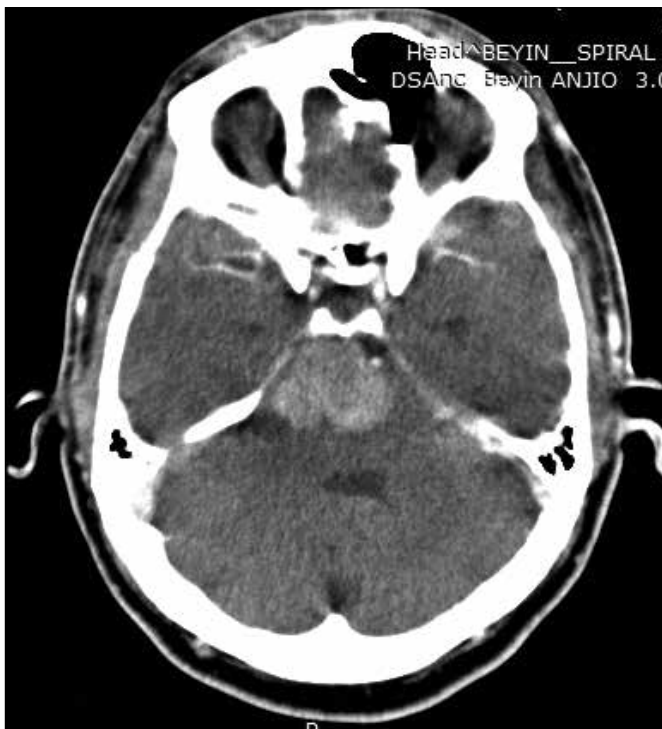


Figure 1: Cranial CT scan showed that hyperdense mass lesion between clivus and brain stem.

enhancement, extended from the upper part of the clivus down to the lower part of the pons, and the pontocerebellar junction (Figure 2A-C). Since the patient had sellar type sphenoid sinus with appropriate aeration, the decision for EET surgery was made, and preparations for surgery were initiated.

Surgical Procedure

A 0° endoscope was inserted through the right nostril, and the middle concha was lateralized. Then, after visualization of the right sphenoid ostium, a vascularized flap was prepared from the nasal septum for reconstruction. The middle concha was lateralized through the left nostril and the left sphenoid ostium was approached. Then, posterior septectomy was performed using the right and left nostrils. The anterior wall of the sphenoid sinus was resected using a high-speed drill. The septum inside the sphenoid sinus was resected. Following excision of the mucosa lining inside the sphenoid sinus, the sella, clivus, and bilateral carotid prominences were exposed. The projection of the internal carotid artery, sella, clivus and tumor on the clivus was determined using neuronavigation. Then, the clivus was drilled with a high-speed drill upwards to the sella, laterally to the carotid prominences, and inferiorly to the base of the sphenoid sinus so as to expose the dura mater. The entire surface of the dura was cauterized using bipolar cautery in order to prevent potential venous bleedings and cut the feeder of the tumor that may arise from the basilar plexus at the beginning of procedure. The dura was opened first from the midline to inspect the tumoral tissue. Afterwards, leaflets of dura were cauterized with bipolar cautery, and peeled away upward and laterally from the tumor to expose the dura mater. Then, the anterior surface of the tumoral mass was explored. Following cauterization of the anterior wall of the tumor with bipolar cautery, biopsy specimens were excised from inside the tumor for diagnostic purposes. The tumor was debulked using an ultrasonic aspirator, and the content of the tumor was evacuated. Inferior and lateral borders of the tumor were identified, dissected away from the brain stem as far as possible, and resected. The basilar artery and anterior inferior cerebellar artery (AICA) were visualized at the left side of the

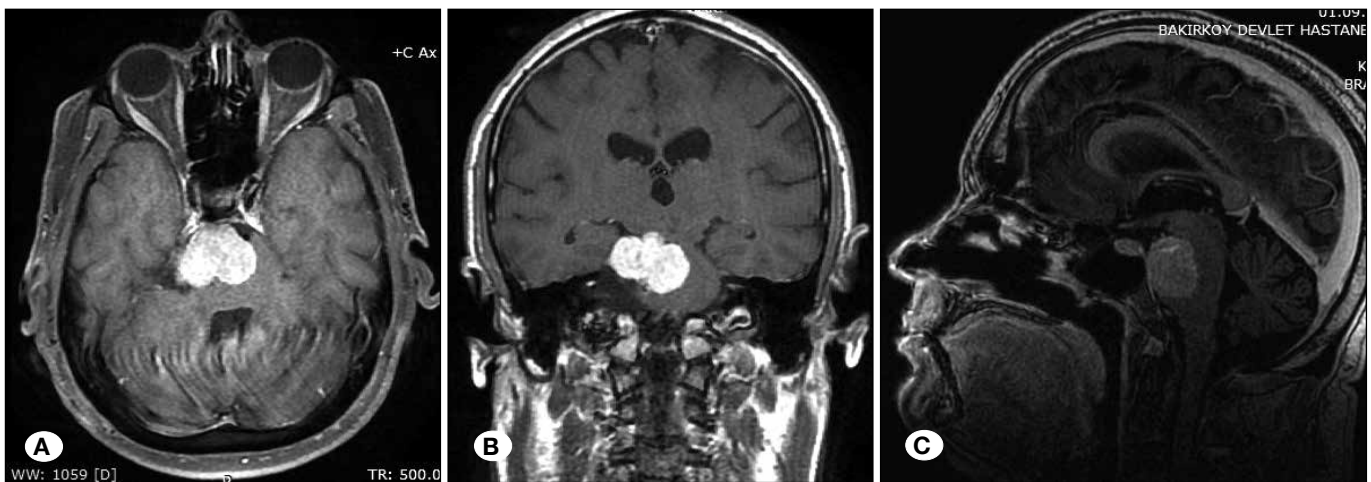


Figure 2: A) Axial, B) Coronal, C) Sagittal T1-weighted contrast-enhanced cranial MRI showed a mass lesion between the clivus and brain stem. The tumor size is 3x4 cm.

tumor. Since the tumor was adherent to the brain stem, and to the vascular structures from its inferior aspect, these parts could not be accessed and the superior part of the right side of the tumor was left intact. A fascia specimen excised from fascia lata was placed on the inner and outer parts of dura mater, and a vascularized nasoseptal flap was spread on the defect. After using tissue sealant, the sphenoid sinus was filled with fat graft, and surgery was terminated. Contrast-enhanced cranial MRI obtained at postoperative 1st month revealed that majority of the tumor was resected (Video). However, a 1.5x0.5 cm residual tumor tissue was observed on the right side and the upper part where the tumor was adherent to the

brain stem. However, compression on the pons was relieved to a large extent (Figure 3A, B). Re-operation through the transcranial approach was offered to the patient. The patient did not accept the second surgery. The patient was sent to Gamma Knife radiosurgery for the treatment of the residual tumor one month after surgery (Figure 4A, B).

■ DISCUSSION

The most frequently used method for approaching lesions of the upper clival region is the lateral suboccipital approach which was first described by Dandy in 1925. The advantages of

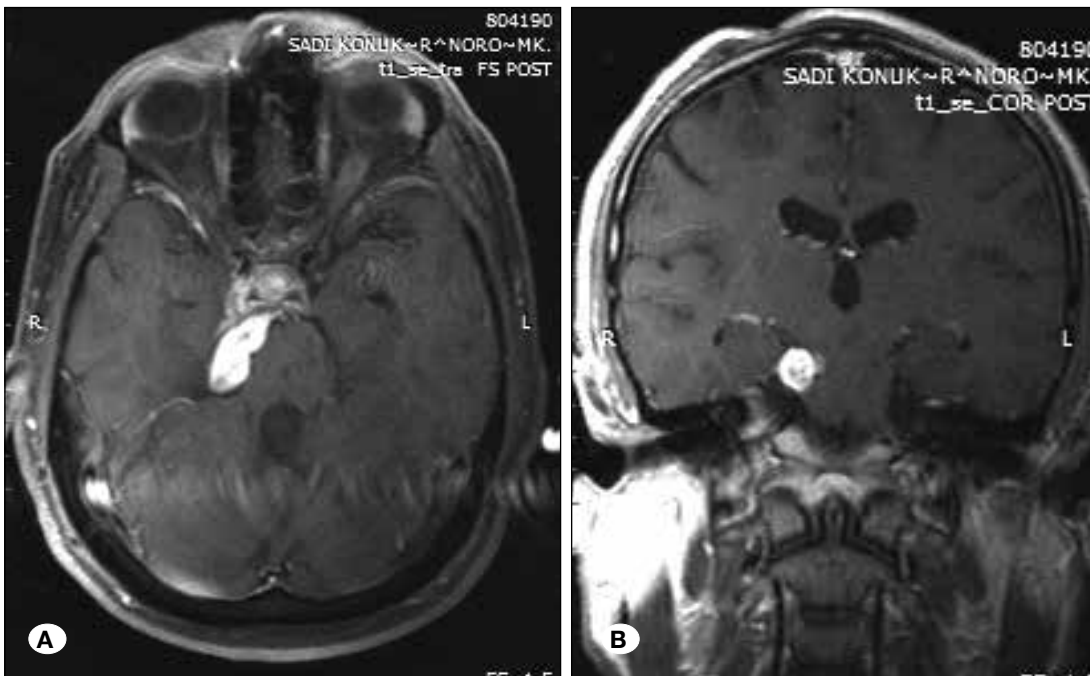


Figure 3: Postoperative 6th month, **A)** Axial, **B)** Coronal T1-weighted contrast-enhanced cranial MRI showed 1.5 cm residual tumor at the right upper part of brain stem.

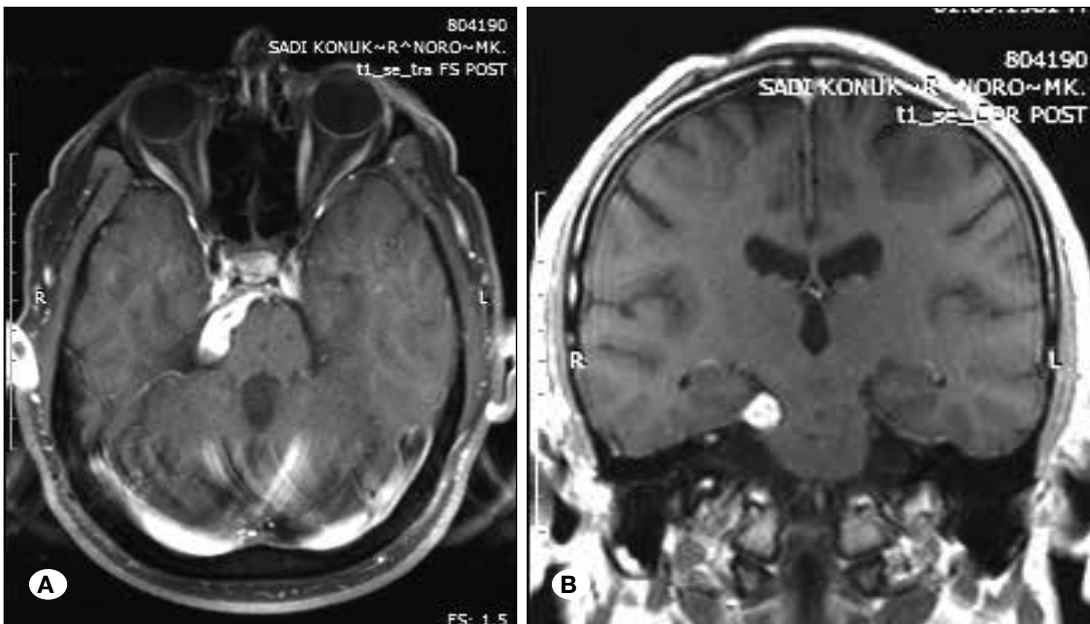


Figure 4: Post-Gamma-Knife 3rd month, **A)** Axial, **B)** Coronal T1-weighted contrast-enhanced cranial MRI showed 1.5 cm residual tumor with central necrosis at right upper part of brain stem.

this approach include its being a physiological route, minimal neural retraction, and smaller amount of craniectomy (4). However, the restricted surgical corridor when approaching anterior lesions of the brain stem, and surgical manipulations that should be performed between cranial nerves to gain access to pathological structures have led the surgeons to use the transsylvian and combined petrosal, presigmoid, subtemporal, and far-lateral approaches. These approaches have ensured improved access to ventral brain stem lesions, and a decreased rate of important complications such as larger bone resection, cranial neuropathy, hemiparesis, and postoperative coma (2,13).

Thanks to the extended EET approach, the targeted lesion can be approached, and improved inspection of the lesion can be ensured through a narrow, but useful corridor with minimal impairment of the normal tissue (14). Zhou et al. performed a study on 24 cases with petroclival meningioma, and used endoscopy-aided microsurgery (n=12), and sole microsurgery. In the neuroendoscope-aided group, total (n=6), subtotal (n=5), and most (n=1) resection could be achieved, while in the microsurgery group, total (n=2), subtotal (n=3), and most (n=7) resection could be realized. They found that rates of both total and subtotal resection in the neuroendoscope-aided group were significantly higher than those of the microsurgery group, but they could not detect an intergroup difference for short- and long-term complication rates (16).

Beer-Furlan et al. indicated that the resection of ventral posterior fossa meningiomas through an EET approach is a safe and feasible method (1). Kassam et al. reported a case where a vertebral artery aneurysm had been endoscopically clipped via the transclival approach (8). After this report, many case reports concerning various types of aneurysms have been presented (5,6,9,10). Rajappa et al. reported a case of pontine ependymoma that was subtotally excised in a 16-year-old patient (12). Dallon et al. reported a bleeding pontine cavernoma that was subtotally extirpated (3). An additional cranial nerve neuropathy had not developed in either of these patients, and even the neurological manifestations recovered after surgery.

EET approach offers important advantages for lesions of the skull base. After the exposure of dura mater, the EET approach provides early access to major vessels, and minimizes retraction of brain and manipulation of the cranial nerve. Besides, although the EET approach was not applied for our case, it allows gross total excision due to extraction of tumor together with surrounding dura mater (11). Its disadvantages include restricted exploration, and inability to perform water-tight closure of dura with resultant risk of cerebrospinal fluid (CSF) fistula, and meningitis (14). In order to prevent complications of CSF fistula, and intracranial infection, endoscopic repair can be performed using vascularized or free grafts and 3-layer reconstruction (15).

In our surgical technique, as reported previously in cadaver studies and case reports, it seems to be possible to approach the clivus, extradural and intradural lesions located on the posterior part of the clivus, and intra-axial lesions in

the anterior part of the brain stem in addition to the upper clival region. To minimize complication rates, technological opportunities including use of neuronavigation and brain stem neuromonitoring should be used (15). Postoperatively, a vascularized nasoseptal flap should be prepared at least from one side, and preferably from both sides for the reconstruction of dura, and it should be used for closure. It should not be forgotten that the risk of CSF fistula is high in this approach. Continuous lumbar drainage, immobilization for the first 2 days after surgery so as to prevent sudden increase in intracranial pressure, bed rest, antiemetics, antitussives, and laxatives are recommended (7).

■ CONCLUSION

If aeration of the sphenoidal sinus together with the clivus-lesion relationship is suitable, the EET route provides a straightforward, easier, more reliable, and less-complicated approach for upper clival meningiomas. The most important surgical stages of this approach include preservation of the neurovascular structures with the aid of technological facilities, and meticulous reconstruction of the skull base. With advances in endoscopic technology, and surgical experience, we believe that a full EET approach will be an alternative in the future for the treatment of posterior circulation aneurysms and extradural/intradural lesions of the ventral aspect of the brain stem.

■ REFERENCES

1. Beer-Furlan A, Vellutini EA, Balsalobre L, Stamm AC: Endoscopic endonasal approach to ventral posterior fossa meningiomas: From case selection to surgical management. *Neurosurg Clin N Am* 26(3): 413-426, 2015
2. Cobb WS, Makosch G, Anand VK, Schwartz TH: Endoscopic transsphenoidal, transclival resection of an enterogenous cyst located ventral to the brainstem: Case report. *Neurosurgery* 67(2): 522-526, 2010
3. Dallon I, Battaglia P, de Notaris M, Caniglia M, Turri-Zanoni M: Endoscopic endonasal transclival approach to a pontine cavernous malformation: Case report. *Int J Pediatr Otorhinolaryngol* 79: 1584-1588, 2015
4. Dandy W: An operation for the total removal of cerebello-pontine (acoustic) tumors. *Surg Gynecol Obstet* 41: 129-148, 1925
5. Ensenat J, Alobid I, De Notaris M, Sanchez M, Valero R, Prats-Galino A, Ferrer E: Endoscopic endonasal clipping of a ruptured vertebral-posterior inferior cerebellar artery aneurysm: Technical case report. *Neurosurgery* 69: 121-128, 2011
6. Germanwala AV, Zanation AM: Endoscopic endonasal approach for clipping of ruptured and unruptured paraclinoid cerebral aneurysms: Case report. *Neurosurgery* 68: 234-240, 2011
7. Hadad G, Bassagasteguy L, Carrau RL, Mataza JC, Kassam AB, Snyderman CH, Mintz A: A novel reconstructive technique after endoscopic expanded endonasal approaches: Vascular pedicle nasoseptal flap. *Laryngoscope* 116: 1882-1886, 2006

8. Kassam AB, Mintz AH, Gardner PA, Horowitz MB, Carrau RL, Snyderman CH: The expanded endonasal approach for an endoscopic transnasal clipping and aneurysmorrhaphy of a large vertebral artery aneurysm: Technical case report. *Neurosurgery* 59: 162–165, 2006
9. Kassam AB, Gardner PA, Mintz A, Snyderman CH, Carrau RL, Horowitz MB: Endoscopic endonasal clipping of an unsecured superior hypophyseal artery aneurysm. Technical note. *J Neurosurg* 107: 1047–1052, 2007
10. Kitano M, Taneda M: Extended transsphenoidal approach to anterior communicating artery aneurysm: Aneurysm incidentally identified during macroadenoma resection: Technical case report. *Neurosurgery* 61: 299–300, 2007
11. Koutourousiou M, Fernandez-Miranda JC, Stefko ST, Wang EW, Snyderman CH, Gardner PA: Endoscopic endonasal surgery for suprasellar meningiomas: Experience with 75 patients. *J Neurosurg* 120(6): 1326–1339, 2014
12. Rajappa P, Margetis K, Sigounas D, Anand V, Schwartz TH, Greenfield JP: Endoscopic endonasal transclival approach to a ventral pontine pediatric ependymoma. *J Neurosurg Pediatr* 12: 465–468, 2013
13. Rhoton AL Jr, Tedeschi H: Lateral approaches to the cerebellopontine angle and petroclival region. *Clin Neurosurg* 41: 517–545, 1994
14. Sanborn MR, Kramarz MJ, Storm PB, Adappa ND, Palmer JN, Lee JY: Endoscopic, endonasal, transclival resection of a pontine cavernoma: Case report. *Neurosurgery* 71(1): 198–203, 2012
15. Snyderman CH, Pant H, Carrau RL, Prevedello D, Gardner PA, Kassam AB: What are the limits of endoscopic sinus surgery? The expanded endonasal approach to the skull base. *Keio J Med* 58: 152–160, 2009
16. Zhou QJ, Liu B, Geng DJ, Fu Q, Cheng XJ, Kadeer K, DU GJ, Wang YX, Luan XP: Microsurgery with or without neuroendoscopy in petroclival meningiomas. *Turk Neurosurg* 25(2): 231–238, 2015