

*Original Investigation*

Complications of 2-Level Dynamic Stabilization: A Correlative Clinical and Radiological Analysis at Two-Year Follow-up on 103 Patients

Necati Mert CIPLAK¹, Tuncer SUZER¹, Salim SENTURK¹, Onur YAMAN¹, Mehdi SASANI¹, Tunc OKTENOGU¹, Atila YILMAZ², Deniz Ufuk ERBULUT³, Ali Fahir OZER¹

¹Koc University, School of Medicine, Department of Neurosurgery, Istanbul, Turkey

²Mustafa Kemal University, School of Medicine, Department of Neurosurgery, Hatay, Turkey

³Medipol University, Department of Biomedical Engineering, Istanbul, Turkey

ABSTRACT

AIM: To investigate the postoperative complications, such as screw loosening, screw breakage and adjacent segment disease (ASD), in patients who underwent surgery with 2-level dynamic stabilization systems.

MATERIAL and METHODS: Postoperative complications, clinical improvements and radiological parameters in patients who underwent surgery using a dynamic system for 2-level lumbar stabilization were retrospectively reviewed. A total of 103 patients with lumbar degenerative spinal instability underwent 2-level dynamic stabilization. Clinical findings were reviewed at 2-year follow-up. Screw breakage and loosening were evaluated during this duration together with clinical findings.

RESULTS: Visual analog scale (VAS) and Oswestry Disability Index (ODI) scores were significantly decreased at the four-month evaluation, and they were also decreased at the 1-year follow up and at the 24th postoperative month. ASD was diagnosed in twelve (8 females, 4 males) of the 103 patients in the follow-up radiological and clinical controls. There were 9 screw breakages and 4 screw loosening cases. The complication rate of 2-level dynamic stabilization was high in this study.

CONCLUSION: Our results showed that complications (screw loosening or breakage and adjacent segment disease) are not rare after 2-level dynamic stabilization, unlike the acceptable results with the single-level dynamic system. The most probable explanation is that the instrument system behaves more rigidly with every additional segment.

KEYWORDS: Dynamic rod, Dynamic stabilization, Dynamic system, Hinged screw, Lumbar degenerative disease

INTRODUCTION

Painful black disc, degenerative spondylolisthesis, painful disc after discectomy and recurrent disc herniation with back pain share the same pathology, which is called "segmental instability". They are a part of a degenerative disc disease. Inadequate surgery for these disorders lead to unfavorable clinical results called failed back surgery syndrome (FBS).

Until the 1990s, the first technique to avoid instability was to perform the operation with due diligence; and the second was to perform fusion. Fusion is a generally accepted operation; however, it has some potential risks. Particularly in elderly patients, if serious complications occur, even the preoperative condition may be preferred.

Henri Graff is the first author who described dynamic stabilization in 1992 (5). He developed the Graff artificial ligament stabilization system that used rigid rods without



Corresponding author: Ali Fahir OZER

E-mail: alifahirozer@gmail.com

fusion for transpedicular stabilization. This system was the first milestone in non-fusion stabilization. However, this system was mechanically weak in hyperflexion and caused foraminal narrowing in compression. Dynesys was developed because of the weak points of Graff's system. The second milestone in non-fusion stabilization was the dynamic screw that was first introduced by Archibald von Strempel (16).

The market currently accommodates two different systems that serve this purpose: dynamic rods and dynamic screws. These two systems (dynamic rods and dynamic screws) can be used together in some patients. Oktenoglu et al. showed that the dynamic screws and dynamic rods stabilize the unstable spine in cadavers and finite element study (11).

On the other hand, dynamic screws with rigid rods are recommended in 2-level stabilization, because rigid rods decrease motion when the number of segments increases.

This study reports the underestimated instrumentation complications and results of patient satisfaction in 103 patients who underwent 2-level lumbar stabilization with the dynamic screw-rigid rod systems.

■ MATERIAL and METHODS

Patient Characteristics

We performed 2-level stabilization surgery with hinged screws (6 dynamic screws and 2 rigid rods) in 103 patients (46 men and 57 women) with lumbar segmental instability. The mean patient age was 46.2 years (range, 17-80 years). In order to avoid the complications of fusion surgery, dynamic stabilization has been developed.

The spinal levels of surgery were L4-S1 in 71 patients, L3-L5 in 28 patients, L2-4 in 3 patients and L1-3 in 1 patient (Table I). In 75 of the 103 patients, dynamic stabilization was the initial surgery, because their main diagnosis was segmental instability. On the other hand, 28 patients had undergone a second surgery. Segmental instability had developed after a microlumbar discectomy procedure in this group. In addition to spinal instrumentation, decompression was performed on 72 of the 103 patients in the same session.

Clinical and Radiological Evaluations

The visual analog scale (VAS) and Oswestry Disability Index (ODI) pain scores were used to evaluate pain and the quality of life preoperatively and during the follow-up period at 4, 12 and 24 postoperative months. The pain scores from all patients were compared at each time interval to assess their individual clinical situations.

Radiological investigations, including plain films, functional lateral X-rays, computed tomography (CT) and magnetic resonance imaging (MRI) were performed for all patients before surgery. During the follow-up period, radiographs were obtained and investigated during control instrumented examinations for all 103 patients; however, CT or MRI scans were performed on patients who had postoperative complaints such as implant failures (screw loosening or screw breakage). These implant failures have been also recorded.

Radiological evaluations were performed with assessments of the segmental lordosis angle (SLA) and lumbar lordosis angle (LLA). Moreover, the intervertebral space ratio (IVS) was measured in the upper (IVS 1) and lower (IVS 2) levels and all data obtained were recorded (Figure 1).

Adjacent Segment Disease (ASD) was diagnosed with both clinical and radiological findings. Criteria were clinical pain, which was evaluated by the pain score and radiologically by ASD and deterioration of the adjacent disc in different grades. Our results are shown in Table II.

Preoperatively bone mineral density (BMD) was measured by DEXA Scan, and the results are given in Table I.

Operative Technique

Standard transpedicular instrumentation was performed on the patients. We applied dynamic screw with a rigid rod system (Cosmic [Ulrich GmbH, Ulm, Germany] and Safinaz [Medikon, Ankara, Turkey]) to stabilize the unstable segments (Figures 2, 3).

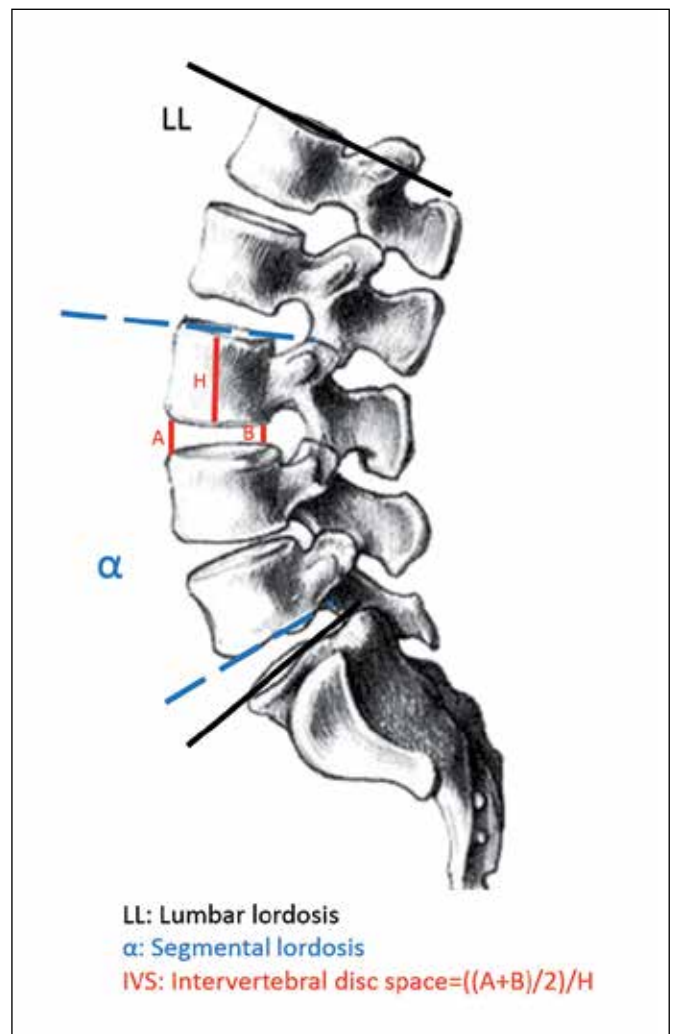


Figure 1: Lumbar segmental lordosis, lumbar lordosis and intervertebral disc space were used as radiological measurements.

Table I: Summary of Patient Characteristics

No. of patients	103
Sex	
Male (n, %)	46 (44.6%)
Female (n, %)	57 (55.4%)
Mean age (years)	46.2 (17-80)
Mean follow-up (months)	32.7
Smoker (n, %)	58 patients (56.3%)
Weight (kg)	71.67 kg (49-94) Mean BMI 23.3
BMD	64 patients: <50 years-old; 2 patients with osteopenia 22 patients: 50-60 years-old; 7 patients with osteoporosis and 8 patients osteopenia 8 patients: 60-70 years-old; 8 patients with osteoporosis 9 patients: 70-80 years-old; 9 patients with osteoporosis
Level of Surgery	
L1-L3	1 patient
L2-L4	3 patients
L3-L5	28 patients
L4-S1	71 patients

BMI: Body mass index, **BMD:** Bone mineral density.

Table II: List of Complications After 2-Level Dynamic Stabilization

Screw breakage	9 patients (8.7%)	3 revisions
Screw loosening	4 patients (3.9%)	2 revisions
Adjacent segment disease	12 patients (11.7%)	8 revisions
Screw breakage and loosening together	1 patient (0.9%)	1 revision

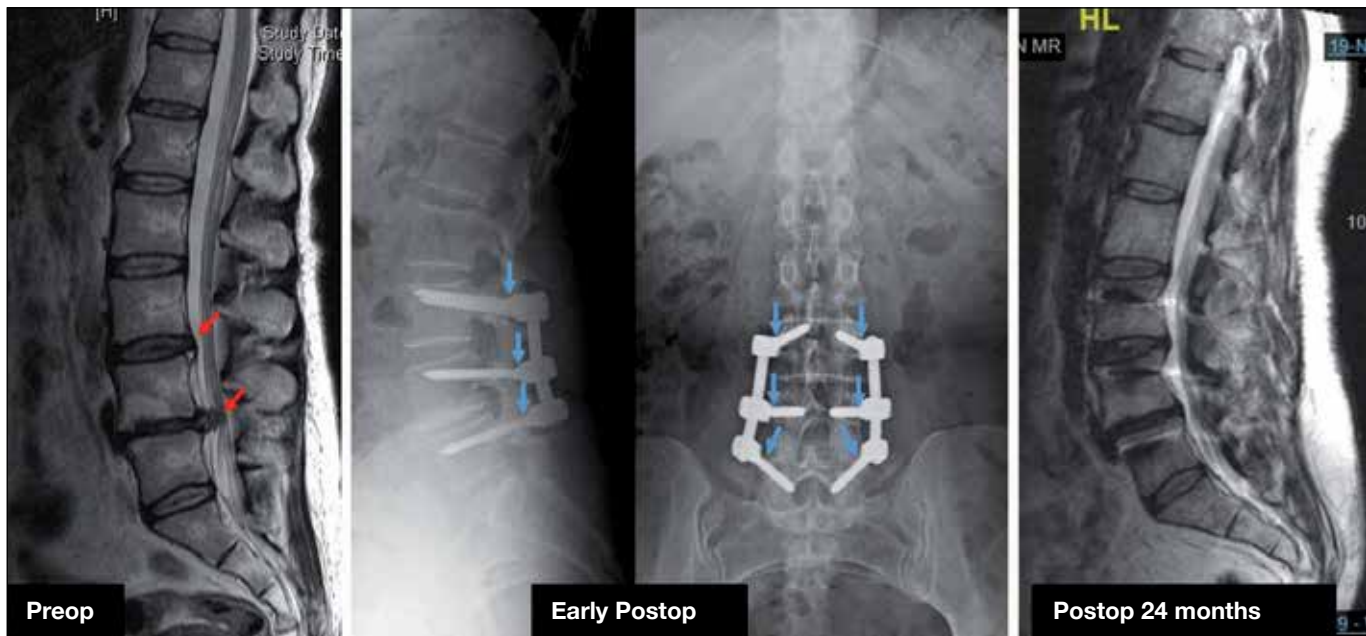


Figure 2: A 40-year-old female patient with 2-level degenerative disc disease (red arrows) was treated with the cosmic system. The screws have hinges between the head and body of the screw (blue arrow).

■ RESULTS

All patients were evaluated at the 4th, 12th and 24th postoperative months (mean follow-up, 32.7 months). Clinical and radiological assessments were recorded.

Complications

Misplacement of the screws, pseudomeningocele, hematoma, infection, neurological worsening or impaired wound healing was not detected in any of the patients; therefore, no early intervention was indicated. The main complications are summarized in Table II.

ASD was diagnosed in twelve (8 females, 4 males) of the 103 patients in the follow-up radiological and clinical controls, and 8 of these 12 patients underwent further operations because of severe pain (Figure 4).

Screw breakage occurred in 9 patients (2 females, 7 males, all younger than 50 years of age), and screw revision was performed on 3 patients (Figure 5). Screw breakage mostly occurred within 2 years after the instrumentation. All broken screws were in the caudal spine.

Screw loosening occurred in 4 patients (2 females, 2 males), and screws were revised in 2 of these 4 patients (Figure 6).

Most of the loosening events occurred in the first 3 months after the surgery and were located in the caudal spine, like the patients with screw breakage. However, these patients were older than 50 years of age, and osteoporosis was prominent. In one female patient, both screw fracture and screw loosening occurred, and the system was revised.

Clinical Assessment

The mean preoperative VAS and ODI scores were 7.2 and 65.9, respectively (Figure 7). During the 4-month postoperative evaluation, the VAS and ODI scores decreased significantly to 3.9 and 31.6, respectively. The decline in the VAS and ODI scores continued at the 1st year follow-up (2.8 and 24.1, respectively). This decrease in the follow-up scores was also observed at the 24th postoperative month (2.7 and 23.1, respectively).

Radiological Assessment

The radiological assessment results are summarized in Table III. The mean preoperative LLA and SLA were 43.1° and 25.7°, respectively. These angles were not found to be statistically significant for the postoperative follow-up assessments at 4 months (42.9°/25.7°), 12 months (43.3°/25.7°) and 24 months (43.1°/25.9°).

Table III: Results of Lumbar and Segmental Lordotic Angles and Intervertebral Space Ratios

	Preop	Postop 4 months	Postop 12 months	Postop 24 months
LLA	43.1	42.9	43.3	43.1
SLA	25.7	25.7	25.7	25.9
IVS 1	0.28	0.29	0.28	0.28
IVS 2	0.26	0.27	0.26	0.27

LLA: Lumbar lordosis angle, **SLA:** Segmental lordosis angle, **IVS:** Intervertebral space ratio, **Preop:** Preoperative, **Postop:** Postoperative.

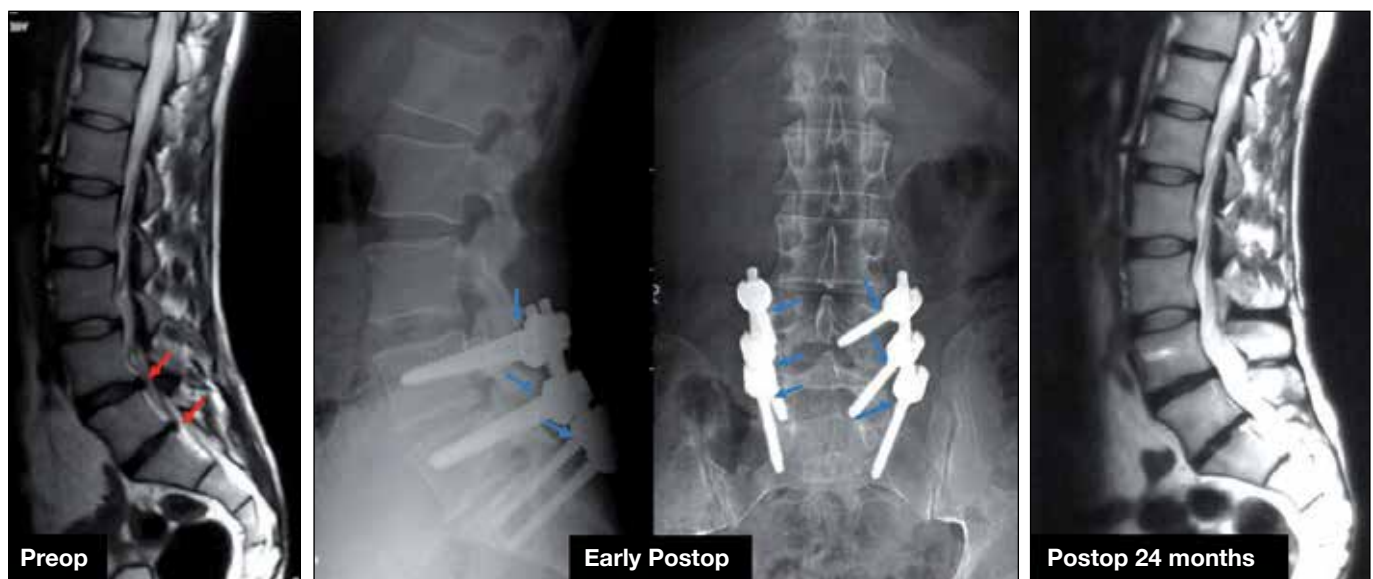

Figure 3: A 55-year-old male patient had 2-level degenerative disc disease (red arrow) that was treated with the Safinaz system (the blue arrow shows dynamic head).

At 4 months (0.29/0.27), 12 months (0.28/0.26) and 24 months (0.28/0.27), the mean postoperative IVS1 and IVS2 ratios were not significantly different from the preoperative ratios (0.28/0.26).

DISCUSSION

Pain is a major symptom in patients with lumbar instability (18). Neurological findings, such as weakness, may be observed, but they are rare symptoms in these patients. Therefore, fusion has always been considered as a surgical method to stabilize the spine but reports about fusion-related complications are increasing with time (6-8,10,20). Dynamic stabilization was used for patients who had segmental instability, without the

necessity for spinal fusion with great hope to prevent fusion-related complications (15,21,22). In one-level surgery, the complication rate is quite low regardless of which dynamic system is used. We noticed that dynamic stabilization in more than one level has some problems too and the complication rate is almost similar with rigid systems.

Pihlajamaki et al. have reported hardware failure (screw loosening or breakage) in 39 of 102 patients with lumbosacral fusion (13). A recent study that investigated the rate of screw failure using F-fluoride PET/CT has reported proven screw loosening in 20 of 59 patients who had pain after fusion surgery (17). It is generally believed that the incidence of screw failure varies from 2.6% to 36% (9). One paper has reported that the

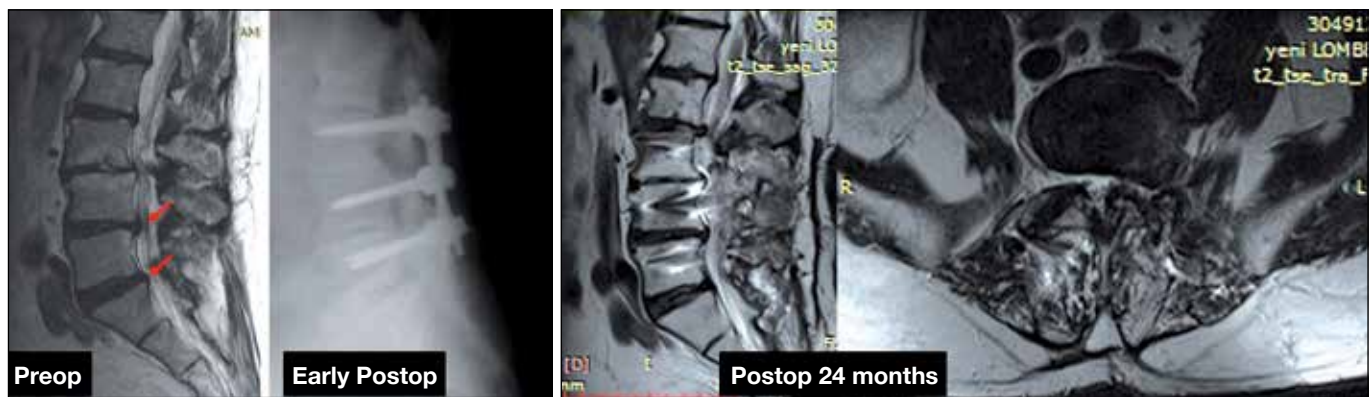

Figure 4: A 57-year-old male patient with spinal canal stenosis was treated with the 2-level dynamic system. Adjacent segment disease developed two years after the operation.

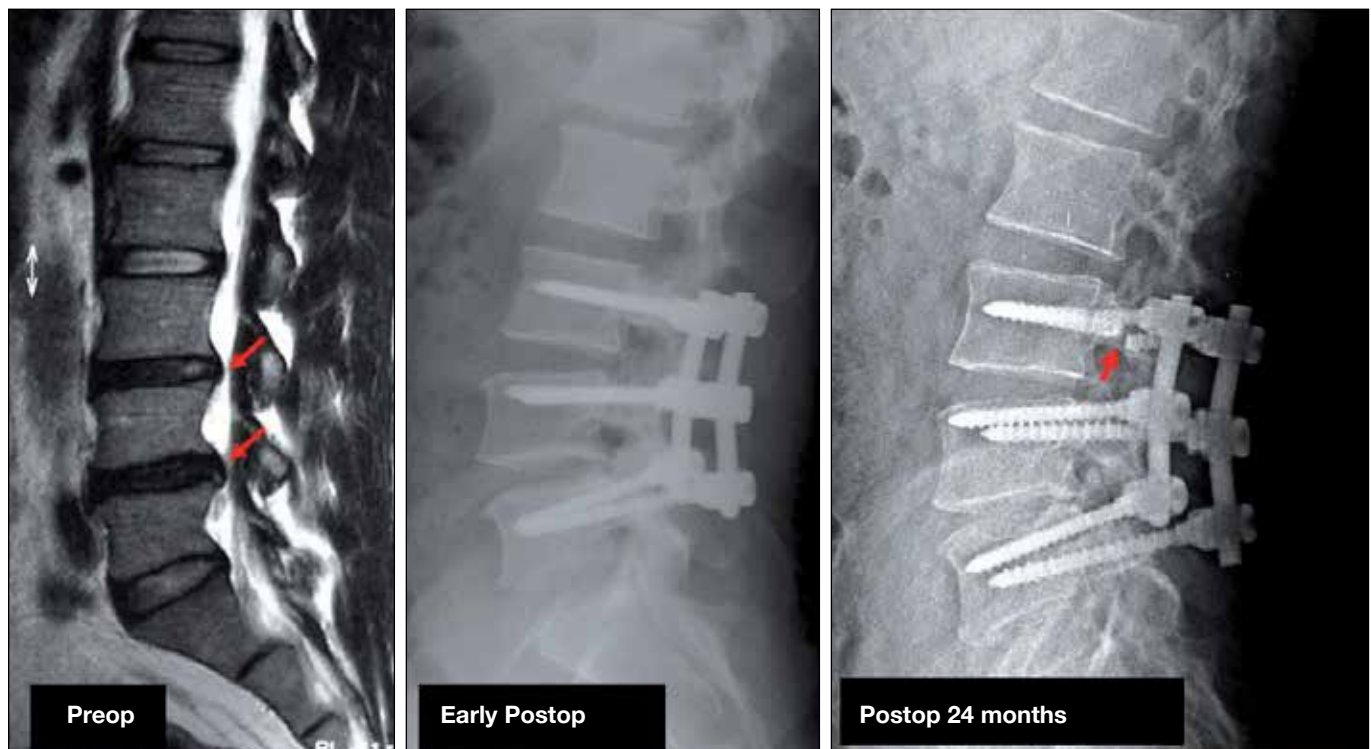


Figure 5: Dynamic screw breakage is observed at the 2-year postoperative follow-up.

incidence of ASD ranged from 5.2 to 100% from a radiological standpoint; however, the incidence of symptomatic patients ranged from 5.2 to 18.5% after fusion surgery (12). In the patient series of Wu et al., which included 126 patients and 658 screws, the authors have reported screw loosening in 25 patients (19.8%) and screw breakage in 3 patients (23).

In a series of 83 patients with degenerative conditions that were treated with a dynamic system, Stoll et al. have reported the necessity of additional operations, including implant removal, conversion into fusion surgery, screw problems and ASD (19). Schaeren et al. have reported similar problems in 26 patients after a minimum four-year follow-up. The authors concluded that degeneration at an adjacent segment was still a problem after dynamic stabilization (14).

It is known that the posterior column would become more rigid when the dynamic screw system is used in multi-level mobile segments; thus, anterior and posterior columns would be even more incompatible, and the system would become a rigid system after fusion surgery. Therefore, the resulting complications would also be similar to those found with the rigid fusion systems. Indeed, our patients who were

instrumented with a two-level dynamic system (6 dynamic screws-2 rigid rods) had higher rates of screw fractures, screw loosening, pull-out and ASD compared to patients treated with the single-level system (4 dynamic screws, 2 rigid rods), and their rates were comparable to those of the fusion patients.

After the posterior column rigidity in the multilevel dynamic screw system, we also observed that screw loosening is more common in osteoporotic female patients, screw breakage is more common in younger patients, and these rates are similar to those of patients who underwent fusion with rigid stabilization systems. Although the results are not as striking as they are in the fusion patients, the figures are still significant for the dynamic system, which is challenging with fusion (4). These results are not encouraging enough to recommend dynamic instrumentation systems instead of fusion systems for 2-level or more levels lumbar stabilization.

We believe that the most significant recent development is the combined use of the dynamic rod and the dynamic screw to stabilize the spine without fusion, which also allows movement in the spine and prevents some possible fusion-related complications. Cadaver and finite element research,

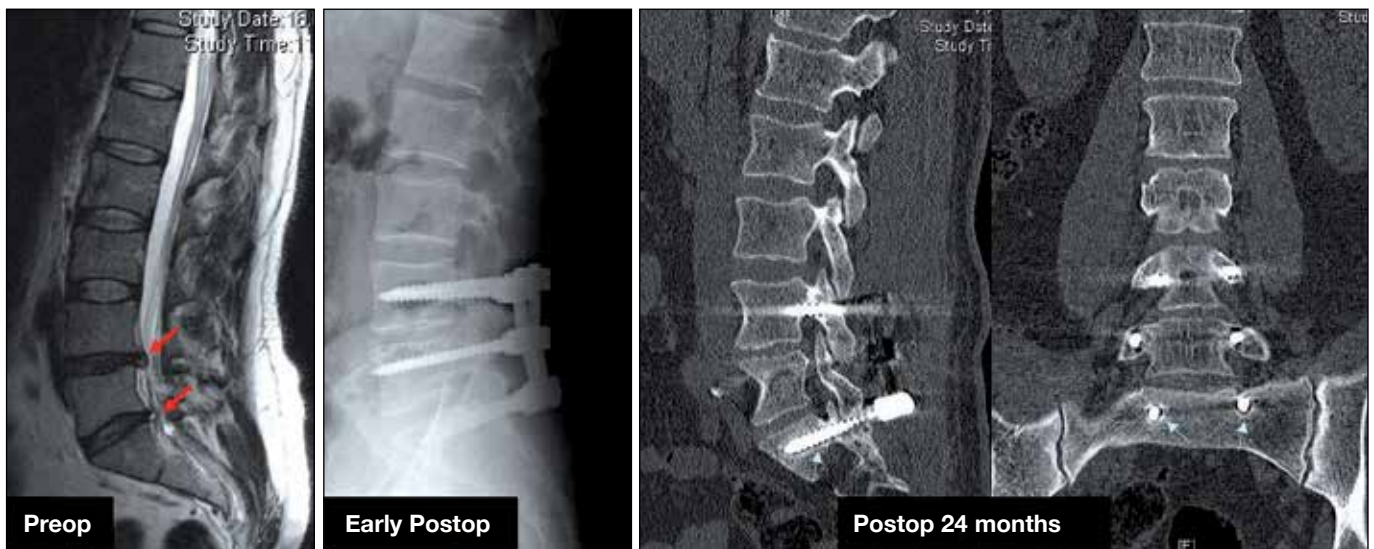

Figure 6: Dynamic screw loosening is observed at the 2-year postoperative follow-up.

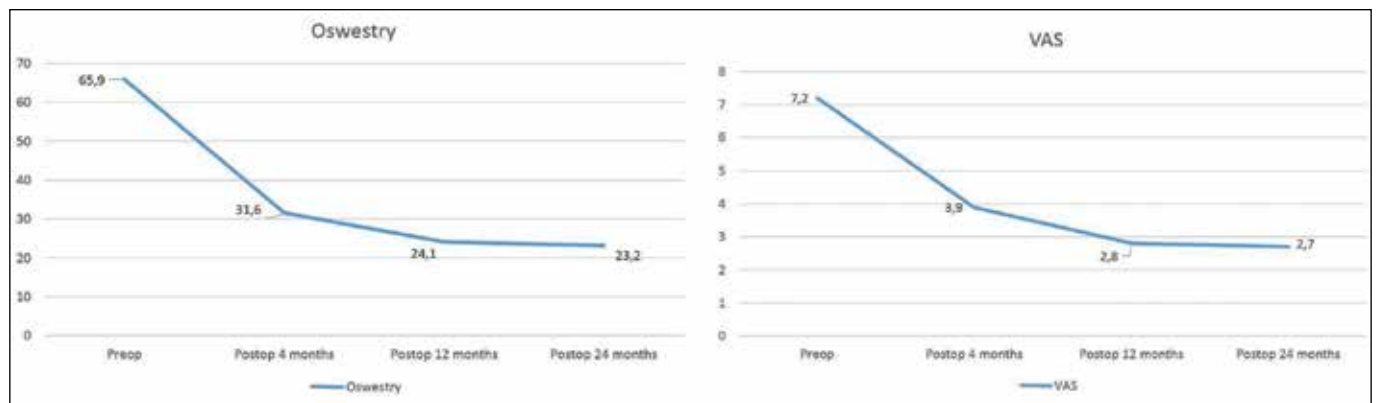


Figure 7: The results of VAS (right) and ODI (left) scores of the patients.

as well as biomechanical studies, have shown that this semi-rigid system could stabilize the segment and that the rigid systems and instability could be successfully corrected with this combined method (1-3,11). The combined use of dynamic rod and dynamic screw systems is available in the market and has long been used for patients in our clinic. The clinical outcomes have been satisfactory.

The aim is to ensure the long-term maintenance of the system without failure, such as hip and knee prostheses. The system differs from fusion; particularly if it is applied to patients with a healthy segment, it will be faced with life-time loading. The system loading interval in fusion is three months in healthy patients, while the fused segment is loaded later, causing the rigid segment to complete its life expectancy. Metal fatigue and consequent fractures are inevitable in dynamic systems exposed to life-time loading. Thus, either the metal strength should be improved, or the design should be modified. Another solution might be to use non-metal constructs or metal hybrid constructs. The long-term, two-year follow-up results will be useful in monitoring disc degeneration surveillance due to the prolonged exposure to the dynamic system loading, hardware failures and patient complications.

■ CONCLUSION

Our results showed that the complication rates (screw loosening or breakage and ASD) are low in fusion systems compared to the literature, but the stabilization system results were not acceptable when we used a 2-level dynamic stabilization system (6 dynamic screws and 2 rigid rods).

Briefly, our one-level stabilization results were satisfactory with the fusion systems, but the 2-level stabilization results were not. It is obvious that more studies should be conducted and that new technologies are needed, particularly for patients with multi-level instability.

■ REFERENCES

- Bozkus H, Senoglu M, Baek S, Sawa AG, Ozer AF, Sonntag VK, Crawford NR: Dynamic lumbar pedicle screw-rod stabilization: In vitro biomechanical comparison with standard rigid pedicle screw-rod stabilization. *J Neurosurg Spine* 12(2):183-189, 2010
- Chamoli U, Diwan AD, Tsafnat N: Pedicle screw-based posterior dynamic stabilizers for degenerative spine: In vitro biomechanical testing and clinical outcomes. *J Biomed Mater Res A* 102:3324-3340, 2014
- Erbulut DU, Zafarparandeh I, Ozer AF, Goel VK: Biomechanics of posterior dynamic stabilization systems. *Adv Orthop* 451956, 2013
- Galbusera F, Volkheimer D, Reitmaier S, Berger-Roscher N, Kienle A, Wilke HJ: Pedicle screw loosening: A clinically relevant complication? *Eur Spine J* 24:1005-1016, 2015
- Graf H: Lumbar instability: Surgical treatment without fusion. *Rachis* 412:123-137, 1992
- Harrop JS, Youssef JA, Maltenfort M, Vorwald P, Jabbour P, Bono CM, Goldfarb N, Vaccaro AR, Hilibrand AS: Lumbar adjacent segment degeneration and disease after arthrodesis and total disc arthroplasty. *Spine* 33:1701-1707, 2008
- Kim CH, Chung CK, Jahng TA: Comparisons of outcomes after single or multilevel dynamic stabilization: Effects on adjacent segment. *J Spinal Disord Tech* 24(1):60-67, 2011
- Lau S, Lam KS: Lumbar stabilisation techniques. *Current Orthopaedics* 21:25-39, 2007
- Mohi Eldin MM, Ali AM: Lumbar transpedicular implant failure: A clinical and surgical challenge and its radiological assessment. *Asian Spine J* 8(3):281-297, 2014
- Mulholland RC, Sengupta DK: Rationale, principles and experimental evaluation of the concept of soft stabilization. *Eur Spine J* 11:198-205, 2002
- Oktenoglu T, Erbulut DU, Kiapour A, Ozer AF, Lazoglu I, Kaner T, Sasani M, Goel VK: Pedicle screw-based posterior dynamic stabilisation of the lumbar spine: In vitro cadaver investigation and a finite element study. *Comput Methods Biomech Biomed Engin* 18 (11):1252-1261, 2015
- Park P, Garton HJ, Gala VC, Hoff JT, McGillicuddy JE: Adjacent segment disease after lumbar or lumbosacral fusion: Review of the literature. *Spine* 29:1938-1944, 2004
- Pihlajamäki H, Myllynen P, Böstman O: Complications of transpedicular lumbosacral fixation for non-traumatic disorders. *J Bone Joint Surg Br* 79:183-189, 1997
- Schaeren S, Broger I, Jeanneret B: Minimum four-year follow-up of spinal stenosis with degenerative spondylolisthesis treated with decompression and dynamic stabilization. *Spine* 33:636-642, 2008
- Schmoelz W, Huber JF, Nydegger T, Dipl-Ing, Claes L, Wilke HJ: Dynamic stabilization of the lumbar spine and its effects on adjacent segments: An in vitro experiment. *J Spinal Disord Tech* 16: 418-423, 2003
- Schmoelz W, Onder U, Martin A, von Stempel A: Nonfusion instrumentation of the lumbar spine with a hinged pedicle screw rod system: An in vitro experiment. *Eur Spine J* 18(10):1478-1485, 2009
- Seifen T, Rodrigues M, Rettenbacher L, Piotrowski W, Holzmannhofer J, Mc Coy M, Pirich C: The value of (18) F-fluoride PET/CT in the assessment of screw loosening in patients after intervertebral fusion stabilization. *Eur J Nucl Med Mol Imaging* 42:272-277, 2015
- Smith D, McMurray N, Disler P: Early intervention for acute back injury: Can we finally develop an evidence based approach? *Clin Rehabil* 16:1-11, 2002
- Stoll TM, Dubois G, Schwarzenbach O: The dynamic neutralization system for the spine: A multi-center study of a novel non-fusion system. *Eur Spine J* 11: 170-178, 2002
- Uschold TD, Fusco D, Germain R, Tumialan LM, Chang SW: Cervical and lumbar spinal arthroplasty: Clinical review. *AJNR Am J Neuroradiol* 33:1631-1641, 2012
- von Stempel A, Moosmann D, Stoss C, Martin A: Stabilization of the degenerated lumbar spine in the nonfusion technique with Cosmic posterior dynamic system. *WSJ* 1:40-47, 2006
- von Stempel A, Neckritz A, Mualenaere P, du Toit G: Dynamic versus rigid spinal implants. In: Gunzburg R, Szpalski M (eds), *Lumbar Spinal Stenosis*. Philadelphia: Lippincott-Williams and Wilkins, 2000: 275-285
- Wu JC, Huang WC, Tsai HW, Ko CC, Wu CL, Tu TH, Cheng H: Pedicle screw loosening in dynamic stabilization: Incidence, risk, and outcome in 126 patients. *Neurosurg Focus* 31:E9, 2011