

An Unusual Presentation of Head Injury: Teeth in Brain

Alışılmadık Bir Kafa Travması Sunumu: Beyin İçinde Diş

ABSTRACT

Penetrating injuries other than gunshot wounds or low-velocity wounds to the head are extremely rare. We report the case of a 19 year old male who sustained a penetrating craniocerebral trauma following a road traffic accident. Noncontrast CT scan revealed three foreign bodies embedded in left frontal lobe, which on surgery turned out to be human teeth. Mechanism of injury seems to share characteristics of low velocity projectiles. The survey of management pattern of these injuries showed a general agreement about CT scan, antibiotics and anticonvulsants. The prompt management resulted in an excellent outcome. We discuss the management of this unusual case reviewing the current literature on craniocerebral injuries caused by similar objects.

KEYWORDS: Intracranial foreign bodies, Penetrating head injury, Teeth

ÖZ

Kafanın silah yaralanmaları ve düşük hızlı yaralanmalar dışındaki penetran yaralanmaları nadirdir. Biz bir trafik kazası nedeniyle penetran bir kranyoserebral travmaya maruz kalan 19 yaşında bir erkek hastayı sunuyoruz. Kontrastsız BT sol frontal lob içinde üç tane yabancı cisim gösterdi ve ameliyatta bunların insan dişi olduğu anlaşıldı. Yaralanma mekanizması düşük hızlı bir cisim yaralanmasının özelliklerini taşıyor görünür. Bu yaralanmaların tedavi şemalarında BT, antibiyotik ve antikonvülzan kullanımıyla ilgili genel bir görüş birliği vardır. Doğru tedavi mükemmel bir sonuca ulaşılmasını sağlar. Benzer objeler tarafından oluşturulmuş kranyoserebral yaralanmalarla ilgili güncel literatür bilgileri eşliğinde bu alışılmadık vakanın tedavisini tartıştık.

ANAHTAR SÖZCÜKLER: Kafaiçi yabancı cisim, Penetran kafa travması

Deepak SINGH
Vishnu GUPTA
Rashim KATARIA
Sanjeev CHOPRA
Pankaj GUPTA
H. BAGARIA

SMS Medical College, Neurosurgery
Department, Jaipur, India

Received : 12.11.2008

Accepted : 13.03.2009

Correspondence address:

Deepak SINGH

E-mail: gkp.deepak@gmail.com

INTRODUCTION

Penetrating cerebral injuries caused by foreign bodies are rare occurrences and still rarer are cases involving multiple foreign bodies after vehicular accidents. There are various reports of multiple foreign bodies like pellets and nails due to blast or gunshot injuries (5,8). We are presenting a very unusual case of penetrating head injury in which teeth were embedded in cerebral parenchyma

CASE REPORT

A 19-year-old male presented as a case of head injury after a motorcycle accident. On taking history it was found that patient was driving a motorcycle and a head-on collision occurred with another motorcycle. Both drivers were without a helmet. At the time of admission, the patient was fully conscious and there was no neurological deficit. Local examination revealed a lacerated wound on the left frontal region with underlying depressed fracture. A noncontrast CT scan head showed left frontal depressed fracture with three hyperdense globular structures in a row; in the left frontal region just below the fracture segment (Figure 1). The patient was operated immediately. The depressed fracture segments were elevated and removed. A dural tear was present with brain matter coming out from it. Dural edges were defined, and three foreign bodies, which turned out to be human teeth, removed one by one through the dural opening (Figure 2). The wound was thoroughly washed with normal saline. Watertight dural closure was achieved using a pericranial patch. The postoperative course was uneventful with CT-scan showing complete removal of all foreign bodies (Figure 3). The patient was discharged on the seventh postoperative day on anticonvulsants without any neurological sequelae.

DISCUSSION

Penetrating injuries of the brain are very common in warfare injuries but are rarer in civilian head injuries. Missile injuries account for the majority of penetrating wounds of the brain (5) although the brain has been penetrated by almost every conceivable object. There are reports in literature ranging from a knife (2) to blades, spoons and even nails (8). The major determinant of injury is the behavior of the penetrating object within the tissue which in turn depends on deformation, yaw

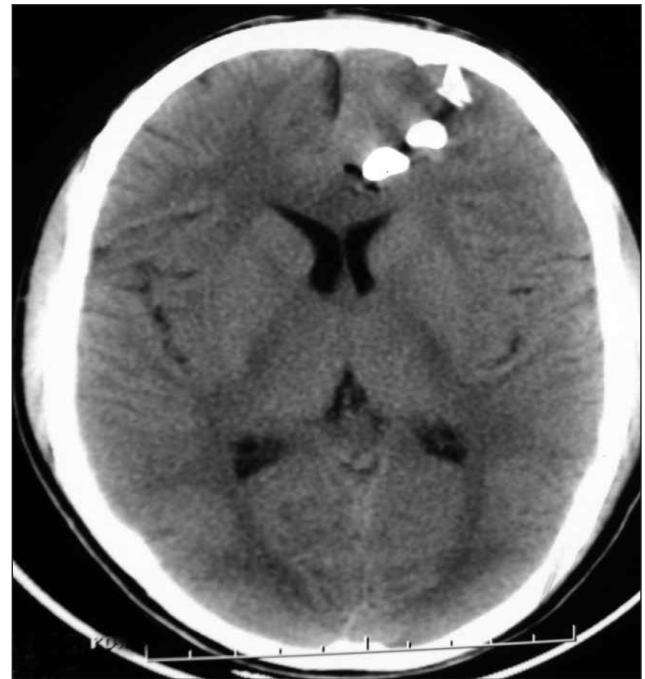

Figure 1: Preoperative CT Head showing three globular hyperdense objects in left frontal region.

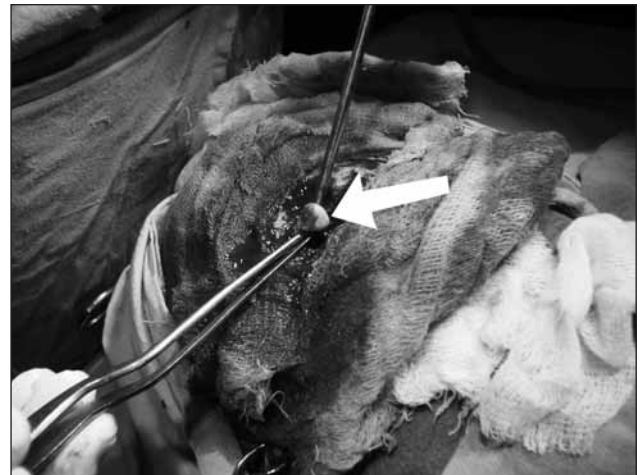

Figure 2: Peroperative photograph showing removal of foreign bodies (Marked with white arrow).

(rotation about the long axis) and fragmentation of the projectile. The velocity of the penetrating object has been emphasized in previous studies and differentiates wounds into "low velocity" and "high velocity". However, velocity is not an independent primary determinant of wounding potential (3).

The three most common types of low velocity penetrating head injuries are industrial accidents, suicide attempts and results of criminal assault (1). In

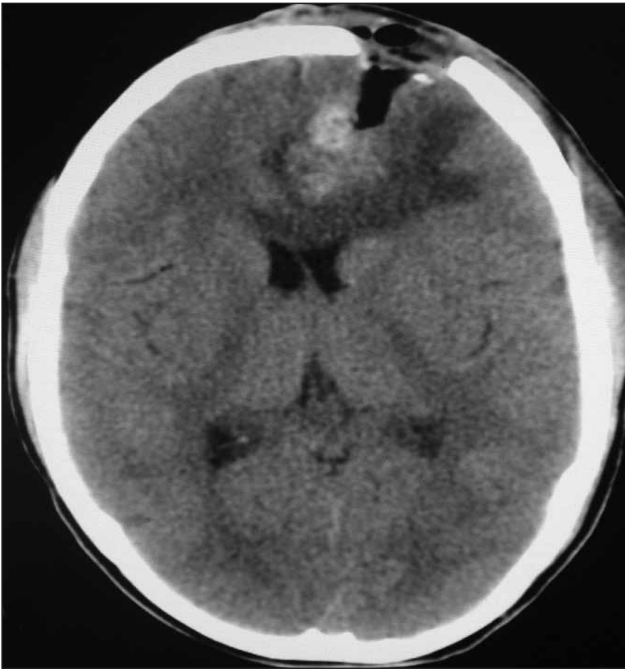


Figure 3: Postoperative CT scan showing complete removal of foreign objects.

our case, the high impact head-on collision of the patient's head with the other biker resulted in penetration of the offenders teeth into the patient's brain parenchyma.

Prompt and meticulous management is called for in these cases. Immediate radiological examination is mandatory because the small entrance wound does not correspond with the size of foreign body and associated intracranial injury. X-ray skull is useful to delineate the depth and direction of penetration (4). CT scan head is mandatory in all cases to know the extent of intracranial injuries and is essential in decision-making regarding surgical intervention (7). However CT scan may need a change of window levels to decrease the metal artifacts. Cerebral angiography may be indicated if injury to a major vessel or venous sinuses is anticipated, or in cases of delayed SAH and intracranial hemorrhage. A decision regarding the

endovascular or surgical treatment can be made with adequate exposure of vessels in the area of injury. Transcranial wounds should be explored surgically and penetrating foreign body should be removed. In our case the teeth were gently removed along with the depressed wound segments. One has to be very careful not to produce further damage to the underlying brain by movement of the foreign body and surrounding bone (1).

These injuries vary in severity from trivial to life threatening but the usual complications are infection and vascular. Penetrating wounds passing through paranasal sinuses or oropharyngeal mucosa before entering the cranium have an increased chance of wound infection.

The survey of management pattern of these injuries showed a general agreement about CT scan, antibiotics and anticonvulsants (6). The prompt management resulted in an excellent outcome. There is a need for continued research in this area.

REFERENCES

1. Bakay L, Glausier FE, Grand W: Unusual intracranial foreign bodies. Report of five cases. *Acta Neurochir(Wien)* 39: 219-231, 1977
2. Davis NL, Kahana T, Hiss J: Souvenir knife: A retained transcranial knife blade. *Am J Forensic Med Pathol* 25: 259-261, 2004
3. Fackler ML: Wound ballistics. A review of common misconceptions. *JAMA* 259: 2730-2736, 1988
4. Herring CJ, Lumsden AB, Tindall C: Transcranial stab wounds. A report of three cases and suggestions for management. *Neurosurgery* 23: 658-662, 1988
5. Kaufman HH: Treatment of civilian gunshot wounds to the head. *Neurosurg Clin North Am* 2:387-339, 1991
6. Kaufman HH, Schwab K., Salazar AM: A national survey of Neurosurgical care for penetrating head injury. *Surgical Neurology* 36: 370-77, 1991
7. Nakayama Y, Tanaka A, Arita T, Kumate S, Yoshinga S: Penetrating head injury caused by weed: Case report. *Brain & Nerve* 47:1192-1194, 1995
8. Salar G, Costella GB, Mottaran R, Mattana M, Gazzola L, Munari M: Multiple craniocerebral injuries from penetrating nails. *J Neurosurg* 100: 963, 2004