Received: 03.12.2010 / **Accepted:** 07.01.2011
DOI: 10.5137/1019-5149.JTN.3985-10.1

Case Report

Epidermoid Cyst Inside Anterior Sacral Meningocele in an Adult Patient of Currarino Syndrome Manifesting with Meningitis

Currarino Sendromlu Yetişkin Bir Hastada Menenjit Olarak Ortaya Çıkan, Anterior Sakral Meningosel İçinde Epidermoid Kist

Ritesh KANSAL, Amit MAHORE, Nitin DANGE, Sanjay KUKREJA

Seth G.S. Medical College at K.E.M. Hospital, Department of Neurosurgery, Parel, Mumbai, Indian

Correspondence address: Ritesh KANSAL / E-mail: drkansal@yahoo.co.in

ABSTRACT

The Currarino triad, also known as the "Currarino Syndrome", is a rare complex of congenital caudal anomalies including three main features; a sacral bony deformity, anorectal malformations, and a presacral mass. We present an extremely uncommon case of Currarino syndrome in adulthood presenting with repeated episodes of meningitis. Magnetic resonance imaging of spine was suggestive of caudal regression. Cord was low lying, conus ending at L3 level with evidence of tethering at that level. A large cyst was noted in the sacral canal extending forwards in the pelvis through the widened sacral foramina on right side. She was operated through a posterior approach, via sacral laminectomy. Dura was opened in the midline, large silvery white epidermoid tumor was found completely occupying the anterior sacral meningocele. The case and relevant literature is discussed.

KEYWORDS: Anterior sacral meningocele, Currarino syndrome, Epidermoid cyst, Meningitis

ÖZ

"Currarino Sendromu" olarak da bilinen Currarino triadı üç ana bulgudan oluşan nadir bir konjenital kaudal anomali kompleksidir: sakral kemik deformitesi, anorektal malformasyonlar ve presakral kitle. Erişkin bir hastada tekrarlanan menenjit episotlarıyla ortaya çıkan çok nadir bir Currarino sendromu vakası sunuyoruz. Omuriliğin manyetik rezonans görüntülemesi kaudal regresyon düşündürdü. Kord düşük seviyedeydi ve konus L3 seviyesinde sonlanıp o seviyede tutunma bulguları gösteriyordu. Sakral kanalda sağ tarafta genişlemiş sakral foramenler içinden pelvise ileri doğru uzanan büyük bir kist görüldü. Hastaya posterior yaklaşımla sakral laminektomi yoluyla ameliyat yapıldı. Dura orta hatta açıldı ve anterior sakral meningoseli tamamen dolduran büyük bir gümüş beyazı epidermoid tümör bulundu. Vaka ve ilgili literatür tartışılmaktadır.

ANAHTAR SÖZCÜKLER: Anterior sakral meningosel, Currarino sendromu, Epidermoid kist, Menenjit

INTRODUCTION

The Currarino triad is a rare condition consisting of sacral bony deformity, anorectal malformation and presacral mass. Anterior sacral meningocele and teratomas are common presacral masses. We present a rare case of Currarino syndrome with an anterior sacral meningocele containing an intradural epidermoid. She presented with repeated bouts of meningitis.

CASE REPORT

A 45 year old lady presented to our outpatient department with complaints of fever headache and vomiting since three days. She also had low backache since two years. On further enquiry she described similar episodes twice in past which were managed by a local physician. On neurological examination there was neck stiffness with positive Brudzinski sign. There was no weakness in lower limbs. She was a diagnosed case of anal stenosis since birth managed by anal dilatation. Cerebrospinal fluid analysis was done which showed leucocytosis with 86% neutrophils. No organism could be identified in culture. Magnetic resonance imaging (MRI) of spine revealed a partial sacral agenesis with dysplastic lower lumbar and sacral segments below L3 level suggesting caudal regression. Small dysplastic sacrum was fused to the lower lumbar segments. Cord was low lying, conus ending at L3 level with evidence of tethering at that level. A large cyst was noted in the sacral canal extending forwards in the pelvis through the widened sacral foramina on right side (Figures 1, 2). The findings were suggestive of anterior sacral meningocele. Terminal syringohydromyelia was noted extending till D12 vertebral body level (Figure 3).

She was operated through a posterior approach, via sacral laminectomy. Dura was opened in the midline, large silvery white epidermoid tumor was found completely occupying the dural sac. The tumor was found to contain thick greenish yellow fluid. Tumor was adherent to the neural tissues from

which it was gradually dissected. The tumor was found to be entering the pelvis anteriorly from a defect in the sacrum towards the right side which was removed gradually. The anterolateral dural defect was closed by direct suturing of the dura at the neck of the herniation. Post operatively patient was fine with no added neurological deficit.

DISCUSSION

Spinal meningocele is an obvious posterior protrusion of meningeal elements out of the spinal canal, which is commonly seen in lumbosacral area. Lateral or anterior spinal meningoceles are known although uncommon. Anterior sacral meningocele is defined as a meningeal cyst that occurs in the presacral space into the retroperitoneal and infraperitoneal space due to agenesis of a portion of the anterior sacrum. It is unilocular or multilocular protrusion of the dura and arachnoid out of the sacral spinal canal. This protrusion may occur anteriorly through the body of the sacrum or anterolaterally through an enlarged intervertebral foramen or coalesced foramina as in our case.

Figure 1: T2 W Magnetic resonance imaging image of lumbosacral spine showing partial sacral agenesis with dysplastic lower lumbar and sacral segments below L3 level. Small dysplastic sacrum is fused to the lower lumbar segments. Conus ending at L3 level with evidence of tethering. A large cyst was noted in the sacral canal.

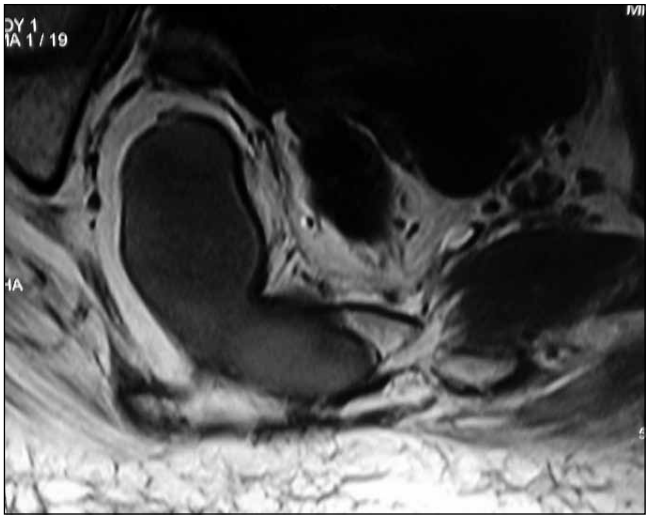

Figure 2 : T1 W MRI axial cut of sacral spine showing a cystic cavity in sacrum extending forwards in the pelvis through the widened sacral foramina on right side.

The anterior defect in the vertebral column may be a result of disordered embryogenesis. Such faulty development also can result in coexisting abnormalities in the skin, subcutaneous tissues, spine, and internal organs. In approximately 50% of cases, associated malformations are found, such as spina bifida, spinal dysraphism, bicornuate uterus, and imperforate anus.

Anterior sacral meningocele occurs sporadically, but familial cases have been reported as part of the Currarino syndrome. The Currarino triad, also known as the "Currarino Syndrome", is a rare complex of congenital caudal anomalies including three main features; a sacral bony deformity, anorectal malformations, and a presacral mass (1). All the three features were present in our case. Enteric cysts, dermoid cysts, lipomas, leiomyosarcomas, yolk sac tumors, pelvic hamartomas and carcinoid tumors have all been described as pre-sacral masses. However, the most frequent pathologies described are anterior sacral meningoceles and teratomas. It may be uncommonly associated with epidermoid cysts.

Meningitis is a serious complication of Currarino syndrome with high mortality. This complication may be iatrogenic or due to fistulous connection of spinal canal with anus

Figure 3: T2 W MRI axial cut of lumbar spine at L1 level showing terminal syringohydromyelia.

or rectum. Sometimes these cases of meningitis may be idiopathic, rare cases of meningitis with epidermoid cysts containing purulent fluid have been described (2,3). Tiny tear in the wall of these epidermoid cyst have been hypothesized as a cause of meningitis in these cases. There may be similar cause in our patient.

Management of Currarino syndrome generally consists of treatment of anorectal malformations first and followed by anterior sacral meningocele. An anterior sacral meningocele may be approached surgically either through the posterior sagittal approach with complete exposure of perineum attained by an incision from the sacrum to the anus. In our case a transdural route was taken from a sacral laminectomy. This route allowed for excision of the intradural epidermoid in our case. The redundant sac extending in the retroperitoneum is known to be adherent to the posterior wall of rectum and may be left behind after closure of the meningocele pedicle.

REFERENCES

1. Currarino G, Coln D, Votteler T: Triad of anorectal, sacral and presacral anomalies. Am J Roentgenol 137:395-398, 1981
2. Haga Y, Cho H, Shinoda S, Masuzawa T: Recurrent meningitis associated with complete Currarino triad in an adult – case report. Neurol Med Chir (Tokyo) 43:505-508, 2003
3. Shamoto H, Yoshida Y, Shirane R, Yoshimoto T: Anterior sacral meningocele completely occupied by an epidermoid tumor. Childs Nerv Syst 15:209-211, 1999