

Frequency and Type of Ponticulus Posticus and Lateralis in a Chinese Population: A CT-Based Analysis of 4047 Cases

Jun ZHANG^{1,2,*}, Jianjian SHEN^{3,*}, Yong LI^{4,*}, Jiayin ZHENG⁵, Yixin WANG⁵, Haiyu SHAO^{1,2}, Mengran JIN^{1,2}, Zhongxiang DING^{1,2}, Tingxiao ZHAO^{1,2}, Xinji CHEN^{1,2}, Yazeng HUANG^{1,2,*}

¹Zhejiang Provincial People's Hospital, Department of Orthopedics, Hangzhou, Zhejiang, China

²People's Hospital of Hangzhou Medical College, Hangzhou, Zhejiang, China

³Cixi People's Hospital, Department of Orthopedics, Ningbo, Zhejiang, China

⁴Qingtian People's Hospital, Department of Orthopedics, Lishui, Zhejiang, China

⁵Fred Hutchinson Cancer Research Center, Seattle, WA, USA

*These authors contribute equally to this study.

Corresponding author: Yazeng HUANG ✉ huangyazeng2007@163.com

ABSTRACT

AIM: To investigate the prevalence and type of ponticulus posticus (PP) and ponticulus lateralis (PL) in the Chinese population by analyzing computed tomography (CT) scans, and to uncover the pathogenesis of PP and PL.

MATERIAL and METHODS: A total of 4,047 cases were included in this study. We evaluated cervical spine CT scans with three dimensional reconstructions and collected age, gender, and presence of PP and PL in each case. If either or both were present, location and type were recorded.

RESULTS: The overall prevalence of PP was 8.01%. The age of patients with PP was significantly higher than those without. Men had a higher prevalence of PP than women. The presence of PP was more common on the left side than the right. According to our previous classification, the most common type of a PP was AC (32.41%), followed by CC (20.06%) and CA (16.98%). The overall prevalence of PL was 4.67%, with no differences between age groups, genders or by location. The most common type of PL was AC (43.92%), followed by CA (35.98%) and CC (20.11%). The prevalence of PP and PL occurring in the same patient was 1.26%.

CONCLUSION: Based on cervical spine CT scans of 4,047 Chinese patients, we found that the prevalence of PP and PL were 8.01% and 4.67%, respectively. PP was more common in older patients, which strongly suggests that PP may be a congenital osseous anomaly of the atlas that mineralizes during aging.

KEYWORDS: Ponticulus posticus, Ponticulus lateralis, Cervical spine, Atlas, Vertebral artery injury

ABBREVIATIONS: PP: Ponticulus posticus, PL: Ponticulus lateralis, CT: Computed tomography scan.


INTRODUCTION

Ponticulus posticus (PP) and ponticulus lateralis (PL) are two well-known variations of the atlas that were first identified by Schmidt in 1959 (17). PP forms a bony bridge between the posterior end of the superior articular

condyle and the posterior arch, which together form the groove through which the final part of the vertebral artery passes. PL is a bony bridge between the posterolateral margin of the same condyle and the transverse process, which form the groove for the first parts of the vertebral artery.

Jun ZHANG  : 0000-0001-5193-9155
Jianjian SHEN  : 0000-0002-9293-8973
Yong LI  : 0000-0002-8715-8200
Jiayin ZHENG  : 0000-0002-5559-6847

Yixin WANG  : 0000-0002-2981-4222
Haiyu SHAO  : 0000-0002-4769-5773
Mengran JIN  : 0000-0003-1195-6318
Zhongxiang DING  : 0000-0001-7691-5571

Tingxiao ZHAO  : 0000-0003-0154-3595
Xinji CHEN  : 0000-0003-2950-0597
Yazeng HUANG  : 0000-0002-2955-1848

PP is regarded as a not uncommon anatomic variant, and is of clinical relevance in the development of unexplainable neck pain, vertigo, and headaches (1,24). It is also associated with cleft lip and palate, dental agenesis, Gorlin-Goltz syndrome and bow hunter's syndrome (6,13). Severe headache occurs in 50–90% of individuals with PP (21,23). PP can easily be mistaken for a thickened posterior arch and may subsequently be used as an entry point for lateral mass atlas screw, causing vertebral artery injury (18,19,25). Proper identification of this osseous anomaly is crucial in avoiding vertebral artery injuries during atlas instrumentation.

The reported prevalence of PP and PL varies from 1.3–68% and 1.1–19%, respectively (3,4,9,12,20). Moreover, the incidence of PP and PL occurring simultaneously was reported to range from 0.4–2% (7,10-12,15). There is still no consensus regarding the predilection of PP and PL for gender (male versus female), location (left versus right), or ethnic and racial populations (4,9,20,22).

Thus, the objective of the present study was to investigate the prevalence of PP and PL in the Chinese population by analyzing CT scans of a large sample size. This study also aimed to ascertain the pathogenesis of PP and PL by evaluating abnormalities of CT scan data.

■ MATERIAL and METHODS

A retrospective analysis was conducted using all cervical spine CT scans with 3D reconstruction (including axial, coronal, and sagittal) performed at Zhejiang Provincial People's Hospital between January 1, 2015 and December 31, 2017. If more than one CT scan was identified for the same patient, only one CT scan was analyzed. All images were reviewed using the institution's picture archiving and communication system server (PACS). Each radiograph was independently inspected for the presence of PP and PL by two experienced spine surgeons. In case of disagreement between the two investigators, a third investigator was involved in the decision-making process. Final decision was reached by mutual consensus. Demographic data for each patient, including age and gender, were also recorded. The study was approved by the institutional review board of Zhejiang Provincial People's

Hospital and all procedures were performed in accordance with the Helsinki Declaration.

When PP was identified, it was recorded according to our previous classification system (14). A, B, and C represent absence of, partial, and complete PP, respectively (Figure 1A-C). For PL, A represents absence of PL and C represents identification of PL (partial or complete) (Figure 2A, B). The classification system uses a two-letter designation for both PP and PL, in which the first letter designation describes the right-side arch and the second letter designation describes the left-side arch. We defined simultaneous presence of PP and PL when both were present in either side or both sides of the same patient (Figure 3A, B).

Descriptive statistics were calculated for the demographic and clinical characteristics. Comparisons were performed using chi-square tests for categorical variables and t tests for continuous variables. Logistic regression was performed to identify demographic factors (age, gender) associated with PP or PL. All analyses were performed using SAS software, version 9.4 (SAS Institute, Cary, NC), and a p-value <0.05 was considered statistically significant.

■ RESULTS

A total of 4,047 unique patients with complete cervical spine CT scans were reviewed and included in this present study, after exclusion of duplicate and incomplete scans. The age of the cohort was 46.0 ± 17.6 years old (range, 3–96) (Table I). Females and males comprised 44.5% and 55.5% of the study population, respectively.

The overall prevalence of PP was 8.01%. The age of patients with PP was significantly higher than those without (47.87 ± 17.47 versus 45.88 ± 17.58 , $p=0.0498$). Men had a higher prevalence of PP than women (males, 66.05% versus females, 33.95%; $p<0.0001$) (Table I). PP was more commonly present in the left side than the right (76.54% versus 53.40%, $p<0.0001$) (Table II). According to our previous classification, the most common type of PP was AC (32.41), followed by CC (20.06%) and CA (16.98%) (Table III).

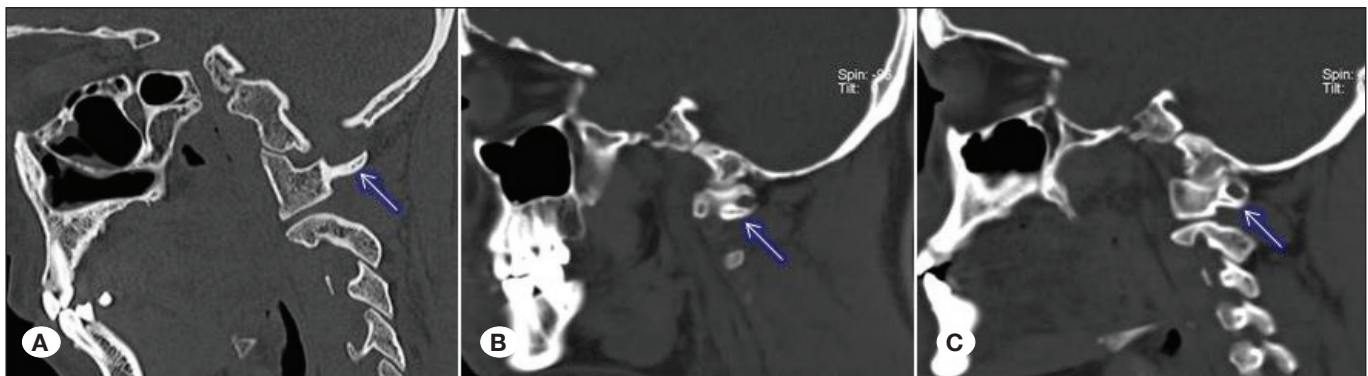


Figure 1: Examples of Ponticulus Posticus. **A)** Absence of a ponticulus posticus. **B)** Partial or incomplete bony arch (at least with approximately 50% of the arch present). **C)** Complete bony arch.

The overall prevalence of PL was 4.67%, with no differences between age groups, genders, or location (Tables I, II). The most common type of PL was AC (43.92%), followed by CA (35.98%) and CC (20.11%) (Table III). The prevalence of PP and PL in the same patient was 1.26%.

DISCUSSION

To the best of our knowledge, this is the first and largest study to assess the prevalence of PP and PL in a Chinese population using CT scans. We found a prevalence of 8.01% for PP, 4.67% for PL, and 1.26% for PP and PL occurring simultaneously. The results of our study are comparable to those reported in the literature.

The present study found that, in a large Chinese population, PP and PL were not common. However drives more clinical attentions due to its clinical relevance with some symptoms and insertion of C1 pedicle screws. As C1 instrumentation

becomes more common, a better understanding of atlas anatomy is essential for avoiding vertebral artery injuries. Previous studies have demonstrated that there is significant difference between different ethnic and racial groups. Due to the large size of the Chinese population and its high proportion of the global population (4,8,20), it is important to understand the prevalence of PP and PL in China.

We found that men had a higher prevalence of PP than women and that PP was more common in the left side than the right, which has also been previously reported in other populations (2,14). PL was also found to be less frequent with no demographic predilections. The age of patients with PP was significantly higher than that of patients without PP, which strongly suggests that PP may be a congenital osseous anomaly of the atlas that mineralizes during aging. Similar trends have been reported previously (5,16). The exact pathogenesis of PP and PL should be further investigated.

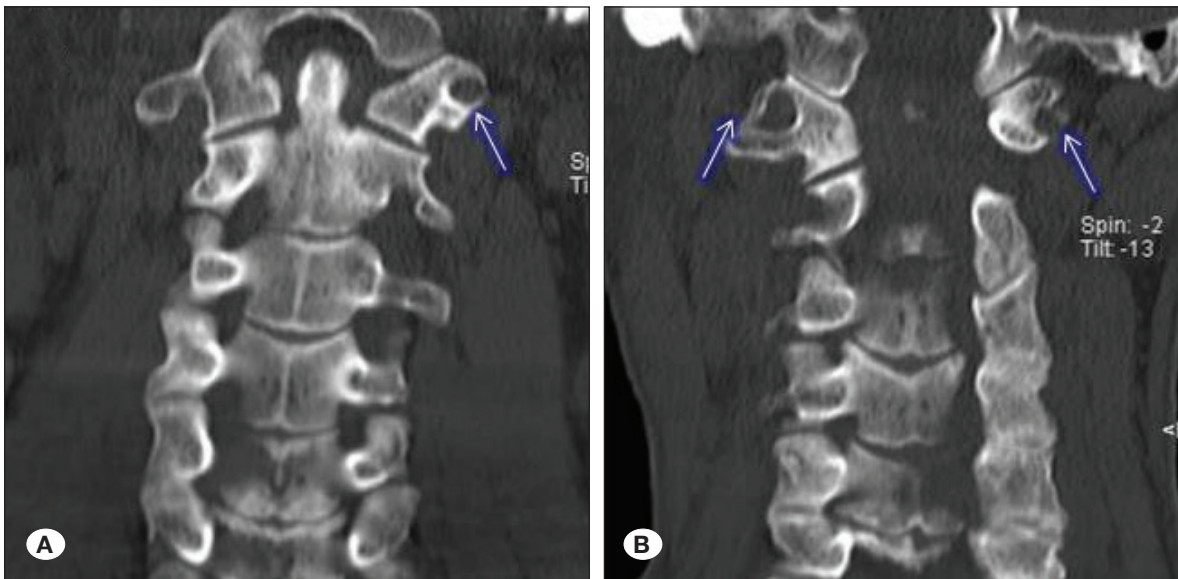


Figure 2: Examples of Ponticulus Lateralis. **A)** Presence of ponticulus lateralis on the left side only. **B)** Presence of ponticulus lateralis on the both side.

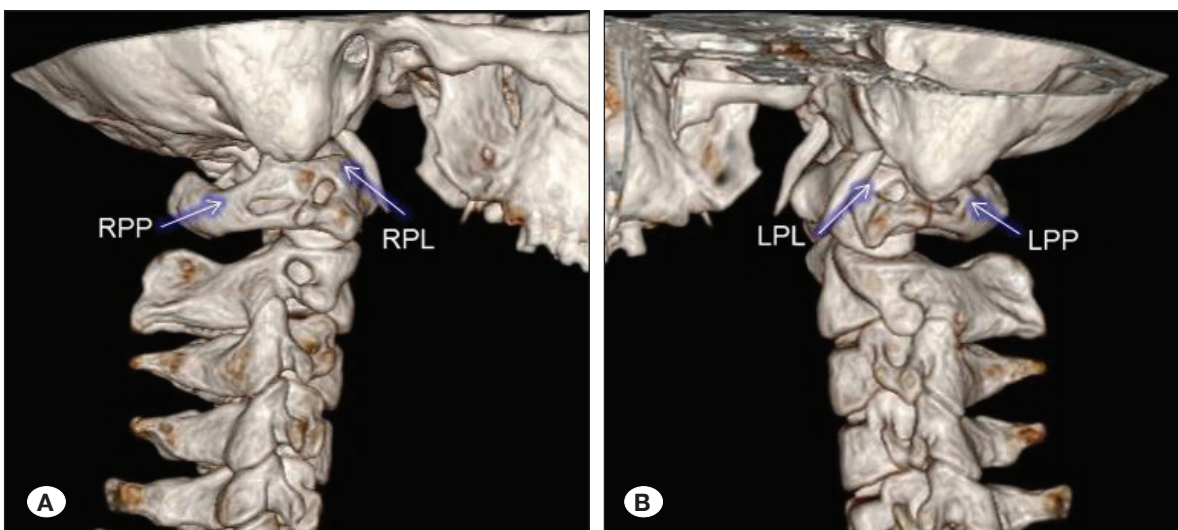


Figure 3: Examples of Ponticulus Posticus and Lateralis. **A)** Presence of ponticulus posticus (RPP) and lateralis (RPL) on the right side. **B)** Presence of ponticulus posticus (LPP) and lateralis (LPL) on the left side.

Table I: Demographic Data of Patients w/o Ponticulus Posticus (PP) and Ponticulus Lateralis (PL)

	All Patients n=4047	Non-PP Cohort n=3723	PP Cohort n=324	p	Non-PL Cohort n=3858	PL Cohort n=189	p
	Mean (Range) [Standard Deviation]	Mean (Range) [Standard Deviation]	Mean (Range) [Standard Deviation]		Mean (Range) [Standard Deviation]	Mean (Range) [Standard Deviation]	
Age	46.0 (3-96) [17.6]	45.88 (3-96) [17.58]	47.87 (8-94) [14.47]	0.0498	46.79 (9-87) [16.46]	46.00 (3-96) [17.63]	0.547
0-9	54	53	1		53	1	
10-19	229	214	15		222	7	
20-29	555	505	50		527	28	
30-39	635	599	36		608	27	
40-49	733	669	64		690	43	
50-59	875	807	68		839	36	
60-69	613	559	54		584	29	
70-79	245	221	24		230	15	
80-89	101	91	10		98	3	
90-99	7	5	2		7	0	
Gender				<0.0001			0.1314
Male	2247 (55.52%)	2033 (54.61%)	214 (66.05%)		2132 (55.26%)	115 (60.85%)	
Female	1800 (44.48%)	1690 (45.39%)	110 (33.95%)		1726 (44.76%)	74 (39.15%)	

Table II: Laterality of Ponticulus Posticus (PP) and Ponticulus Lateralis (PL)

PP	Right	Left	p
Complete Arch (C)	128 (39.51%)	178 (54.94%)	<0.0001
Partial Arch (B)	45 (13.89%)	70 (21.6%)	0.0102
Both Type (B and C)	173 (53.4%)	248 (76.54%)	<0.0001
PP	Right	Left	p
Complete Arch (C)	83 (43.92%)	68 (35.98%)	0.1152

Our study has some limitations. Firstly, this study was performed retrospectively in one hospital in the southeast of China, which may not fully represent the overall Chinese population. Secondly, we did not exclude patients with neck pain or other symptoms associated with PP or PL, which could theoretically elevate the prevalence rates. In addition, we did not record patients' BMI data, smoking or alcohol assumption, and other demographic characteristics that could be helpful for understanding the pathogenesis of PP and PL. Finally, our findings were limited to data of a Chinese population, and thus our results should not be considered as universal for other ethnic and racial populations.

CONCLUSION

In conclusion, PP and PL are important anatomical variations with great clinical relevance. With PP can easily be mistaken for the entry point of an atlas screw. To avoid vertebral artery injuries, careful review of CT scans with 3D reconstruction to identify the prevalence of PP and PL is required before atlas instrumentation.

Table III: Ponticulus Posticus (PP) and Ponticulus Lateralis (PL) by Classification

Ponticulus Posticus Classification	Number of patients (% of Overall Population / % of Patients with PP)
AA	3723 (91.99%)
AB	46 (1.14% / 14.2%)
AC	105 (2.59% / 32.41%)
BA	21 (0.52% / 6.48%)
BB	16 (0.4% / 4.94%)
BC	8 (0.2% / 2.47%)
CA	55 (1.36% / 16.98%)
CB	8 (0.2% / 2.47%)
CC	65 (1.61% / 20.06%)
Ponticulus Lateralis Classification	Number of patients (% of Overall Population / % of Patients with PL)
AA	3858 (95.33%)
AC	83 (2.05% / 43.92%)
CA	68 (1.68% / 35.98%)
CC	38 (0.94% / 20.11%)

REFERENCES

- Cakmak O, Gurdal E, Ekinci G, Yildiz E, Cavdar S: Arcuate foramen and its clinical significance. *Saudi Med J* 26:1409-1413, 2005
- Geist JR, Geist SM, Lin LM: A cone beam CT investigation of ponticulus posticus and lateralis in children and adolescents. *Dentomaxillofac Radiol* 43(5):20130451, 2014
- Gibelli D, Cappella A, Cerutti E, Spagnoli L, Dolci C, Sforza C: Prevalence of ponticulus posticus in a Northern Italian orthodontic population: A lateral cephalometric study. *Surg Radiol Anat* 38:e335-e343, 2016
- Karau PB, Ogengo JA, Hassanali J, Odula P: Anatomy and prevalence of atlas vertebrae bridges in a Kenyan population: An osteological study. *Clin Anat* 23:649-653, 2010
- Kendrick GS, Biggs NL: Incidence of the ponticulus posticus of the first cervical vertebra between ages six to seventeen. *Anat Rec* 145:449-453, 1963
- Lukianchikov V, Lvov I, Grin A, Kordonskiy A, Polunina N, Krylov V: Minimally invasive surgical treatment for vertebral compression in a patient with one-sided ponticulus posticus and ponticulus lateralis. *World Neurosurg* 117:97-102, 2018
- Macalister A: Notes on the development and variants of the atlas. *J Anat Physiol* 27:519-542, 1893
- Mitchell J: The incidence and dimensions of the retroarticular canal of the atlas vertebra. *Acta Anat (Basel)* 163:113-120, 1998
- Mitchell J: The incidence of the lateral bridge of the atlas vertebra. *J Anat* 193:283-285, 1998
- Muraki T: On the morphological varieties of the Kanto-Japanese atlantes. *Rep Dept Anat Jikei Univ School Med* 25:1-7, 1964
- Poirier P: *Trait D'anatomie Humaine*. Paris: Masson, 1899
- Prescher A: The craniocervical junction in man, the osseous variations, their significance and differential diagnosis. *Ann Anat* 179:1-19, 1997
- Putrino A, Leonardi RM, Barbato E, Galluccio G: The association between Ponticulus posticus and dental agenesis: A retrospective study. *Open Dent J* 12:510-519, 2018
- Saleh A, Gruber J, Bakhsh W, Rubery PT, Mesfin A: How common is the ponticulus posticus? A computed tomography based analysis of 2917 patients. *Spine (Phila Pa 1976)* 43(8):e436-e441, 2018
- Sato E, Notiyasu S: Studies on the Ponticulus posterior and Ponticulus lateralis of the human first cervical vertebra. *Sapporo Med J* 47:599-617, 1978
- Schilling J, Schilling A, Goldames IS: Ponticulus posticus on the posterior arch of the atlas, prevalence analysis in asymptomatic patients. *Int J Morphol* 28:317-322, 2010
- Schmidt H: Okzipitale Dysplasien. *Fortschr Röntgenstr* 90:691-704, 1959
- Senoglu M, Gumusalan Y, Yuksel KZ, Uzel M, Celik M, Ozbag D: The effect of posterior bridging of C1 on craniovertebral junction surgery. *J Neurosurg Spine* 5:50-52, 2006
- Simsek S, Yigitkanli K, Comert A, Acar HI, Seckin H, Er U, Belen D, Tekdemir I, Elhan A: Posterior osseous bridging of C1. *J Clin Neurosci* 15:686-688, 2008
- Taitz C, Nathan H: Some observations on the posterior and lateral bridge of the atlas. *Acta Anat (Basel)* 127:212-217, 1986
- Tambawala SS, Karjodkar FR, Sansare K, Motghare D, Mishra I, Gaikwad S, Dora AC: Prevalence of ponticulus posticus on lateral cephalometric radiographs, its association with cervicogenic headache and a review of literature. *World Neurosurg* 103:566-575, 2017
- Tubbs RS, Johnson PC, Shoja MM, Loukas M, Oakes WJ: Foramen arcuale: Anatomical study and review of the literature. *J Neurosurg Spine* 6:31-34, 2007
- Wakao N, Takeuchi M, Nishimura M, Riew KD, Kamiya M, Hirasawa A, Kawanami K, Imagama S, Sato K, Takayasu M: Vertebral artery variations and osseous anomaly at the C1-2 level diagnosed by 3D CT angiography in normal subjects. *Neuroradiology* 56:843-849, 2014
- Wight S, Osborne N, Breen AC: Incidence of ponticulus posterior of the atlas in migraine and cervicogenic headache. *J Manipulative Physiol Ther* 22:15-20, 1999
- Young JP, Young PH, Ackermann MJ, Anderson PA, Riew KD: The ponticulus posticus: Implications for screw insertion into the first cervical lateral mass. *J Bone Joint Surg Am* 87(11):2495-2498, 2005