



Clinical Analysis of the Effects of Frontal Bone Reconstruction and Cranial Suture Reconstruction in the Operation of Simple Premature Closure of Frontal Suture in Infants

Qi QIN, Han WU, Zhen Tao LI, Meng Zhao FENG

The Third Affiliated Hospital of Zhengzhou University, Department of Neurosurgery, Zhengzhou City, China

Corresponding author: Feng MENGZHAO ✉ mengzhaofeng0371@163.com

ABSTRACT

AIM: This study aimed to compare and analyze the effects of cranial suture reconstruction and frontal bone reconstruction in the operation of premature closure of the sagittal suture in infants.

MATERIAL and METHODS: A total of 35 infants with simple premature closure of frontal suture were divided into the experimental group (n=18) and the control group (n=17). In the experimental group, the skull model was reconstructed by imaging examination and three-dimensional (3D) printing technique before operation, and the frontal bone reconstruction was used to guide the surgical treatment of cranial stenosis. In the control group, the skull model was reconstructed by imaging examination and 3D printing technique before operation, and the cranial suture reconstruction was performed by the same operator. The surgical effects of the two groups were compared.

RESULTS: During the 12-month follow-up after operation, the interfrontal angles of scaphoid malformation were 153.67 ± 12.77 and 128.67 ± 7.90 in the experimental and control groups, respectively. The difference between the two groups was statistically significant.

CONCLUSION: Frontal bone reconstruction surgery can guide the operation of cranial stenosis, significantly improve the surgical treatment effect of infants with frontal suture, and esthetically enhance the head type of infants. Moreover, its effect is better than that of traditional operation, which is worth given significant attention in clinical settings.

KEYWORDS: Infant, Cranial stenosis, Surgery, Premature closure of cranial suture, 3D printing technique

ABBREVIATION: IFA: Interfrontal angle

INTRODUCTION

Simple premature closure of frontal suture in infants is defined as the absence of premature closure of other cranial sutures except frontal suture, such as coronal suture, sagittal suture, and herringbone suture (1,2,9,10). Simple premature closure of frontal suture will cause triangular head deformity in children, that is, abnormal proliferation of bone fibers in the central frontal suture of the frontal bone, leading to the formation of a protruding frontal ridge in the

median sagittal line of the forehead and making the head shape triangular. Frontal suture premature closure is the third most common cranial suture premature closure, after coronal suture and sagittal suture. Although recent studies have reported that its incidence rate has increased to 28%, its incidence is less than 15% (3,4). Compared with other types of cranial stenosis, patients with simple premature closure of frontal suture have younger age of onset, poorer surgical tolerance, and higher surgical risk and other factors.

Thus, the progress of surgical treatment of simple premature closure of frontal suture faces several challenges. There is no unified and representative evaluation index before and after operation, similar with the interfrontal angle (IFA), between the anterior most point of the cranium and the supraorbital notches using multiplanar reconstructions reoriented relative to the Frankfort horizontal plane (angles 111–123 = severe, angles 124–135 = moderate, angles 136–147 = mild, angle > 147 = normal) (4,5). At present, three-dimensional (3D) printing technology has been fully used in various fields of medicine, with the advantages of restoring the shape of the focus at 1:1, simulating the surgical approach, reducing surgical risk, and customizing individual implants (6). The operation of simple premature closure of cranial suture in infants is significantly suitable. Due to the difficulties in diagnosis and treatment of children with premature closure of frontal suture, there are few studies on frontal bone reconstruction, and compared with the literature at the national and international level, no control group has been found. Moreover, there is a lack of accurate data as an evaluation index before and after operation. We used 3D printing technique to assist frontal bone reconstruction to guide the surgical treatment of 18 cases of infantile cranial stenosis and compared 17 cases of cranial suture reconstruction assisted by 3D printing technique as control to explore the comparative analysis of the effect of cranial suture reconstruction and frontal bone reconstruction in the operation of simple frontal suture premature closure in infants. The surgical effect was evaluated by analyzing accurate data.

■ MATERIAL and METHODS

A total of 35 infants with simple frontal suture premature closure treated in our department from July 2012 to November 2020 were included. The inclusion criteria were as follows: 1) patients with the main symptom of triangular head deformity; 2) patients with cranial computed tomography (CT) suggesting that there was simple closure of frontal suture, which was not associated with the closure of other cranial sutures, and with an IFA < 135°; 3) patients with no surgical history of cranial stenosis; and 4) patients with complete clinical data. The exclusion criteria were as follows: 1) patients with simple frontal suture closure, which is not the main symptom of triangular head deformity or with IFA > 135°; 2) patients with cranial CT suggesting the closure of other cranial sutures; 3) patients with microcephaly; 4) patients with surgical history of a narrow skull; and 5) patients with absent or incomplete clinical data. In the control group, 17 children with simple frontal suture premature closure were treated with preoperative 3D printing on a voluntary basis and were subsequently treated with cranial suture reconstruction. In the experimental group, we introduced a new surgical method, frontal bone reconstruction, and 18 patients who were treated with 3D printing auxiliary frontal frame retraction were included in the experimental group. This study was approved by the hospital ethics committee, and the families of patients signed the informed consent form (Date: 11.01.2021; No: 2021-011-01).

Experimental group: 1) 3D reconstruction and model

printing: patients were routinely examined by CT and magnetic resonance imaging before operation, and the data were processed by a printer to print the skull model according to a 1:1 ratio and make the skull solid anatomical model consistent with the actual size. 2) The IFA value was measured according to the preoperative imaging data, compared with the normal value range, and re-measured on the 3D printed model, and the mean value of the preoperative image measurement value and the model measurement value were calculated to reduce the error. All measurements were completed by the same author. The best splicing method of the frontal bone for frontal bone reconstruction was designed. 3) Operation: 3D printing technique was used to assist frontal bone reconstruction. The method of operation was to peel off the scalp and expose the forehead through the coronal incision of the scalp. Subsequently, direct osteotomy was designed, the frontal bone was cut open, and the osteotomy line was equivalent to the coronal suture. The anterior osteotomy line was located at approximately 1.5–2.0 cm above the superior margin of both orbits. After the frontal bone was cut, the frontal bone was cut into several pieces according to the bone mass designed before operation, and the excess bone tissue was removed. The free bone flap was fixed in the nasal root, lateral orbit, and temporal and bone fragments by the absorbable internal fixation system. All operations were performed by the same operator (Figure 1A-F).

The operation plan of the control group: 3D printing was performed to accurately determine the location of premature closure of cranial suture according to the routine imaging examination data before operation. Subsequently, the cranial suture was reconstructed, and the closed cranial suture was opened. The hyperplastic bone fibers were removed without frontal bone reconstruction, and the operation was performed by the same operator.

Observation indicators: the interfrontal angle (IFA), located between the anterior most point of the cranium and the supraorbital notches using multiplanar reconstructions reoriented relative to the Frankfort horizontal plane, was determined. The duration of operation and the amount of intraoperative blood loss were recorded. The head circumference and IFA of infants with cranial stenosis were recorded before and 12 months after operation.

The Statistical Package for the Social Sciences version 26.0 statistical software was used to process the data. The measurement data are expressed by $X \pm S$, and the counting data are expressed by examples and percentage. The head circumference and IFA were compared by paired t-test before and 12 months after operation. Taking an α level of 0.05 as the test level, $p < 0.05$ as the difference was statistically significant.

■ RESULTS

Comparison of head circumference and IFA in the same group 12 months before and after operation: in the experimental group, the IFAs of triangular head deformity were 121.25 ± 9.47 before operation and 153.67 ± 12.77 12 months after operation. There was a significant difference between the two

groups ($p < 0.05$). In the control group, there was no significant difference in the IFA before and 12 months after operation ($p > 0.05$) (Table I).

Comparison of head circumference and IFA 12 months after operation between the two groups: there was no significant difference in preoperative head circumference and IFA between the two groups. During the 12-month follow-up after operation, the IFAs of triangular head deformity in the experimental and control groups were 153.67 ± 12.77 and 128.67 ± 7.90 , respectively. The difference between the two groups was statistically significant (Table II).

Comparison of intraoperative blood loss and operation time between the two groups: the average operation times

were 2.75 ± 0.68 and 2.59 ± 0.47 hours in the experimental and control groups, respectively. There was no significant difference between the two groups. The average intraoperative blood losses were 114.83 ± 23.37 and 112.48 ± 245.33 ml in the experimental and control groups, respectively. There was no significant difference between the two groups (Table III).

DISCUSSION

This study takes the lead in the clinical application of 3D printing-assisted frontal bone reconstruction in children with simple premature closure of frontal suture and actively explores the clinical value of frontal bone reconstruction in children with simple premature closure of frontal suture. Combined with the

Table I: Comparison of Head Circumference, IFA 12 Months Before and After Operation in the Same Group

	Preoperative head circumference(cm)	Head circumference 12 months after operation (cm)	p	Preoperative IFA	IFA 12 months after operation	p
Experimental group	38.50 ± 1.20	40.70 ± 1.40	0.17	121.25 ± 9.47	153.67 ± 12.77	0.01
Control group	39.20 ± 1.50	41.50 ± 1.50	0.12	122.37 ± 8.33	128.67 ± 7.90	0.31

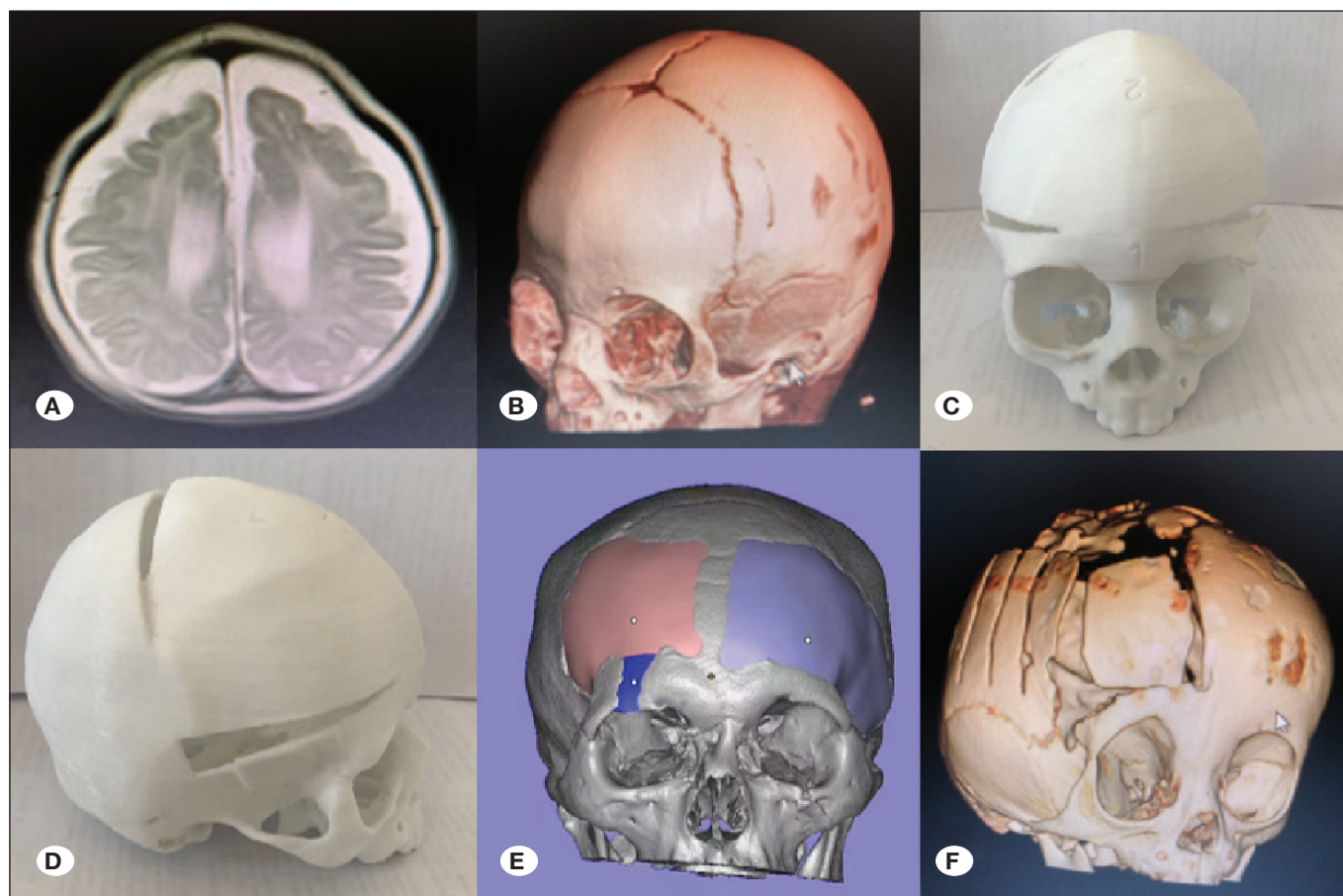


Figure 1: 3D printing technique assisted surgical treatment of infantile cranial stenosis. **A)** Preoperative MRI image **B)** preoperative Head type; **C, D)** preoperative 3D printing model: assist the fronto-orbital band retraction technique and guide the formulation of the operation plan **E)** 3D printing model during operation to guide the operation of frontal bone reconstruction; **F)** The CT images reexamined after operation.

Table II: Comparison of Head Circumference, IFA 12 Months After Operation Between the Two Groups

	Head circumference 12 months after operation (cm)	IFA 12 months after operation
Experimental group	40.70 ± 1.40	153.67 ± 12.77
Control group	41.50 ± 1.50	128.67 ± 7.90
p	0.60	0.01

Table III: Comparison of Intraoperative Bleeding Volume and Operation Time Between the Two Groups

	Operation time (h)	Intraoperative bleeding volume (ml)
Experimental group	2.75 ± 0.68	114.83 ± 23.37
Control group	2.59 ± 0.47	112.48 ± 245.33
p	0.35	0.63

unified and unique accurate data evaluation index before and after operation, this study quantified the surgical effect and accurately evaluated the clinical application effect of frontal bone reconstruction.

Furthermore, 3D printing assisting the fronto-orbital band retraction technique to guide the operation of cranial stenosis can improve the surgical treatment effect of children with premature closure of sagittal suture, and the effect is better than that of traditional cranial suture reconstruction according to the case analysis of this study. As a consequence, it is worthy of clinical promotion. However, the number of cases in this study is small, and the follow-up time is short, which may deviate from the actual theory. The author will continue to follow up and study the patients and summarize the long-term effect of the operation. Premature closure of frontal suture is a common disease in pediatric neurosurgery, which often occurs in infants. Triangular head deformity is the main clinical manifestation, which is often complicated with mental and motor retardation, intracranial hypertension, headache, vomiting, optic papilledema, and other symptoms (1,9,10). In severe cases, brain hernia can even occur, causing respiratory arrest, endangering life and seriously endangering the health of infants. The main treatment is surgical treatment. Traditional surgery cannot effectively correct head deformities and achieve the effect of an esthetically enhanced skull type, and the operation has many complications and high risk. At present, 3D printing technology is widely used in many subprofessional fields of neurosurgery. However, 3D printing technology is rarely used in the operation of premature closure of frontal suture in infants and young children. Through the novelty search report, it is found that there is no control study in the literature in China. This is the first study to use 3D printing technology to assist frontal bone reconstruction to guide the surgical treatment of 18 infants with simple forehead suture premature closure, to compare the effect of 3D print-assisted cranial suture reconstruction in 17 patients with simple frontal suture premature closure as control, and to explore the effect of cranial suture reconstruction and frontal bone reconstruction in infants with simple frontal suture premature closure.

Moreover, 3D printing-assisted frontal bone reconstruction technique significantly improved the effect of surgical treatment of simple premature closure of frontal suture in infants. From the comparison of head circumference and IFA between the same group before and 12 months after operation, it can be observed that there is a significant difference in IFA before and after operation among the children with triangular head deformity. In the control group, there was no significant difference in IFA before and after operation, indicating that the surgical effect of the experimental group was ideal, and it was confirmed that 3D printing-assisted frontal bone reconstruction technology could significantly improve the effect of surgical treatment of simple premature closure of forehead suture in infants. The 3D printing-assisted frontal bone reconstruction technique can restore the deformed skull at a 1:1 ratio and perform the splicing and shaping of the bone flap before operation, which makes the head type of the designed patients closer to the normal skull type, and select the appropriate surgical approach and the open position and size of the skin flap. Thus, the amount of blood loss of the operation is less (6-8), the operation time is shorter, and the risk is lower than the traditional operation. Moreover, frontal bone reconstruction technique truly customizes the optimal operation plan according to the patient's condition, makes the operator more familiar with the mode of operation, and controls the effect of operation, which can significantly improve the therapeutic effect of skull orthopedic surgery for a narrow skull.

Furthermore, 3D printing-assisted frontal bone reconstruction technique guides the operation of early closure of frontal suture, and the effect is better than that of traditional cranial suture reconstruction. In this study, there was no significant difference in preoperative head circumference and IFA between the test and control groups ($p > 0.05$), excluding the influence of interference factors. In children with triangular head deformity mentioned above, there was a significant difference between the two groups 12 months after operation ($p < 0.05$). The postoperative IFA of the experimental group was closer to normal, which indicated that the surgical effect of 3D printing-assisted frontal bone reconstruction was better than that of traditional cranial suture reconstruction, and the

proportion of head shape corrected after operation was more esthetically enhanced. The 3D printing-assisted frontal bone reconstruction technique can accurately design the operation plan according to the imaging data and 3D model before operation, which can make the operation plan more specific and complete, the intraoperative orthopedic effect more significant, and the head's shape closer to the normal head's shape after correction.

The frontal bone reconstruction technique guided the operation of a narrow skull, but there was no evident advantage compared with the control group in shortening the operation time and reducing the amount of intraoperative blood loss. However, the 3D printing-assisted frontal bone reconstruction technique can guide the operation of a narrow skull, accurately make individual operation plan before operation, simulate the operation before operation, shorten the operation time, and reduce the amount of blood loss during the operation. Moreover, it reduces the risk of postoperative general anesthesia, surgical trauma, blood loss, and infection, significantly increases the safety of the operation, and is beneficial to the operation of simple early closure of forehead suture in infants.

■ CONCLUSION

This study has a limitation in that the number of patients in this paper is relatively small, and there may be a deviation from the actual theory. According to the case analysis of this paper, 3D printing-assisted frontal bone reconstruction can guide the operation of cranial stenosis and can improve the surgical treatment effect of children with simple premature closure of frontal suture. The effect is better than that in the traditional cranial suture reconstruction, which is worth given significant attention in clinical settings. We will continue to follow up and study the patients and summarize the long-term effect of the operation.

■ AUTHORSHIP CONTRIBUTION

Study conception and design: MZF

Data collection: QQ

Analysis and interpretation of results: QQ

Draft manuscript preparation: QQ

Critical revision of the article: MZF

Other (study supervision, fundings, materials, etc...): HW, ZTL

All authors (QQ, HW, ZTL, MZF) reviewed the results and approved the final version of the manuscript.

■ REFERENCES

1. Calandrelli R, Pilato F, Massimi L, Panfili M, Marrazzo A, Di Rocco C, Colosimo C: Craniofacial sutural pattern and surgical management in patients with different degrees of trigonocephaly severity. *J Comput Assist Tomogr* 44:374-379, 2020
2. Gleizal A, Di Rocco F, Chauvel-Picard J: Indications of Lefort osteotomies for facial deformities induced by craniosynostosis. *Neurochirurgie* 65:279-285, 2019
3. Kajdic N, Spazzapan P, Velnar T: Craniosynostosis - Recognition, clinical characteristics, and treatment. *Bosn J Basic Med Sci* 18:110-116, 2018
4. Kellogg R, Allori AC, Rogers GF, Marcus JR: Interfrontal angle for characterization of trigonocephaly: Part 1: development and validation of a tool for diagnosis of metopic synostosis. *J Craniofac Surg* 23:799-804, 2012
5. Massimi L, Bianchi F, Frassanito P, Calandrelli R, Tamburrini G, Caldarelli M: Imaging in craniosynostosis: When and what? *Childs Nerv Syst* 35:2055-2069, 2019
6. Mocquard C, Aillet S, Riffaud L: Recent advances in trigonocephaly. *Neurochirurgie* 65:246-251, 2019
7. Qian XY, Jin LD, Tao WH, Zhao JH, Hong SQ: Clinical application of 3D printing technique in cerebral aneurysm surgery. *Chinese Journal of Neuromedicine* 15:484-485, 2016.
8. Safran T, Viezel-Mathieu A, Beland B, Azzi AJ, Galli R, Gilardino M: The state of technology in craniosynostosis. *J Craniofac Surg* 29:904-907, 2018
9. Wu X, Gu Y: Signaling mechanisms underlying genetic pathophysiology of craniosynostosis. *Int J Biol Sci* 15:298-311, 2019
10. Yilmaz E, Mihci E, Nur B, Alper OM, Tacoy S: Recent advances in craniosynostosis. *Pediatr Neurol* 99:7-15, 2019