

# Is Standalone Posterior Cervical Pedicle Screw Fixation Sufficient to Correct Cervical Postlaminectomy Kyphosis?

Yurdal GEZERCAN<sup>1</sup>, Semih Kivanc OLGUNER<sup>1</sup>, Ferhat HARMAN<sup>2</sup>, Baris ARSLAN<sup>3</sup>

<sup>1</sup>Adana City Training and Research Hospital, Department of Neurosurgery, Adana, Turkey

<sup>2</sup>Marmara University Faculty of Medicine, Department of Neurosurgery, Istanbul, Turkey

<sup>3</sup>Adana City Training and Research Hospital, Department of Anesthesiology, Adana, Turkey

**Corresponding author:** Yurdal GEZERCAN ✉ gezercan@hotmail.com

## ABSTRACT

**AIM:** To evaluate the clinical processes of patients with cervical postlaminectomy kyphosis (PLK) who underwent standalone posterior pedicle screw fixation surgery.

**MATERIAL and METHODS:** The results of 21 patients with cervical PLK treated using the pedicle screw method between 2015 and 2018 were retrospectively examined. Patient data included demographic information and indications for surgery. Furthermore, the following criteria were calculated for each patient: cervical sagittal vertical axis (cSVA), C2–7 cervical lordosis (CL) parameters, modified Japanese Orthopaedic Association (mJOA) score, Neck Disability Index (NDI) score and visual analogue scale score, and these were evaluated preoperatively and postoperatively statistically.

**RESULTS:** A total of 21 patients with PLK were evaluated. In terms of radiographic parameters, postoperative cSVA was significantly lower than the preoperative cSVA, and postoperative CL was significantly higher than the preoperative CL ( $p < 0.001$ ,  $p < 0.001$ , respectively). Postoperative mJOA scores were significantly higher than the preoperative scores ( $p < 0.001$ ). Both postoperative NDI and VAS scores were significantly lower than the preoperative scores ( $p < 0.001$ ,  $p < 0.001$  respectively).

**CONCLUSION:** Pedicle screw fixation was found to be an effective treatment for cervical PLK. Although this technique is not preferred by many spine surgeons because of its high complication rate, it has a positive effect on the quality of life scores and provides optimal correction.

**KEYWORDS:** Cervical pedicle screw, Cervical postlaminectomy kyphosis, Cervical radiographic parameters

## INTRODUCTION

Cervical degenerative diseases such as tumours, infections and trauma are common pathologies regularly encountered by spine surgeons. In cases where conservative treatment fails, surgical options are needed. Surgeons aim to relieve the pressure on the neural tissue as soon as possible with a preferred surgical technique. Decompressive laminectomy and facetectomies were the most preferred surgical technique for posterior cervical approaches, as they provide neural decompression and enable rapid recovery. While the neural tissue is relieved from pressure, surgeons should attempt to keep the spine in its normal anatomical alignment. Postlaminectomy kyphosis (PLK) is a common and

complex complication of the extensive resection of posterior elements (4,9). It may be catastrophically due to the typical biomechanics of this area (19). Myelopathic findings may be observed because of the impaired perfusion of the spinal cord secondary to cord compression (22). In advanced cases, gait disorders and upper extremity dysfunction occur. Moreover, horizontal gaze and swallowing disorders may be observed (22).

The most common method of cervical PLK correction is the use of cervical lateral mass screws with or without anterior corpectomies, which may result with unsatisfactory correction or pseudoarthrosis. The cervical pedicle screwing technique

was first described by Abumi et al. and was used in trauma surgery (1). It was then considered for non-traumatic lesions (2). This technique provides a strong stabilisation by fixing the vertebra in three columns when using only the posterior approach (2).

In this retrospective study, we aimed to share our technique of treating patients with cervical PLK by using the standalone pedicle screwing method with reference to radiographic parameters, quality of life indices and complications.

## ■ MATERIAL and METHODS

This study has been carried out in accordance with the principles of the Declaration of Helsinki and approved by the Ethics Committee of Adana City Training and Research Hospital (Approval Date: 15.01.2020; No: 689). Informed consent was obtained from all individual participants included in the study.

The results from 21 patients with cervical PLK treated using the pedicle screw technique between 2015 and 2018 were examined retrospectively. Primary surgical indications were analysed and noted for all patients. The study included 1) patients aged >18 years and 2) those with kyphotic deformity after posterior decompressive surgery, which was corrected with the posterior pedicle fixation alone. PLK occurs when the subaxial C2–7 intervertebral Cobb angle is  $\leq 5^\circ$  or the focal kyphotic angulation is  $> 5^\circ$  between two consecutive subaxial vertebrae, and diagnosed cases were included in the study. Patients with no history of posterior cervical surgery, have flat neck, and have a solid anterior fusion were excluded from the study. The decision to use a posterior surgical approach was based on the flexibility of the neck. Cervical hyperflexion–hyperextension radiographs were obtained preoperatively. If the kyphotic cervical alignment became neutral or lordotic on the lateral dynamic cervical X-ray, the patient was diagnosed with flexible cervical kyphosis and included in the study; otherwise, the patient was excluded from the study (20).

### Surgical Technique

All procedures were performed by the same senior spine surgeon. No traction was used intraoperatively or preoperatively. Posterior pedicle fixation was performed with a free-hand technique under fluoroscopic guidance. Ponte osteotomies were performed on the apex of the cervical kyphosis in all patients, which was determined with preoperative radiological studies (6). The bilateral foramina were opened carefully and widely to prevent root compression during neck correction. Since we can apply strong compressive forces with pedicle screws after ponte osteotomies, the pedicle edges can come into contact with each other and provide sufficient fusion area. Bone autografts obtained from the surgical area and suboccipital bone were used for the fusion procedure (7). Then, pedicle screws of 4 mm diameter and cobalt chromium rods were preferred in all cases to prevent correction loss. The length of screws ranged from 24 to 38 mm. Intraoperative neuromonitoring was implemented in all procedures. While placing the rods on the screw heads, the cranial part of the operating table was elevated gradually to create a lordotic posture to the neck. Then screw nuts were locked.

## Radiological Evaluation

Radiographic measurements were evaluated using a lateral cervical radiography. The cervical sagittal vertical axis (cSVA) and C2–7 cervical lordosis (CL) were measured before surgery and at the last follow-up. The distance between a line perpendicular to the centre of C2 and the posterior superior corner of C7 represents the cSVA. CL was measured with the Cobb method, which was defined as the angle between the C2 inferior endplate and the C7 inferior endplate (5).

The modified Japanese Orthopaedic Association (mJOA) score, Neck Disability Index (NDI) and visual analogue scale (VAS) assessments were performed on patients preoperatively and postoperatively to assess the health-related quality of life and patient comfort. Complications were noted and examined in detail.

## Statistical Analysis

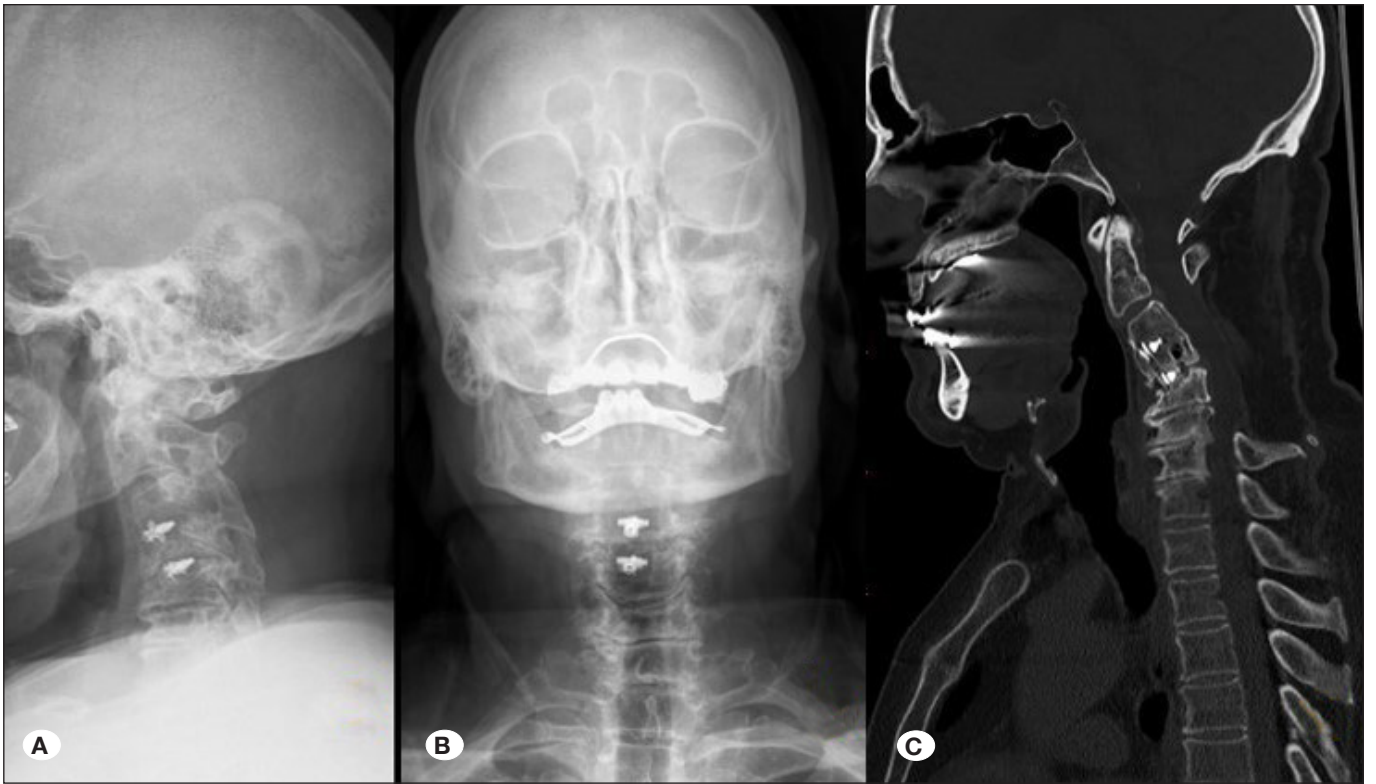For the analysis of variables, SPSS 25.0 (IBM Corporation, Armonk, NY, USA) and PAST 3 (Palaeontological Statistics Software Package for Education and Data Analysis by Hammer, Harper, and Ryan) were used. Compliance of univariate data to a normal distribution was evaluated by the Shapiro–Francia test and compliance of multivariate data to a normal distribution was evaluated by Mardia and Doornik and Hansen omnibus tests, while variance homogeneity was evaluated by Levene’s test for univariate analyses and by Box’s M test for multivariate analyses. When comparing two independent groups based on quantitative data, the independent-samples t test was used with Bootstrap results, and the Mann–Whitney U test was used with Monte Carlo method. To compare two repetitive measurements of dependent quantitative variables, the Wilcoxon signed-rank test was used, and to examine the interaction of repeated quantitative measurements of variables by groups, the general linear model repeated analysis of variance test was used. In the tables, quantitative variables are shown as mean  $\pm$  SD (standard deviation) and as median (minimum–maximum), and categorical variables are shown as n (%). Variables were evaluated at the 95% confidence level, and p-values were considered significant when below 0.05.

## ■ RESULTS

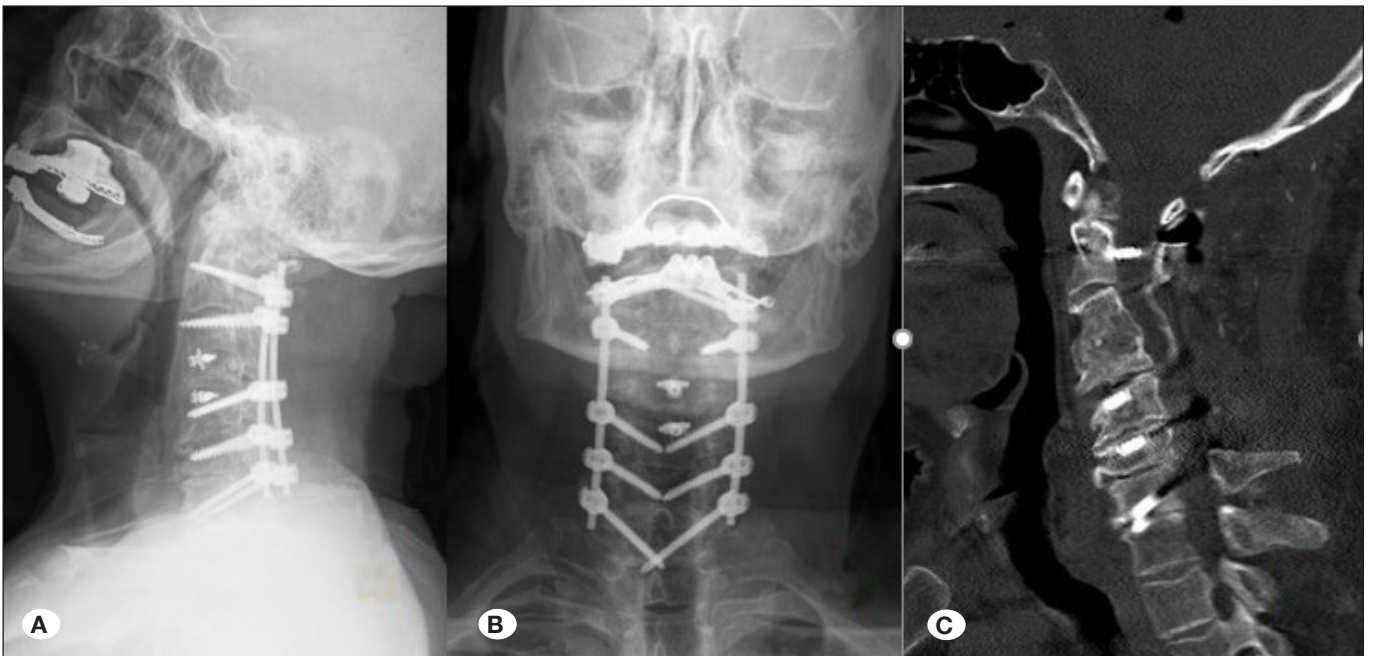
A total of 21 (10 female, 11 male) patients with cervical PLK were evaluated. The mean age was 51 years. The mean follow-up time for the entire study group was 30 months. When the patients were grouped by their primary aetiologies, 12 underwent surgery for cervical spondylotic myelopathy (CSM) (Figures 1A–C, 2A–C), 8 for tumour and 1 for dermal sinus excision (Figures 3A–D, 4A–D) (Table I).

According to statistical results, postoperative cSVA was significantly lower than preoperative cSVA with  $35.10 \pm 6.60$  mm and  $71.14 \pm 5.52$  mm, respectively ( $p < 0.001$ ). Postoperative CL was significantly higher than preoperative CL, with  $14.81^\circ \pm 3.47^\circ$  and  $-13.67^\circ \pm 2.56^\circ$ , respectively ( $p < 0.001$ ) (Table II).

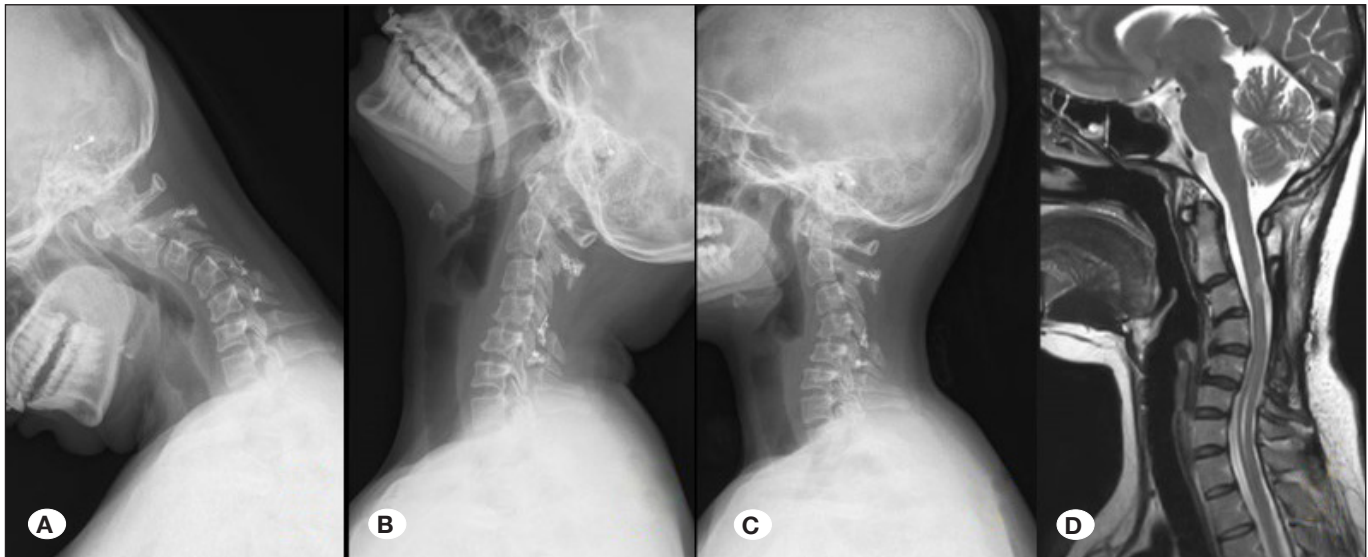
The postoperative mJOA scores were significantly higher than the preoperative scores, with  $13.38 \pm 1.28$  and  $9.38 \pm 1.50$ ,



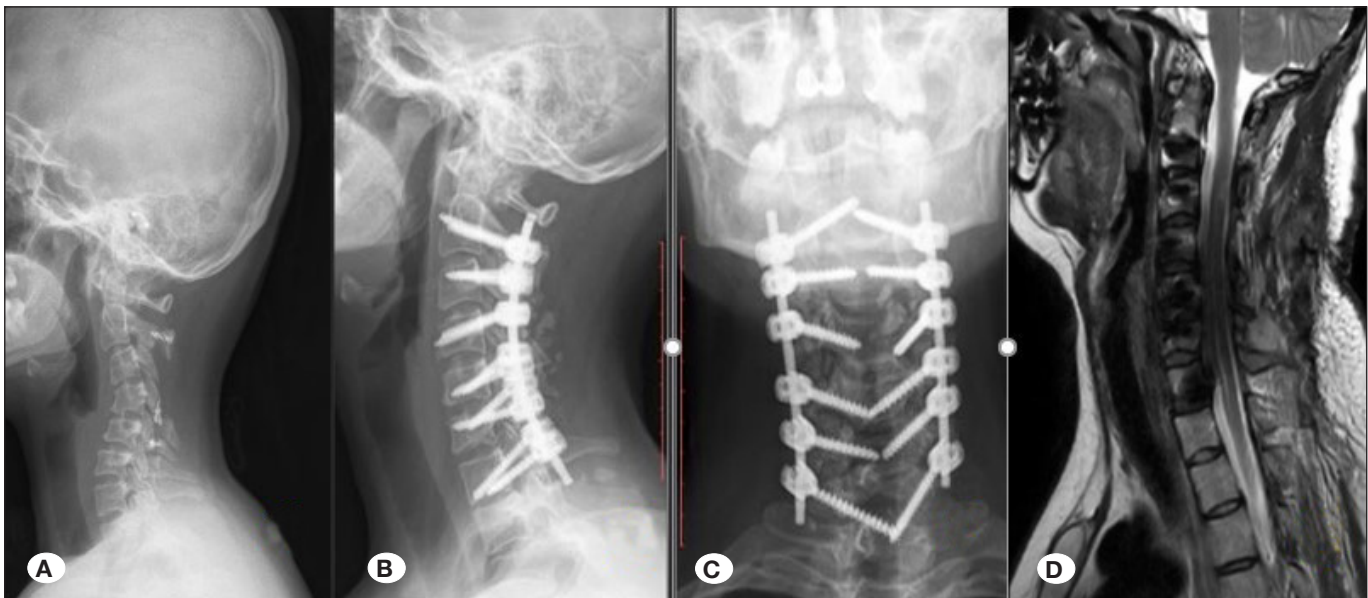**Figure 1:** A 61-year-old male patient underwent 4 levels of extensive total laminectomy due to CSM through C3-4 and C4-5 anterior cervical discectomy + fusion + posterior intervention and severe neck pain started in the patient after 2 months. Postlaminectomy kyphosis is seen on the preoperative direct radiograph (A, B) and (C) computerised tomography (CT) sagittal image, before the patient's corrective surgery.



**Figure 2: A-C)** In the postoperative images, pedicle instrumentation is visualized and kyphosis between C2-7 has resolved.



**Figure 3:** The neck flexibility is observed in preoperative hyperflexion and hyperextension radiographs (A, B) of a female patient who developed postlaminectomy kyphosis in the sixth month after surgery. A laminoplasty was performed after a dermal sinus excision at age 25 (C). Cervical kyphotic deformity in the preoperative lateral radiograph (C) and magnetic resonance imaging (D) draws attention.



**Figure 4:** Preoperative radiograph (A), postoperative radiographs (B, C) and magnetic resonance imaging (D) demonstrating that kyphosis has completely resolved after pedicle fixation between C2-7 and two levels of ponte osteotomy (C4-5 and C5-6) are performed.

respectively. Postoperative NDI scores were significantly lower than the preoperative scores, with  $15.24 \pm 4.24$  and  $29.76 \pm 4.85$ , respectively ( $p < 0.001$ ). The postoperative VAS scores were significantly lower than the preoperative scores, with median (min-max) scores of 3 (2-6) and 8 (7-9), respectively.

Complications occurred in 4 of 21 (19%) patients. Superficial wound infection was seen in two patients, and partial C5 palsy was found in two patients. In this study, a total of 198 pedicle screws were used. Screw malposition was evaluated with the postoperative axial computed tomography (CT) scan, as

described by Yoshimoto et al. (24). According to the position of the screws in the pedicle, they were classified as (1) complete perforation (CP) if  $>50\%$  of the screw diameter exceeded the pedicle wall, (2) partial perforation (PP) if  $<50\%$  of the screw diameter exceeded the pedicle and (3) no perforation when the screw was completely within the pedicle. In this study, 17 (8.5%) screws were causing pedicle perforation. All screw malpositions were found on the lateral wall. Moreover, 14 screws have PP and three screws have CP. However, no vascular complications that required revision surgery were noted.

**Table I:** Clinical Features of the Study Group

Case	Age	Gender	Primary Etiology	Follow up Period (months)	Levels of Instrumentation	Number of Osteotomy Levels	Complication
1	26	Female	Dermal sinus	32	C3-4-5-6-7	2	C5 Palsy
2	68	Male	CSM	24	C4-5-6-7	2	-
3	47	Male	Tumor	26	C3-4-5-6-7	2	-
4	52	Male	CSM	24	C2-3-4-5-6-7	2	-
5	51	Male	Tumor	31	C3-4-5-6-7	2	-
6	63	Male	CSM	28	C3-4-5-6	2	-
7	68	Female	CSM	39	C3-4-5-6-7	2	-
8	41	Female	Tumor	25	C3-4-5-6-7	2	Superficial wound infection
9	69	Female	CSM	33	C3-4-5-6-7	2	-
10	70	Male	CSM	24	C4-5-6	2	-
11	39	Female	Tumor	29	C2-3-4-5-6	3	-
12	57	Male	CSM	25	C3-4-5-6-7-T1	2	-
13	61	Male	CSM	40	C3-4-5-6-7	3	-
14	51	Female	CSM	24	C3-4-5-6-7	3	-
15	71	Female	CSM	26	C3-4-5-6-7	2	C5 Palsy
16	38	Female	Tumor	25	C3-4-5-6	2	-
17	49	Female	Tumor	44	C3-4-5-6-7	3	-
18	51	Male	CSM	25	C3-4-5-6-7	2	Superficial wound infection
19	43	Female	Tumor	26	C3-4-5-6-7	3	-
20	50	Male	CSM	52	C3-4-5-6-7	3	-
21	45	Male	Tumor	29	C4-5-6	2	-

## ■ DISCUSSION

Extensive laminectomies performed on the cervical spine can lead to PLK by changing the underlying biomechanics characteristic of this area. The weight of the head is distributed to the subaxial cervical spine through the occipital condyles, C1 lateral mass, and C1–2 facet joints. The intervertebral discs carry approximately 1/3 of the axial load between C2 and C7 vertebrae, while the facet joints carry 2/3 of the load (22). Therefore, in cases of disrupted facet capsule and damaged posterior tension band, spasm occurs in the paraspinal muscles to balance the forces that pull the head forward (9, 22). Paraspinal muscles attempt to keep the head upright, and this process leads to pain and fatigue clinically, which lead to kyphotic deformity and eventually rapid degeneration and height loss in the intervertebral discs, resulting in a vicious cycle that accelerates the deformity (22). A few studies have focused on cervical PLK (4,9). In these studies, correction strategies

were performed by an anterior or a combined anterior–posterior approach. To the best of our knowledge, this is the first study presenting a case series in which standalone cervical pedicular fixation was the sole method used in cervical PLK treatment. In this context, we aimed to examine all aspects of the clinical process that occurred in the patient group.

Neck pain is one of the most common complaints in patients with PLK, which badly affect the functional capacity and quality of life. To evaluate the neck pain and functional capacity, VAS, NDI and mJOA scores were commonly used to evaluate patients with PLK. O'shaughnessy et al. treated cervical kyphoses (combined approach in all patients and lateral mass screws had been preferred in subaxial cervical region) in 16 patients and reported that Nurick scores improved with the improvement of cervical alignment (18). In another study, Grosso et al. shared the results of 36 patients with cervical kyphosis, and all patients underwent the combined approach,

Table II: Demographic and Clinical Data

	Female (n=10)	Male (n=11)	Total (n=21)	p
	Median (Min./Max.)	Median (Min./Max.)	Median (Min./Max.)	
Age	49 (26 / 71)	51.5 (45 / 70)	51 (26 / 71)	0.426 <sup>u</sup>
Follow up period	29 (24 / 44)	31 (24 / 52)	30 (24 / 52)	0.114 <sup>u</sup>
<sup>w</sup> p value for preop postop comparison	0.003	0.007	<0.001	
<b>VAS</b>				
Preoperative (A)	8 (7 / 9)	8 (7 / 9)	8 (7 / 9)	0.782 <sup>u</sup>
Postoperative (B)	3 (2 / 6)	3 (2 / 5)	3 (2 / 6)	0.426 <sup>u</sup>
Difference (B-A)	-5 (-6 / -2)	-5 (-7 / -3)	-5 (-7 / -2)	0.980 <sup>u</sup>
<sup>w</sup> p value for preop postop comparison	<0.001	0.002	<0.001	
	<b>Mean ± SD.</b>	<b>Mean ± SD.</b>	<b>Mean ± SD.</b>	
<b>CSVA</b>				
Preoperative (A)	69.82 ± 5.02	72.60 ± 5.93	71.14 ± 5.52	0.263 <sup>t</sup>
Postoperative (B)	36.09 ± 6.54	34.82 ± 7.02	35.10 ± 6.60	0.952 <sup>t</sup>
Difference (B-A)	-33.73 ± 5.68	-37.78 ± 4.65	-36.04 ± 5.31	0.209 <sup>g</sup>
<sup>g</sup> p value for preop postop comparison	<0.001	<0.001	<0.001	
<b>CL</b>				
Preoperative (A)	-13.27 ± 1.95	-14.10 ± 3.14	-13.67 ± 2.56	0.473 <sup>t</sup>
Postoperative (B)	11.55 ± 3.14	14.20 ± 3.43	14.81 ± 3.47	0.080 <sup>t</sup>
Difference (B-A)	24.82 ± 4.05	28.30 ± 4.47	28.48 ± 4.51	0.078 <sup>g</sup>
<sup>g</sup> p value for preop postop comparison	<0.001	<0.001	<0.001	
<b>MJOA</b>				
Preoperative (A)	9.09 ± 1.51	9.70 ± 1.49	9.38 ± 1.50	0.366 <sup>t</sup>
Postoperative (B)	13.73 ± 1.35	13.00 ± 1.15	13.38 ± 1.28	0.199 <sup>t</sup>
Difference (B-A)	4.64 ± 1.29	3.30 ± 1.16	4.00 ± 1.38	0.022 <sup>g</sup>
<sup>g</sup> p value for preop postop comparison	<0.001	<0.001	<0.001	
<b>NDI</b>				
Preoperative (A)	30.91 ± 3.83	28.50 ± 5.70	29.76 ± 4.85	0.266 <sup>t</sup>
Postoperative (B)	14.91 ± 3.18	15.60 ± 5.34	15.24 ± 4.24	0.719 <sup>t</sup>
Difference (B-A)	-16.00 ± 4.22	-12.90 ± 3.11	-14.52 ± 3.97	0.073 <sup>g</sup>
<sup>g</sup> p value for preop postop comparison	<0.001	<0.001	<0.001	

<sup>g</sup> General Linear Model Repeated ANOVA (Wilks' Lambda), <sup>t</sup> Independent T Test (Bootstrap), <sup>u</sup> Mann-Whitney U Test (Monte Carlo), <sup>w</sup> Wilcoxon Signed Ranks Test (Monte Carlo), **SD**: Standard deviation, **Min**: Minimum, **Max**: Maximum

dorsal approach alone (lateral mass screws in subaxial cervical spine) and ventral approach alone, and they concluded that the increase in CL reflected an improvement of mJOA scores (12). Virk et al. examined cervical deformity in three groups and revealed that decreases in local kyphosis of patients with focal deformity improved the NDI and mJOA scores as well as the numerical rating scale for neck pain after 1 year (23). In this study, the postoperative VAS, NDI and mJOA scores were distinctly better than their corresponding preoperative scores. Obviously, the correction of lordosis and restoration of cervical alignment is the main reason for the improvement of functional capacity and decreases the neck pain.

The surgical treatment of PLK is a challenging procedure and mainly aims to correct the CL and restore the cervical alignment. The anterior, posterior or combined anterior–posterior approach is used for the correction. The most popular method for correcting PLK is anterior discectomy–corpectomy with cervical hybrid fixation, which means that the lateral mass screw had or had no pedicle screw (16–18). The combined anterior–posterior approach is commonly accepted in correcting cervical kyphotic deformity; however, no standard treatment method has been established for flexible cervical kyphosis. The requirement of longer segment stabilisation is the disadvantage of the posterior approach; however, it avoids the complications of combined surgery. Mummaneni et al. reported satisfactory results with the combined anterior and posterior approach in 30 patients with cervical kyphosis, and they used lateral mass screws for the posterior approach to fix cervical deformity (16). Nottmeier et al. used the combined anterior–posterior approach in 41 patients with cervical kyphosis, but they did not mention the type of kyphosis fixed. They used a hybrid system for the posterior approach and performed pedicle screw techniques only for C2 and C7 pedicles (17). Song et al. compared anterior alone with the combined anterior–posterior approach in 21 patients with flexible and 9 with fixed cervical kyphosis, and they found that CL correction was superior with the combined anterior–posterior approach than with the anterior approach alone (20). Although the posterior approach appeared to be less effective than the combined anterior–posterior approach in managing cervical kyphotic deformity (3,11,13), Abumi et al. suggested the use of standalone cervical pedicle screws for correction in flexible cervical kyphosis. They found improvement of kyphosis from 28.4° to 5.1° in their series using pedicle screws only (3). Biomechanically, the pull-out strength of pedicle screws is superior than that of lateral mass screws (14,15). Shorter screws and less bone interface markedly decrease the pull-out strength in lateral mass screws (15). Thus, manoeuvre for kyphosis correction may result with instrument failure during surgery. By contrast, pedicle screws have very strong pull-out strength that provides powerful manoeuvre force more easily and safely for kyphosis correction. In this study, cSVA and C2–7 CL were markedly improved on postoperative measurement, which is compatible with the literature. The use of strong pedicle screws and the amount of correction provided by multilevel ponte osteotomies allowed us to complete the stabilisation at C7 because ideal alignment was achieved. Although we provide the ideal alignment in this series by ending at C7, it would be appropriate to extend to T1

or T2 vertebra according to the results of the long-term follow-up. Cervical standalone pedicle fixation may be preferred for the correction of flexible PLK because the anterior approach is not needed and pedicle screws provide stronger pull-out strength than cervical lateral mass screws for PLK correction.

Although we cannot report long-term results, we encountered some complications, which include an average follow-up period of 2.5 years. No mechanical complications, such as screw fracture or rod fracture, were observed. Lateral pedicle perforation was detected in 17 screws (8.5%); however, no patients required revision surgery. Superficial wound infection developed in two patients, and they received medical treatment without the need for surgical debridement. No vertebral artery damage was observed. While no neurological deficits due to spinal cord injury were recorded, partial C5 palsy developed in two cases after 48 h postoperatively. Although ponte osteotomies were performed and C5 roots were widely decompressed, C5 palsy occurred in two patients. However, since all patients had a kyphotic deformity, the resulting root tension from the spinal cord shifting post-correction caused this difference. Patients recovered completely within 1 month after medical and physical therapy. Many studies have addressed C5 palsy, which is a common complication of posterior cervical surgery, and complication rates vary between 5% and 14% (8,10,21). In this study, this complication was noted in 9.5% (2/21) patients, and this parallels the literature.

The retrospective design of this study and the limited number of patients can be considered the most noteworthy limitations of the study. In addition, more parameters could be used during radiographic evaluation, and a more detailed analysis could be performed. The T1 slope could be measured to obtain normative values of the CL, and the chin–brow vertical angle could be measured to evaluate horizontal gaze. Regarding its strength, this study is the first detailed study examining the treatment of post-laminectomy kyphosis with cervical pedicle screws. In future studies, long-term results would be helpful.

## ■ CONCLUSION

Cervical pedicle screw fixation provides rigid fixation of the vertebra and an effective deformity correction. This fixation method, which offers a satisfactory improvement of quality of life indices and radiological parameters, can be performed in selected cases by experienced surgeons.

## ■ AUTHORSHIP CONTRIBUTION

**Study conception and design:** YG, SKO

**Data collection:** YG, SKO, FH, BA

**Analysis and interpretation of results:** YG, SKO, FH, BA

**Draft manuscript preparation:** YG, SKO, FH, BA

**Critical revision of the article:** YG, SKO, FH

**Other (study supervision, fundings, materials, etc...):** BA

All authors (YG, SKO, FH, BA) reviewed the results and approved the final version of the manuscript.

## ■ REFERENCES

- Abumi K, Itoh H, Taneichi H, Kaneda K: Transpedicular screw fixation for traumatic lesions of the middle and lower cervical spine: Description of the techniques and preliminary report. *J Spinal Disord* 7:19-28, 1994
- Abumi K, Kaneda K: Pedicle screw fixation for nontraumatic lesions of the cervical spine. *Spine (Phila Pa 1976)* 22:1853-1863, 1997
- Abumi K, Shono Y, Taneichi H, Ito M, Kaneda K: Correction of cervical kyphosis using pedicle screw fixation systems. *Spine (Phila Pa 1976)* 24:2389-2396, 1999
- Albert TJ, Vacarro A: Postlaminectomy kyphosis. *Spine (Phila Pa 1976)* 23:2738-2745, 1998
- Ames CP, Blondel B, Scheer JK, Schwab FJ, Le Huec JC, Massicotte EM, Patel A, Traynelis V, Kim HJ, Shaffrey C, Smith J, Lafage V: Cervical radiographical alignment: Comprehensive assessment techniques and potential importance in cervical myelopathy. *Spine (Phila Pa 1976)* 38:S149-S160, 2013
- Ames CP, Smith JS, Scheer JK, Shaffrey CI, Lafage V, Deviren V, Moal B, Protosaltis T, Mummaneni P, Mundis G, Hostin R, Klineberg E, Burton D, Hart R, Bess S, Schwab F: A standardized nomenclature for cervical spine soft-tissue release and osteotomy for deformity correction. *J Neurosurg Spine* 19:269-278, 2013
- Bauman JA, Hardesty DA, Heuer GG, Storm PB: Use of occipital bone graft in pediatric posterior cervical fusion: An alternative paramedian technique and review of the literature - Technical note. *J Neurosurg Pediatr* 7:475-481, 2011
- Bydon M, Macki M, Kaloostian P, Sciubba DM, Wolinsky JP, Gokaslan ZL, Belzberg A, Bydon A, Witham T: Incidence and prognostic factors of C5 Palsy: A clinical study of 1001 cases and review of the literature. *Neurosurgery* 74:595-604, 2014
- Deutsch H, Haid RW, Rodts GE, Mummaneni PV: Postlaminectomy cervical deformity. *Neurosurg Focus* 15(3):E5, 2003
- Eskander MS, Balsis SM, Balinger C, Howard CM, Lewing NW, Eskander J, Aubin M, Lange J, Eck J, Connolly P, Jenis L: The association between preoperative spinal cord rotation and postoperative C5 nerve palsy. *J Bone Jt Surg - Ser A* 94:1605-1609, 2012
- Grosso MJ, Hwang R, Krishnaney AA, Mroz TE, Benzel EC, Steinmetz MP: Complications and outcomes for surgical approaches to cervical kyphosis. *J Spinal Disord Tech* 28:E385-E393, 2015
- Grosso MJ, Hwang R, Mroz T, Benzel E, Steinmetz MP: Relationship between degree of focal kyphosis correction and neurological outcomes for patients undergoing cervical deformity correction surgery. *J Neurosurg Spine* 18:537-544, 2013
- Helenius IJ, Sponseller PD, Mackenzie W, Odent T, Dormans JP, Asghar J, Rathjen K, Pahys JM, Miyajima F, Hedequist D, Phillips JH: Outcomes of spinal fusion for cervical kyphosis in children with neurofibromatosis. *J Bone Jt Surg - Am* 98:e95, 2016
- Ito Z, Higashino K, Kato S, Kim SS, Wong E, Yoshioka K, Hutton WC: Pedicle screws can be 4 times stronger than lateral mass screws for insertion in the midcervical spine: A biomechanical study on strength of fixation. *J Spinal Disord Tech* 27:80-85, 2014
- Johnston TL, Karaikovic EE, Lautenschlager EP, Marcu D: Cervical pedicle screws vs. lateral mass screws: Uniplanar fatigue analysis and residual pullout strengths. *Spine J* 6:667-672, 2006
- Mummaneni PV, Dhall SS, Rodts GE, Haid RW: Circumferential fusion for cervical kyphotic deformity: Clinical article. *J Neurosurg Spine* 9:515-521, 2008
- Nottmeier EW, Gordon Deen H, Patel N, Birch B: Cervical kyphotic deformity correction using 360-degree reconstruction. *J Spinal Disord Tech* 22:385-391, 2009
- O'Shaughnessy BA, Liu JC, Hsieh PC, Koski TR, Ganju A, Ondra SL: Surgical treatment of fixed cervical kyphosis with myelopathy. *Spine (Phila Pa 1976)* 33:771-778, 2008
- Scheer JK, Tang JA, Smith JS, Acosta FL Jr, Protosaltis TS, Blondel B, Bess S, Shaffrey CI, Deviren V, Lafage V, Schwab F, Ames CP: Cervical spine alignment, sagittal deformity, and clinical implications: A review. *J Neurosurg Spine* 19:141-159, 2013
- Song KJ, Johnson JS, Choi BR, Wang JC, Lee KB: Anterior fusion alone compared with combined anterior and posterior fusion for the treatment of degenerative cervical kyphosis. *J Bone Jt Surg - Ser B* 92B:1548-1552, 2010
- Takemitsu M, Cheung KMC, Wong YW, Cheung WY, Luk KDK: C5 nerve root palsy after cervical laminoplasty and posterior fusion with instrumentation. *J Spinal Disord Tech* 21:267-272, 2008
- Tan LA, Riew KD, Traynelis VC: Cervical spine deformity-part 1: Biomechanics, radiographic parameters, and classification. *Neurosurgery* 81:197-203, 2017
- Virk S, Passias P, Lafage R, Klineberg E, Mundis G, Protosaltis T, Shaffrey C, Bess S, Burton D, Hart R, Kim HJ, Ames C, Schwab F, Smith J, Lafage V: Intraoperative alignment goals for distinctive sagittal morphotypes of severe cervical deformity to achieve optimal improvements in health-related quality of life measures. *Spine J* 20(8):1267-1275, 2020
- Yoshimoto H, Sato S, Hyakumachi T, Yanagibashi Y, Kanno T, Masuda T: Clinical accuracy of cervical pedicle screw insertion using lateral fluoroscopy: A radiographic analysis of the learning curve. *Eur Spine J* 18:1326-1334, 2009