Turk Neurosurg, 2022

Original Investigation

DOI: 10.5137/1019-5149.JTN.36660-21.2

Received: 18.09.2021
Accepted: 19.01.2022

Published Online: 15.06.2022

Is Balloon Kyphoplasty Effective for Bone Remodeling of AO-Type A3–4 Fractures at the Thoracolumbar Junction?

Inan UZUNOGLU[1], Gokhan GURKAN[1], Baran TASKALA[2], Ilker Deniz CINGOZ[3], Murat ATAR[4], Ismail KAYA[3], Kazım Ayberk SINCI[5], Yusuf Kenan CETINOGLU[6], Nurullah YUCEER[1]

[1]Katip Celebi Unıversity Ataturk Training and Research Hospital, Department of Neurosurgery, Izmir, Turkey
[2]Istanbul Basaksehir Cam and Sakura State Hospital, Department of Neurosurgery, Istanbul, Turkey
[3]Usak University School of Medicine, Department of Neurosurgery, Usak, Turkey
[4]Sultan Abdulhamid Han Training and Research Hospital, Department of Neurosurgery, Istanbul, Turkey
[5]Katip Celebi University Ataturk Training and Research Hospital, Department of Radiology, Izmir, Turkey
[6]Batman Training and Research Hospital, Department of Radiology, Batman, Turkey

Corresponding author: Inan UZUNOGLU ✉ dr_inan_uzunoglu@hotmail.com

ABSTRACT

AIM: To evaluate the parameters that affect bone retropulsion and restoration in patients with thoracolumbar junction (TLJ) vertebral compression fractures (VCF) without neurological deficits who underwent balloon kyphoplasty (BKP).

MATERIAL and METHODS: Thirty-one of Frankel E and Arbeitsgemeinschaft für Osteosynthesefragen (AO) A3–4 type VCFs fractures at the TLJ, with bone retropulsion into the spinal canal, from 2017 to 2020, were evaluated retrospectively. Data was gathered on patient demographics and medical histories. Measurements of anterior vertebral heights, posterior vertebral heights, local kyphotic angles, spinal cord area, and bone retropulsion into the spinal canal (BRC) were evaluated preoperatively, early postoperatively, and late postoperatively.

RESULTS: In those patients who underwent early surgery (<4 weeks postfracture), a significantly greater increase in anterior vertebral heights was seen between early postoperative and preoperative measurements than in patients who underwent late surgery (>4 weeks postfracture) (p=0.016). At the six-month follow-up, a significantly greater decrease in local kyphotic angle measurements was seen in patients over 65 years of age than those under 65 (p=0.023). Comparison of local kyphotic angles between sexes revealed a significant decrease in measurements at follow-up in female patients (p=0.029). Both early postoperative and late postoperative local kyphotic angle measurements of patients with a body mass index (BMI) ≥25 were significantly lower than those of patients with a BMI <25 (p=0.012).

CONCLUSION: The restoration of vertebral angles and heights with the maximum level of BKP can effectively reduce BRC.

KEYWORDS: Anterior-posterior vertebral height, Balloon kyphoplasty, Bone retropulsion into the spinal canal, Local kyphotic angle, Vertebral compression fractures

ABBREVIATIONS: AVH: Anterior vertebral height, **BKP:** Balloon kyphoplasty, **BMI:** Body mass index, **BMD:** Bone mineral density, **BRC:** Bone retropulsion into the spinal canal, **CT:** Computed tomography, **25-OH-D3:** D vitamin, **LKA:** Local kyphotic angle, **MRI:** Magnetic resonance imaging, **PACS:** Picture Archiving and Communication Systems, **PV:** Percutaneous vertebroplasty, **PVH:** Posterior vertebral height, **STIR:** Short tau inversion recovery, **SCA:** Spinal cord area, **SPSS:** Statistical Package for the Social Sciences, **TLJ:** Thoracolumbar junction, **VCF:** Vertebral compression fractures

Inan UZUNOGLU : 0000-0001-5859-0443
Gokhan GURKAN : 0000-0003-1839-1014
Baran TASKALA : 0000-0002-3398-3846
Ilker Deniz CINGOZ : 0000-0002-0452-7606
Murat ATAR : 0000-0001-6047-2956
Ismail KAYA : 0000-0002-5117-8066
Kazım Ayberk SINCI : 0000-0002-2207-5850
Yusuf Kenan CETINOGLU : 0000-0002-7878-6117
Nurullah YUCEER : 0000-0003-3509-9939

INTRODUCTION

Traumatic spine fractures occur most frequently in the thoracic and lumbar vertebral segments (8), with the most common location being the thoracolumbar junction (TLJ/Th10–L2) (8,16). Approximately half of all TLJ fractures are to the Th12–L1 vertebrae. Regarding the formation of fractures, Research suggests that the greater incidence of fractures at this location is due to the greater mobility of this region of the spine (8).

In spinal fractures, factors such as the cause and severity of the trauma, and the patient's bone quality affect the neurological outcome (20). The patient's neurological condition post-trauma and the morphology of the fracture guide the treatment choices (20). In recent years, balloon kyphoplasty (BKP) has taken the place of bed rest and spinal instrumentation as the treatment of choice for compression fractures without neurological deficits and is favored over percutaneous vertebroplasty (PV) due to its rapid pain palliation, restoration of high vertebral loss, and lower rate of cement leakage (4).

However, some have suggested that BKP is contraindicated in cases with bone retropulsion into the spinal canal (BRC) (4). These fractures occur when the anterior and middle column cannot bear the axial load, causing the posterior wall of the spine to protrude into the epidural area. Yet, there is little data on the effects of BKP on bone restoration in cases with BRC. Bone restoration can be achieved by stretching the posterior longitudinal ligament (3).

In this study, we conducted a retrospective evaluation of data from our clinic on bone repair and restoration of TLJ fractures in cases with BRC to determine the efficacy and safety of BKP with such patients.

MATERIAL and METHODS

The Institutional Review Board (IRB) approved the study protocol (December 24, 2020, decision number 1095).

Patient Selection

BKP has been applied in our clinic with increasing frequency since the end of 2000. It is our policy to operate as soon as possible on neurologically intact (Frankel grade E) Arbeitsgemeinschaft für Osteosynthesefragen (AO) A-type spinal fractures, provided patient consent is given after they have been informed of the surgical risks and alternative treatments (such as bed rest and spinal stabilization). We recommend the BKP procedure to these patients., BKP has also been recommended in our clinic for vertebral compression fractures (VCF) with BRC for the last five years. Radiological confirmation of VCF along with pain or tenderness upon spinous process palpation are accepted as adequate surgical indications, regardless of the time elapsed since the trauma. Surgery is not indicated in patients who present with pain but whose spinal short tau inversion recovery (STIR) magnetic resonance imaging (MRI) shows no hyperdensity in the relevant area. All AO B and C-type spinal trauma patients with BRC are treated with decompression and stabilization.

Between 2017 and 2020, a total of 284 patients were treated for vertebral fractures at our clinic with BKP. Of these, 31 received surgical intervention for single compression fractures of vertebrae in the TLJ (Th10–11–12–L1–2). These were included in the study. Inclusion criteria were a single surgery for a spinal fracture to the TLJ on any single level of the spine during the delineated period; damage to the posterior wall of the spine or BRC without neurological deficits (Frankel grade E); and A3–A4 fractures according to AO classification (13). Exclusion criteria were more than one operation, including additional spinal surgery (minimally invasive surgeries, decompression, stabilization, or injection) to any part of the spine before or at the same time as the TLJ operation, or during the follow-up period; fractures classified as A1–2, B, or C-type; patients with a preoperative malignancy diagnosis, or patients whose intraoperative biopsy results were compatible with malignancy or infection; and patients with diseases that impair bone metabolism (such as Paget or chronic renal failure), known or revealed by biopsy. The biopsies performed used routine BKP biopsy procedures (17).

Data Collection

Patients' medical files were accessed retrospectively and the age, sex, body mass index (BMI), 25-hydroxyvitamin D(25(OH) D3 levels, bone mineral density (BMD), additional diseases, and time elapsed between trauma and surgery were recorded. The patients' fractured vertebrae were automatically measured for anterior and posterior vertebral heights (A-PVHs) (mm), local kyphotic angle (LKA) (°), and spinal cord area (SCA) (mm^2) from the Picture Archiving and Communication System (PACS) by determining the cross-section of the computed tomography (CT) imaging with the highest pressure and manually marking the area around the axial spinal CT. The amount of BRC (mm) was determined visually as the area with the most bone retropulsion to the normal corpus posterior wall. These measurements were all taken preoperatively, early postoperatively, and late postoperatively (six months after the initial axial and sagittal spinal CT scans) by a radiologist with at least five years' experience. The amount of bone cement (polymethyl methacrylate) used during the operation (cc), the operation type (unilateral or bilateral), the BKP balloon size (cc) used during the procedure, the type of bone fracture according to the McCormack load sharing classification system (10), and the current AO/Magerl classifications were determined (Figure 1-3).

Operation Planning

Pain complaints leading to suspicion of fracture were investigated with X-ray and spinal CT scans. Spinal magnetic resonance radiography (MRI) with STIR was performed. A hyperdense appearance in the TLJ was taken as confirmation of fracture. However, in patients with a contraindication for MRI (such as a cardiac pacemaker) fractures were determined from clinically compatible pain and spinal CT findings. All patients were operated on under sedoanalgesics with fluoroscopy using standard BKP procedures. They were advised to come for control with the results of the biopsy while being discharged the same day or the next day.

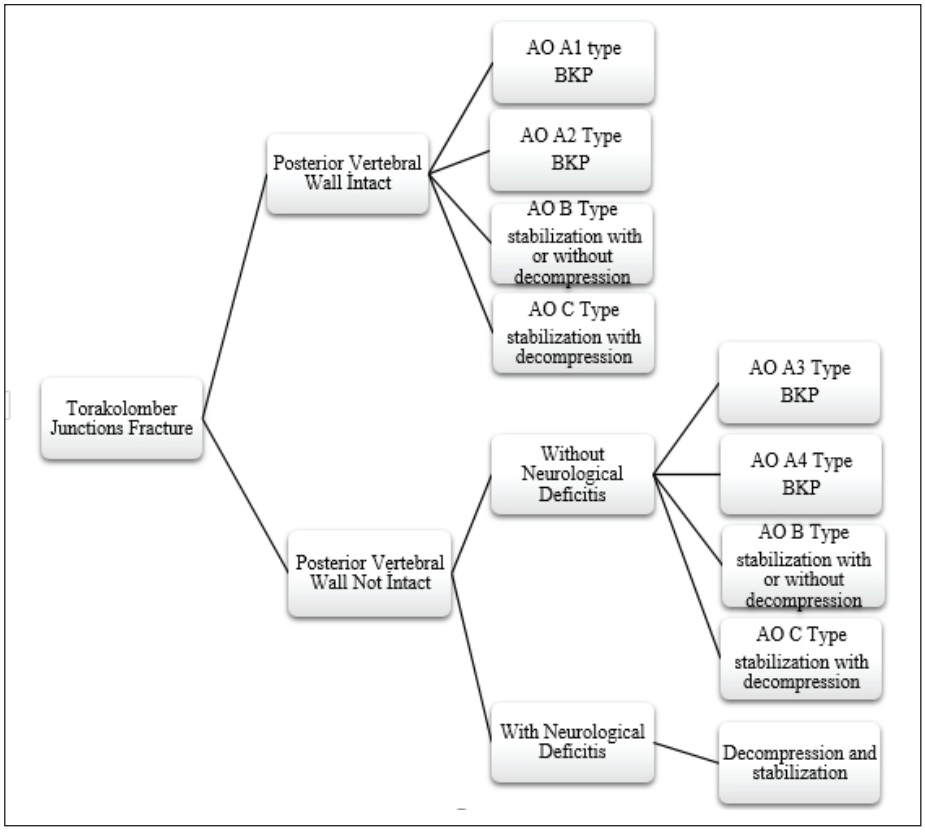

Figure 1: Surgery algorithm for bone remodeling of AO type A3–4 fracture at the thoracolumbar junction using balloon kyphoplasty based on radiological and neurological data.

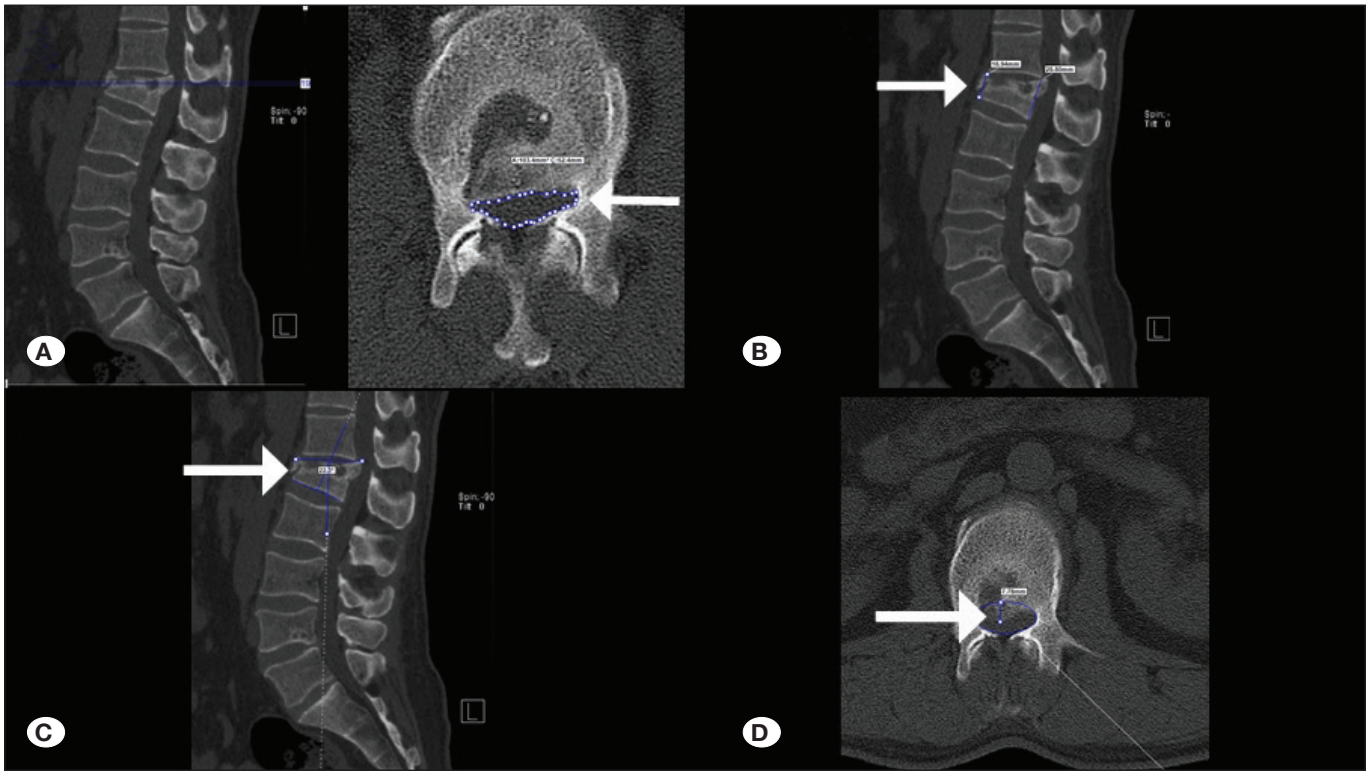

Figure 2: Preoperative axial and sagittal computed tomography images of AO type A3–4 fracture at the thoracolumbar junction. White arrows show **A)** SCA measurements on sagittal and axial CT; **B)** AVH and PVH measurements on sagittal CT; **C)** LKA measurements on sagittal CT; **D)** BRC measurements on axial CT. **AVH:** Anterior vertebral heights, **BRC:** Bone retropulsion into the spinal canal, **CT:** Computed tomography, **LKA:** Local kyphotic angle, **PVH:** Posterior vertebral heights, **SCA:** Spinal cord area.

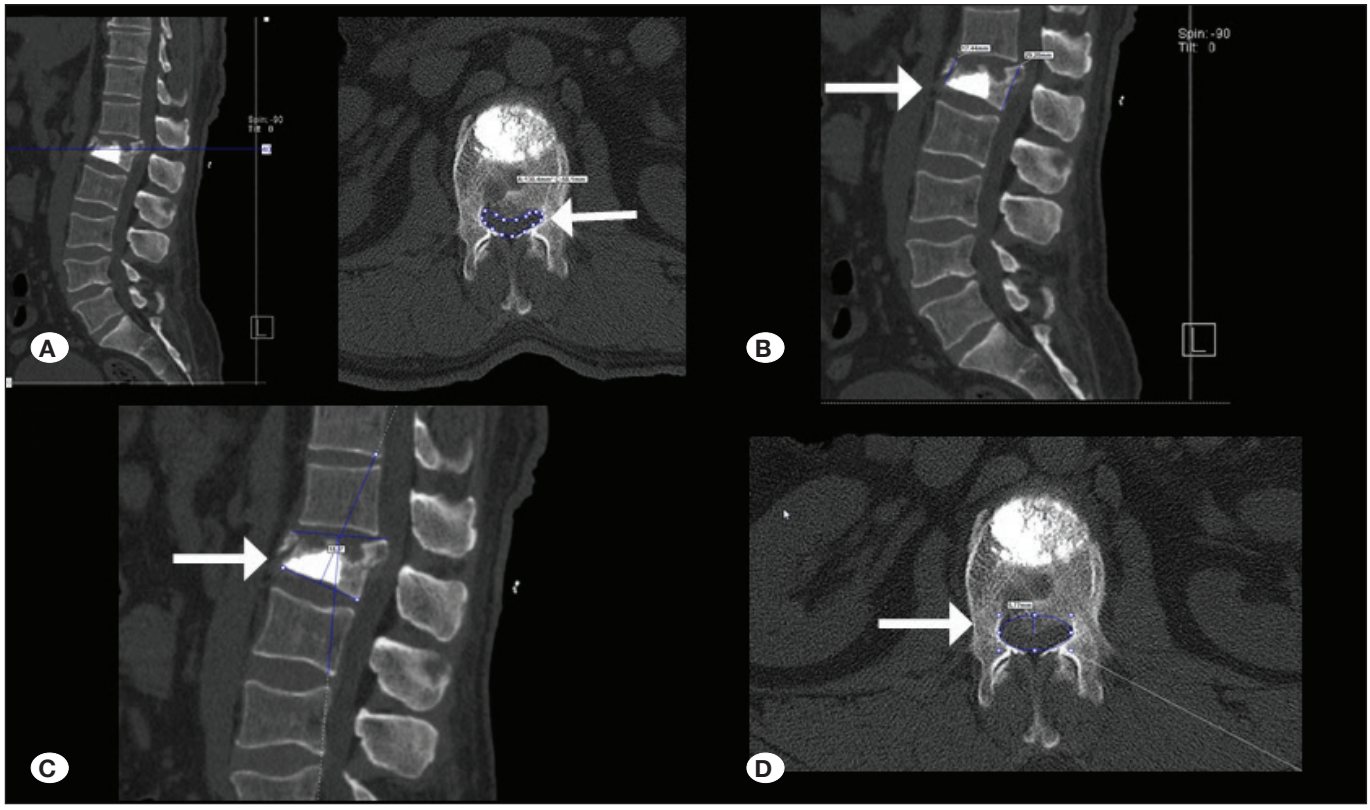

Figure 3: Early postoperative axial and sagittal computed tomography images of remodeled AO type A3–4 fracture at the thoracolumbar junction. White arrows show **A)** SCA measurements on sagittal and axial CT; **B)** AVH and PVH measurements on sagittal CT; **C)** LKA measurements on sagittal CT; **D)** BRC measurements on axial CT. **AVH:** Anterior vertebral heights, **BRC:** bone retropulsion into the spinal canal; **CT:** Computed tomography, **LKA:** Local kyphotic angle, **PVH:** Posterior vertebral heights, **SCA:** Spinal cord area.

Operation Procedure

During surgery, the corpus anterior-posterior distance was divided into four equal parts on a lateral X-ray, and the injection of cement toward the posterior of the 3/4 area to the anterior of the corpus was marked as a red line. The procedure was terminated in cases of cement damage to the posterior of the 2/3 area remaining anterior to the corpus. The approximate setting times of all cement used during the operation were known to us. Slow-drying cement is preferred during multi-level BKP, while fast-drying cement is preferred for single-level operations. Before the cement was placed in the working cannula with a filler device, the solidification of the preoperative cement was rechecked by the surgeon. The cement was sent into the corpus very slowly, using more X-rays to aid visualization. In addition, overfilling of the corpus with cement was carefully avoided as it could prevent bone fragment remodeling. A balloon was used to inflate the fractured corpus, with emphasis on maximizing the anterior-posterior height of the corpus. Simultaneously, a neurological examination of the patient was performed and they were asked whether they had lower back or leg pain).

Statistical Analysis

Statistical analysis was performed on Statistical Package for the Social Sciences (SPSS) v. 15.0 (IBM Corp., Armonk, New York, USA) software. Data were analyzed with either chi-square or Mann–Whitney U tests. A p-value of <0.05 was considered statistically significant.

RESULTS

In our study, 7 of the 31 patients treated with BKP were male and 24 were female. The mean age was 71.16 ± 11.60 (range = 47–91). No additional predisposing disease was present in 25 (80, 60%) patients. The mean BMI of the patients who underwent surgery 1–75 days post-trauma was 29.87 ± 5.51 kg/m^2, and the mean BMD was −1.71 ± 1.10 g/cm^2. The patients' mean level of 25-hydroxyvitamin D(25(OH)D3 at the time of admission was 34.06 ± 25.29 µg/L. While the fractures of 26 patients were due to trauma, the etiology of the fracture was undetermined in the other 5 patients. Unilateral BKP was performed in 26 patients, while unilateral surgery was performed in 5 patients. A 15 cc BKP balloon was used in 15 patients and a 20 cc balloon in 16 patients. Using AO/Magerl thoracolumbar fracture classification, A3 (87, 10%) fractures were the most common in our patients. Lumbar one fractures were treated in 15 (48, 40%) patients. An average of 5.75 ± 7.98 cc of cement was injected into each vertebral fracture. After BKP, radiological cement leakage was detected in 17 (54, 80%) patients without clinical findings. A score of 4 on the McCormack load sharing classification was observed in 19 (61, 30%) of our patients. None of our patients had

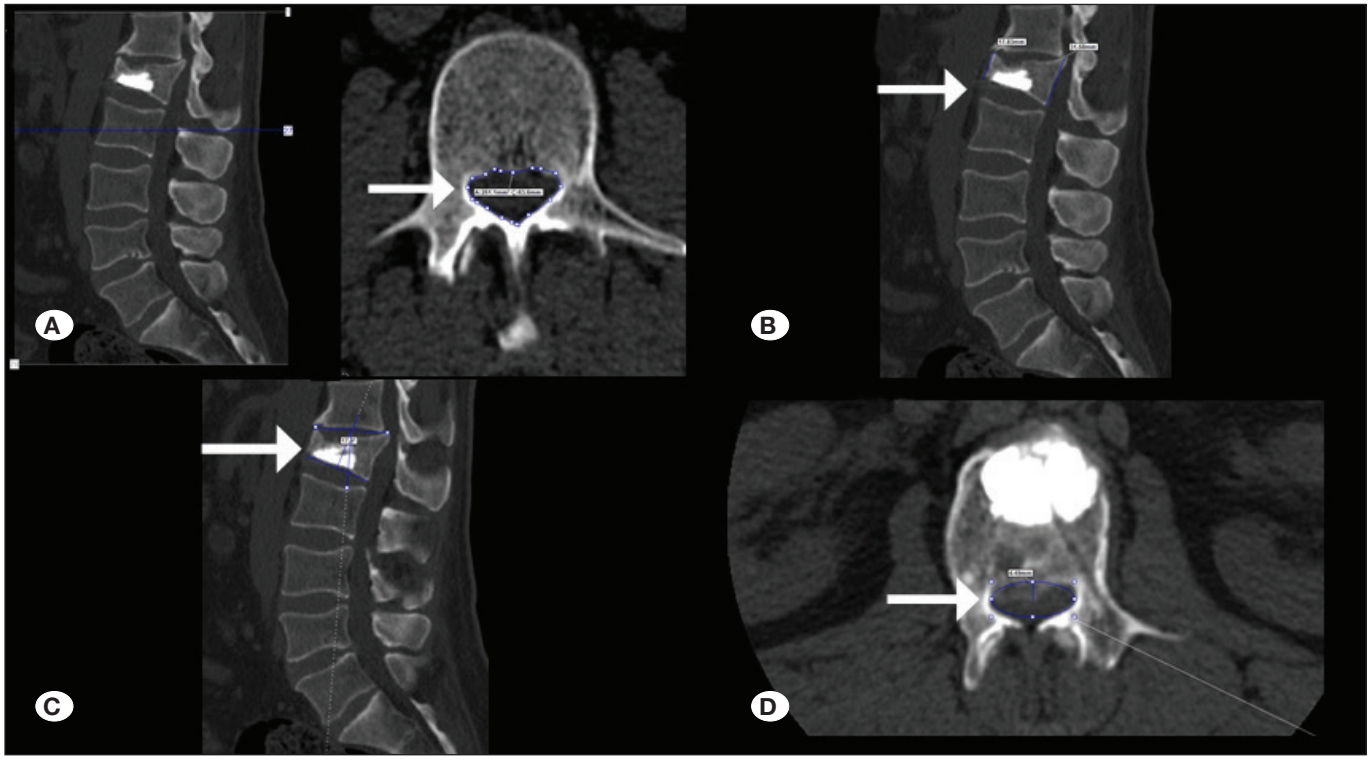

Figure 4: Late postoperative axial and sagittal computed tomography images of remodeled AO type A3–4 fracture at the thoracolumbar junction. White arrows show **A)** SCA measurements on sagittal and axial CT; **B)** AVH and PVH measurements on sagittal CT; **C)** LKA measurements on sagittal CT; **D)** BRC measurements on axial CT. **AVH:** Anterior vertebral heights, **BRC:** Bone retropulsion into the spinal canal, **CT:** Computed tomography, **LKA:** Local kyphotic angle, **PVH:** Posterior vertebral heights, **SCA:** Spinal cord area.

preoperative or postoperative neurological deficits and all were classified as Frankel grade E (Table I).

The mean anterior vertebral height (AVH) was 15.53 ± 4.14 mm. The change in AVH at patient follow-ups averaged 1.63 ± 3.69 mm. The mean posterior vertebral height (PVH) was 21.34 ± 3.16 mm, and the total change measured at follow-up was 0.23 ± 2.63 mm. The mean LKA was 12.45 ± 5.61°, and its total change was −2.90 ± 4.57°. The mean SCA was 80.10 ± 13.86 mm^2, and its total change was 13.26 ± 19.61 mm^2. The mean BRC was 4.55 ± 1.96 mm, and the total change was −0.19 ± 2.12 mm (Table II).

Surgery was performed on 23 (74, 20%) patients within the first four weeks (early) after trauma or pain onset, while 8 (25, 80%) patients underwent surgery more than four weeks after trauma or onset (late). In 22 (22/23) of the patients who were operated on early, a significant increase was seen between preoperative and early postoperative AVH (p=0.016). A total of 11 patients were under 65 years of age, and 20 were over 65. A significant decrease in LKA was found at the six-month follow-up in patients over 65 years compared to patients under 65 years of age (p=0.023). When LKA was evaluated by sex, a significant decrease was found in the LKA of female patients at the follow-up (p=0.029). There were significant differences in the amount of early postoperative and late postoperative LKA decrease between patients with BMI ≥25 and those with BMI <25 (p=0.012) (Table III).

A significant decrease in the amount of bone displaced into the spinal canal was seen between preoperative and late postoperative measurements in cases where over 5 cc of cement was injected during the BKP procedure (p=0.023). The amount of bone displaced into the spinal canal was significantly higher in our female patients than in our male patients (p=0.043). The higher the preoperative PVH (>20 mm), the more significant a decrease in retropulsion was found postoperatively (<3.5 mm) (p=0.047). The lower the LKA (<10°) in the early follow-up, the greater the amount of late postoperative BRC (>3.5 mm) (p=0.022) (Table IV).

Patient biopsy results were evaluated for different stages of bone healing (normal bone tissue). Patients were discharged on either the same day as the operation or the day after.

DISCUSSION

In studies of conservative treatment options for VCFs, BKP has been shown to significantly reduce recovery time, pain, and mortality due to complications that result from prolonged bed rest in elderly patients (5,18). Moreover, malignancies can be detected incidentally in the biopsy results taken during the BKP procedure, providing earlier oncological diagnoses and treatment, prolonging survival (17).

Vertebral compression fractures are most frequently seen at the TLJ. In TLJ vertebral fractures, AO/Magerl type A fractures, and cases of spinal canal compression without

Table I: Distribution of Patients According to Their General Data

Characteristic	n (%)
Sex	
Male	7 (22.60)
Female	24 (77.40)
Age	71.16 ± 11.60 (47-91)
≤65	11 (35.50)
>65	20 (64.50)
Predisposing disease	
Yes	7 (19.40)
No	25 (80.60)
The time between the trauma and the operation (day)	18.35 ± 18.31 (1-75)
<7	12 (38.70)
8-28	11 (35.50)
28<	8 (25.80)
BMI (kg/m^2)	29.87 ± 5.51 (20-38)
<25	10 (32.30)
≥25	21 (67.70)
BMD (g/cm^2)	-1.71±1.10 (-3.60-1.10)
Osteoporosis	7 (22.60)
Osteopenia	17 (54.80)
Normal	7 (22.60)
25-OH-D_3 (µg/L)	34.06 ± 25.29 (3-124)
Severe Deficiency	6 (19.40)
Deficiency	7 (22.60)
Normal	18 (58.10)
Etiology	
Trauma	26 (83.90)
Unknown	5 (16.10)
Side	
Unilateral	26 (83.90)
Bilateral	5 (16.10)
Baloon Volume (ml)	
15	15 (48.40)
20	16 (51.20)
AO Classification	
A3	27 (87.10)
A4	4 (12.90)
Level	
Th10	0
Th11	2 (6.50)
Th12	9 (29.00)
L1	15 (48.40)
L2	5 (16.10)
Cement Volume (ml)	5.75 ± 7.98 (3-12)
<5	18 (58.10)
≥5	13 (41.90)
Cement Leakage	
Yes	17 (54.80)
No	14 (45.20)
McCormack Load Sharing score	
3	0 (0.00)
4	19 (61.30)
5	5 (16.10)
6	4 (12.90)
7	2 (6.50)
8	1 (3.20)
9	0 (0.00)

+ *Coronary artery disease, Hypertension, Hyperlipidemia*

neurological deficits (Frankel grade E), treatment with BKP is an increasingly favored option.

In BKP, the vertebral body is inflated using a balloon to restore vertebral height. This stretches the ligaments and reduces the LKA, causing the displaced bone fragments compressing the spinal canal to return to their correct positions (22).

Palmowski et al. analyzed a case series in which AVH was shown to increase significantly more after kyphoplasty for thoracolumbar fractures in those who underwent early surgery than in those who were operated on later (12). In another study of 72 patients, postoperative AVHs were found to be higher in patients who underwent early BKP than those treated later (15). In our study, the first four weeks were regarded as early surgical intervention, and AVH was found to increase significantly between the preoperative and early postoperative periods in 22 of the 23 patients who were operated on early compared with those operated on later (p=0.016). Arabmotlagh et al. conducted a study of 31 patients with an average age of 67.7 years and found a decrease in LKA in the 12-month follow-up period, but it was not statistically significant (1). Noriega et al. found that radiological correction could not be achieved in the LKA (11). In another study, vertebral fractures were followed conservatively without surgical intervention, and LKA in elderly patients was found to be significantly lower than in younger patients (6). In our study, a decrease in LKA was seen in 19 of the 20 patients over the age of 65 and in 7 of the 11 patients under 65. A significantly greater decrease in LKA was seen in the patients over 65 than those under 65 (p=0.023). Goldstein et al. followed vertebral fractures conservatively, observing radiological data, and found no significant association between sex and LKA (6). In our study, we saw a decrease in LKA in 4 of the 7 male patients and 22 of the 24 female patients. The decrease was significantly greater in the female patients than the male patients (p=0.029). This is likely to be because the bone quality of women is lower. Lin et al. found no significant difference was found between BMI and LKA in their BKP study (9). In contrast, we saw a decrease in LKA in 19 of 21 patients with BMI ≥25 and 5 of 10 patients with BMI <25. Moreover, a statistically significant difference was found between early postoperative and late postoperative patients with BMI ≥25 and BMI <25 (p=0.012).

Research has found an increase in TLJ fractures and recurrent fractures in those over 60 with serum vitamin D deficiencies (21). However, we found no relationship between serum vitamin D deficiency and vertebral fractures, AVH, PVH, or LKA. While other studies have shown improvements in LKA in follow-ups up to three years after BKP (2), we found no significant differences in LKA between the early postoperative and late postoperative measurements. This suggests that the cost and utility of our six-month follow-up examinations should be reconsidered.

Hiwatashi and Westesson (7) found no significant difference in the amount of preoperative and postoperative retropulsion in corpus fractures with spinal canal compression that had undergone PV, while other studies have found a decrease in canal compression with PV and BKP (4,14). Although not statistically significant, we saw an increase in SCA in the

Table II: Preoperative, Early Postoperative, and Late Postoperative Results According to the Radiological Data of the Patients

	Preoperative (Mean)	Early Postoperative (Mean)	Late Postoperative (Mean)	D- preoperative-early postoperative	D early-late postoperative	D-total
AVH (mm)	15.53 ± 4.14 (4.8-22.5)	17.60 ± 3.31 (10.6-25.2)	17.16 ± 2.75 (9.9-25.2)	2.07 ± 2.48 (-2.7-9.3)	-0.42 ± 2.18 (-5.3-3.7)	1.63 ± 3.69 (-5.4-9.4)
PVH (mm)	21.34 ± 3.16 (16.6-29.0)	22.21 ± 2.69 (17.9-29.2)	21.60 ± 3.55 (13.7-31.0)	0.83 ± 1.75 (-2.9-5.8)	-0.60 ± 2.52 (-7.1-3.1)	0.23 ± 2.63 (-6.2-4.6)
LKA (°)	12.45 ± 5.61 (2.5-21.7)	9.44 ± 4.66 (2.3-19.4)	8.31 ± 4.25 (2.0-18.3)	-2.88 ± 3.62 (-10.9-7.9)	-0.90 ± 2.73 (-8.3-5.8)	-2.90 ± 4.57 (-14.5-3.1)
SCA (mm^2)	80.10 ± 13.86 (47-97)	81.68 ± 12.63 (52-98)	82.39 ± 12.39 (52-99)	10.58 ± 11.04 (-17-40)	2.61 ± 13.93 (-26-28)	13.26 ± 19.61 (-20-54)
BRC (mm)	4.55 ± 1.96 (1.4-8.4)	4.19 ± 1.61 (1.4-7.0)	4.15 ± 1.59 (1.6-7.0)	-0.36 ± 0.81 (-1.7-2.7)	0.22 ± 1.93 (-3.5-7.0)	-0.19 ± 2.12 (-5.0-5.0)

AVH: *Anterior vertebral heights,* ***PVH:*** *Posterior vertebral heights,* ***LKA:*** *Local kyphotic angles,* ***SCA:*** *Spinal cord area, BRC: Bone retropulsion into the spinal canal.*

Table III: Distribution of Kyphotic Angle Changes by Age and Gender During the Six-Month Follow-Up Period

	Number of Patients D-LKA↑	Number of Patients D-LKA↓	p
Age			
≤65	4	7	
>65	1	19	**0.023**
Sex			
Male	3	4	
Female	2	22	**0.029**
BMI*			
<25	5	5	
≥25	2	19	**0.012**

LKA: *Local kyphotic angle. * The D-LKA in the table was arranged according to the preoperative and early postoperative data.*

Table IV: BRC; Changes According to Cement Volume, Gender, Preoperative PVH and Early Postoperative LKA Data

	No. of patients BRC ↑*	No. of patients BRC ↓*	p
Cement Volume (cc)			
<5	10	8	**0.023**
≥5	2	11	
Gender			
Female	7	17	
Male	5	2	**0.043**
Preoperative PVH (mm)			
≥20	9	9	
<20	2	11	**0.047**
Early postoperative LKA (°)			
<10°	13	4	
≥10°	5	9	**0.022**

BRC: *Bone Retropulsion Into The Spinal Canal,* ***PVH:*** *Posterior Vertebra Height,* ***LKA:*** *Local Kyphotic Angle. * BRC ≥3.5mm and above was considered as increasing and <3.5 as decreasing.*

preoperative, early postoperative, and late postoperative periods. In BKP of vertebral compression fractures with low bone strength and loose bone structure, vertebral height is restored by the balloon, the cavity is prepared for safe cement injection, and the displaced bone fragments are directed back into the vertebrae by ligaments and cerebrospinal fluid pressure (4).

In our study, 11 of the 13 patients who underwent BKP in the TLJ showed a statistically significant decrease in the amount of BRC (p=0.023). In their study of stabilization in vertebral fractures, Yuan et al. (19) reported an increase in SCA in patients whose PVH was restored and LKA corrected. Similarly, it has been determined that low PVH (3) and correction of LKA with BKP (4) directly facilitate the regression of retropulsion. our study determined that the higher the preoperative PVH (>20 mm), the more significant the decrease in the late postoperative BRC (<3.5 mm), while the lower the LKA (10°) in the early follow-up, the greater the late postoperative BRC (3.5 mm).

In patients with BRC, there may be spontaneous partial or near-total resorption of bone fragments and the diameter of the spinal canal can increase, and the bone compression disappears, over time (4). Some studies have suggested that decompression of the spinal canal and radiological correction may not improve the neurological condition (4). For this reason, pain palliation and partial correction of spinal deformities are sufficient for BRC without neurological deficits, which are most often seen in elderly patients. Therefore, it is clear that BKP is efficient and sufficient as a minimally invasive surgery in these patients.

The primary limitation of our study was the small sample size resulting from the specificity of our inclusion criteria. Nevertheless, there are few detailed studies on this topic in the literature. It is anticipated that further contributions will be made by similar studies in the future with larger samples.

CONCLUSION

BKP was found to be a safe, effective, minimally invasive surgical approach to the restoration of neurologically intact thoracolumbar vertebral fractures with bone fragment compression to the spinal canal. Our study indicates that increasing the PVH and LKA at the highest rate with BKP can effectively reduce BRC. However, further studies with larger sample sizes are needed.

AUTHORSHIP CONTRIBUTION

Study conception and design: IU

Data collection: GG, BT

Analysis and interpretation of results: IDC, MT

Draft manuscript preparation: IK, KAS

Critical revision of the article: YKC

Other (study supervision, fundings, materials, etc...): NY

All authors (IU, GG, BT, IDC, MA, IK, KAS, YKC, NY) reviewed the results and approved the final version of the manuscript.

REFERENCES

1. Arabmotlagh M, Nikoleiski SC, Schmidt S, Rauschmann M, Rickert M, Fleege C: Radiological evaluation of kyphoplasty with an intravertebral expander after osteoporotic vertebral fracture. J Orthop Res 37:457-465, 2019
2. Chalhoub G, Cheung B, Gonzalez C: Balloon kyphoplasty complication: A case of a lodged balloon within the vertebral body. Cureus 12:e10542, 2020
3. Dai J, Lin H, Niu S, Wu X, Wu Y, Zhang H: Correlation of bone fragments reposition and related parameters in thoracolumbar burst fractures patients. Int J Clin Exp Med 8:11125-11131, 2015
4. Gan M, Zou J, Zhu X, Wang G, Yang H: Balloon kyphoplasty for osteoporotic spinal fractures with middle column compromise. Injury 45:1539-1544, 2014
5. Garfin SR, Buckley RA, Ledlie J, Balloon Kyphoplasty Outcomes G: Balloon kyphoplasty for symptomatic vertebral body compression fractures results in rapid, significant, and sustained improvements in back pain, function, and quality of life for elderly patients. Spine 31:2213-2220, 2006
6. Goldstein S, Smorgick Y, Mirovsky Y, Anekstein Y, Blecher R, Tal S: Clinical and radiological factors affecting progressive collapse of acute osteoporotic compression spinal fractures. J Clin Neurosci 31:122-126, 2016
7. Hiwatashi A, Westesson PLA: Vertebroplasty for osteoporotic fractures with spinal canal compromise. AJNR Am J Neuroradiol 28:690-692, 2007
8. Jaiswal NK, Kumar V, Puvanesarajah V, Dagar A, Prakash M, Dhillon M, Dhatt SS: Necessity of direct decompression for thoracolumbar junction burst fractures with neurological compromise. World Neurosurg 142:e413-e419, 2020
9. Lin J, Qian L, Jiang C, Chen X, Feng F, Lao L: Bone cement distribution is a potential predictor to the reconstructive effects of unilateral percutaneous kyphoplasty in OVCFs: A retrospective study. J Orthop Surg Res 13:140, 2018
10. McCormack T, Karaikovic E, Gaines RW: The load sharing classification of spine fractures. Spine 19:1741-1744, 1994
11. Noriega DC, Ramajo RH, Lite IS, Toribio B, Corredera R, Ardura F, Krüger A: Safety and clinical performance of kyphoplasty and SpineJack(®) procedures in the treatment of osteoporotic vertebral compression fractures: A pilot, monocentric, investigator-initiated study. Osteoporos Int 27:2047-2055, 2016
12. Palmowski Y, Balmer S, Burger J, Schomig F, Hu Z, Pumberger M: Influence of operative timing on the early post-operative radiological and clinical outcome after kyphoplasty. Eur Spine J 29:2560-2567, 2020
13. Schnake KJ, Schroeder GD, Vaccaro AR, Oner C: AOSpine Classification Systems (Subaxial, Thoracolumbar). J Orthop Trauma 31 Suppl 4:S14-S23, 2017
14. Shin JJ, Chin DK, Yoon YS: Percutaneous vertebroplasty for the treatment of osteoporotic burst fractures. Acta Neurochir 151:141-148, 2009

15. Takahashi S, Hoshino M, Terai H, Toyoda H, Suzuki A, Tamai K, Watanabe K, Tsujio T, Yasuda H, Kono H, Sasaoka R, Dohzono S, Hayashi K, Ohyama S, Hori Y, Nakamura H: Differences in short-term clinical and radiological outcomes depending on timing of balloon kyphoplasty for painful osteoporotic vertebral fracture. J Orthop Sci 23:51-56, 2018
16. Trungu S, Forcato S, Bruzzaniti P, Fraschetti F, Miscusi M, Cimatti M, Raco A: Minimally invasive surgery for the treatment of traumatic monosegmental thoracolumbar burst fractures: Clinical and radiologic outcomes of 144 patients with a 6-year follow-up comparing two groups with or without intermediate screw. Clin Spine Surg 32:E171-E176, 2019
17. Uzunoglu I, Kaya I, Sucu HK, Kizmazoglu C, Sevin IE, Aydin HE, Rezanko TA, Yuceer N: Evaluation of incidentally detected pathology results of patients with vertebral fracture treated by vertebroplasty and kyphoplasty: A retrospective study. World Neurosurg 122:e639-e646, 2019
18. Wardlaw D, Cummings SR, Van Meirhaeghe J, Bastian L, Tillman JB, Ranstam J, Eastell R, Shabe P, Talmadge K, Boonen S: Efficacy and safety of balloon kyphoplasty compared with non-surgical care for vertebral compression fracture (FREE): A randomised controlled trial. Lancet 373:1016-1024, 2009
19. Yuan L, Yang S, Luo Y, Song D, Yan Q, Wu C, Yang H, Zou J: Surgical consideration for thoracolumbar burst fractures with spinal canal compromise without neurological deficit. J Orthop Translat 21:8-12, 2020
20. Yuksel MO, Gurbuz MS, Gok S, Karaarslan N, Is M, Berkman MZ: The association between sagittal index, canal compromise, loss of vertebral body height, and severity of spinal cord injury in thoracolumbar burst fractures. J Neurosci Rural Pract 7:S57-S61, 2016
21. Zhang L, Chun C, Yang Y, Liu B, Zhu Y, Chen R, Rong L: Vitamin D deficiency/insufficiency is associated with risk of osteoporotic thoracolumbar junction vertebral fractures. Med Sci Monit 25:8260-8268, 2019
22. Zou J, Mei X, Gan M, Wang G, Lu J, Yang H: Is kyphoplasty reliable for osteoporotic vertebral compression fracture with vertebral wall deficiency? Injury 41:360-364, 2010