

Investigation of Possible Reasons of Failed Treatment of Conservative Thoracolumbar Osteoporotic Vertebral Fractures

Mustafa Abdullah OZDEMIR¹, Serkan BAYRAM², Sahin KARALAR², Murat KORKMAZ², Ijhan SULEJMANI², Sevan SIVACIOGLU³, Turgut AKGUL²

¹Kahramanmaraş Sutcu Imam University, Faculty of Medicine, Department of Orthopaedics and Traumatology, Kahramanmaraş, Turkey

²Istanbul Faculty of Medicine, Istanbul University, Department of Orthopaedics and Traumatology, Istanbul, Turkey

³Acibadem University, Faculty of Medicine, Department of Orthopaedics and Traumatology, Istanbul, Turkey

Corresponding author: Serkan BAYRAM ✉ dr.serkanbayram89@gmail.com

ABSTRACT

AIM: To investigate the possible reasons of failed conservative treatment of osteoporotic thoracolumbar vertebral compression fractures (VCFs). Sagittal balance impairment may weaken union by increasing the load on the fracture line. Most osteoporotic vertebral fractures occur in the thoracolumbar and mid-thoracic regions.

MATERIAL and METHODS: We investigated the records of patients aged >60 years who underwent treatment for osteoporotic thoracolumbar VCFs between 2012 and 2020. The patients were divided into two groups: those who required surgical treatment due to the failure of conservative treatment and those who were successfully treated with conservative treatment. All the patients underwent lateral radiography and computer tomography of the whole spine at their initial and final visit. The radiographic parameters of spine and presence of sarcopenia, age, and gender were compared between the groups.

RESULTS: Of the study subjects, the mean age of 13 females and 7 males in whom conservative treatment was successful was 67.4 years and the mean follow-up period was 23.5 months, while in 18 females and 5 males who underwent surgical treatment due to the failure of conservative treatment, the mean age was 68.7 years and the mean follow-up period was 22.1 months. No significant differences between the groups regarding age and gender were observed. However, significant differences were observed between the groups regarding the presence of sarcopenia and thoracic kyphosis, thoracolumbar kyphosis and distance from the center of the fractured vertebra to the plumb line (DSVA).

CONCLUSION: Sarcopenia and DSVA were significantly higher in the surgical treatment group. Receiver operating characteristic analysis demonstrated that the sensitivity and specificity of DSVA for identifying high-risk patients for failed conservative treatment of osteoporotic thoracolumbar VCFs were 100% and 95%, respectively, with an optimum diagnostic cutoff value of 6.5 mm.

KEYWORDS: Thoracolumbar region, Osteoporotic vertebral fractures, Sarcopenia, Radiological parameters

ABBREVIATIONS: **CT:** Computed tomography, **PI:** Pelvic incidence, **PT:** Pelvic tilt, **SS:** Sacral slope, **LL:** Lumbar lordosis, **TLK:** Thoracolumbar kyphosis, **TK:** Thoracic kyphosis, **T1SPI:** T1 spinopelvic inclination, **T9SPI:** T9 spinopelvic inclination, **TPA:** T1 pelvic angle, **DSVA:** Distance from the center of the fractured vertebra to the plumb line, **VAS:** Visual analog scale

■ INTRODUCTION

As the average age of the population increases, the proportion of the elderly population and the incidence of osteoporosis increase accordingly (2). Osteoporosis is characterized by the weakening of the bone structure and an increased risk of fractures (3). The estimated lifetime risk of osteoporosis-related fractures after the age of 50 years is 40% for females and 13% for males (11). Most osteoporotic vertebral fractures occur during daily activities and do not result in significant trauma. Although pain occurs in the affected areas for a short time period, the pain often resolves within 2–3 weeks.

The importance of osteoporotic vertebral fractures is increasing and it is accepted as a significant health problem. Managing these fractures can be complicated due to the additional complications associated with aging, multiple drug use, poor functional capacity, and other comorbidities. Most osteoporotic vertebral fractures are conservatively treated with bed rest, analgesia, and osteoporosis treatment, with which most of the fractures functionally heal almost completely (14). However, in some patients, fracture healing is impaired by non-union, endplate collapse, spinal deformity, and spinal cord narrowing. Although these complications are mostly uncommon, they can result in prolonged back pain, deterioration in the performance of daily activities, chronic pain, depression, sleep disturbance, and decreased self-esteem (5). In cases where conservative treatment fails, percutaneous cement strengthening techniques are used (e.g., kyphoplasty and vertebroplasty). The use of spinal instrumentation/implants is required for unstable fractures and in patients with neurological deficits and vertebral deformities.

One of the main objectives of osteoporotic vertebral fracture treatment is enabling union. Impairment in sagittal balance may weaken union by increasing the load on the fracture line (9). Most osteoporotic vertebral fractures occur in the thoracolumbar and midthoracic regions (16). The thoracolumbar region carries the dynamic load along the entire spine and is at the highest risk for kyphotic deformity and nonunion.

This study investigated the possible reasons for failed conservative treatment of osteoporotic thoracolumbar vertebral fractures.

■ MATERIAL and METHODS

Study Design

The study retrospectively reviewed the patients who were followed up with the diagnosis of osteoporotic vertebral fracture in the Department of Orthopedics and Traumatology of the Faculty of Medicine at Istanbul University between 2012 and 2020. The institutional review boards approval was obtained by our Institute of Orthopedics and Traumatology. The study was explained to the patients in detail and written informed consent was obtained from all the patients prior to their participation in the study.

Inclusion criteria: Patients with osteoporotic vertebral fractures at the thoracolumbar level, with a follow-up period of at least 1

year and available clinical and radiological data were included in the study.

Exclusion criteria: Patients with high-energy traumas, treated with only vertebroplasty or kyphoplasty without instrumentation, history of malignancies, and patients with unfollowed were excluded from the study.

Patients diagnosed with thoracolumbar vertebral fractures and followed up conservatively were routinely treated with a thoracolumbar brace. They were allowed to walk using a walker while wearing a corset. Pain-relief medications such as nonsteroidal anti-inflammatory drugs and acetaminophen were provided to the patients for use as needed. A lower extremity exercise program was also conducted with the help of a physiotherapist. The patients were examined on the 2nd, 4th, and 6th weeks of their outpatient follow-up. Use of the corset was terminated at the 6th-week follow-up and these patients were re-examined at the 12th week. The success of the conservative treatment was evaluated by considering absence of neurological symptoms and pain relief in addition to fracture union. Surgical treatment was indicated for patients whose pain did not resolve after at least 3 months of conservative treatment and who experienced difficulty in walking.

Accordingly, the patients were divided into two groups: those who required surgical treatment due to the failure of conservative treatment (surgically treated group) and those who were successfully treated with conservative treatment (conservatively treated group).

The patients with failed conservative treatment consequently underwent posterior approach and pedicle screw instrumentation. A posterior longitudinal incision was made three levels above and below the fracture and long level fixation was performed at two or three levels above and below the fracture level.

Radiological Evaluation

We examined the computed tomography (CT) and lateral radiograph of the spine at the C7 vertebra and both hips. The CT images for all the patients were underwent in the standard position at the time of admission and after the surgical treatment in the tomography unit of our hospital. The radiographs of the patients were used to measure pelvic incidence (PI), pelvic tilt (PT), sacral slope (SS), lumbar lordosis (LL), thoracolumbar kyphosis (TLK), thoracic kyphosis (TK), T1 spinopelvic inclination (T1SPI), T9 spinopelvic inclination (T9SPI), T1 pelvic angle (TPA), and the distance from the center of the fractured vertebra to the plumb line (DSVA).

PI is the angle between the perpendicular line drawn at the sacral-end upper-plate midpoint and the line connecting the axis of the femoral head to this midpoint. PT is the line connecting the vertical line drawn from the femoral head axis and the sacral-end upper-plate midpoint from the femoral head axis. SS is the angle between the line drawn from the last upper sacral plate and the horizontal line drawn from the midpoint of the last upper sacral plate. LL is the Cobb angle between the L1 and S1 vertebrae upper endplates. TLK is the

Cobb angle between the T10 vertebra upper endplate and L2 vertebra lower endplate. TK is the Cobb angle between the T4 vertebra upper endplate and T12 vertebra lower endplate. T1SPI is the angle between the line drawn from the center of the T1 vertebra to the femoral head axis and vertical plumb line. T9SPI is the angle between the line drawn from the center of the T9 vertebra to the femoral head axis and vertical plumb line. TPA is the angle between the line drawn from the femoral head axis to the center of the T1 vertebra and the line drawn from the femoral head axis to the sacral-end upper plate. DSVA is the distance of the C7 plumb line from the center of the fractured vertebra. The farthest distance was measured in patients with multiple fractures. Sagittal balance (SB) is the distance from the vertical descending line at the center of the C7 vertebra to the posterior upper-plate posterosuperior corner of the S1 vertebral body. The distance of this line from the S1 vertebral body to the final upper-plate posterosuperior corner, 2.5 cm anteriorly and posteriorly, is considered a neutral SB. The distance of >2.5 cm anteriorly and posteriorly was considered positive and negative SB, respectively.

Fracture union was defined as the absence of movement in the fracture line on the radiographs captured during extension and flexion at 12th week visit control.

The psoas muscle was used to evaluate sarcopenia in the patients (4). Psoas lumbar vertebral index (PLVI) is a valid and easy measurement tool that has previously been reported in the literature. In the axial CT of the patients, the mean cross-sectional areas of the right and left psoas muscles at the L4 vertebra level and the ratio of the L4 vertebral body at the L4 pedicles level were calculated. L4 vertebral index values were determined, and the patients were divided into high and low categories according to their relationship with the cohort median.

Functional Evaluation

The visual analog scale (VAS) was used to measure the clinical outcomes of the surgical group.

Statistically Analyses

For the statistical analysis, SPSS software (Version 24.0; SPSS Inc., Chicago, IL, USA) was used. Descriptive statistical methods (mean, standard deviation, median, minimum, and maximum) were used to evaluate the study data. Normal distribution was tested by Shapiro–Wilk test. The patients were initially stratified into high versus low PLVI groups with a median value of 0.720 to identify baseline characteristic differences. The high PLVI cohort was defined as ≥ 0.720 and

low PLVI cohort was defined as < 0.720 . Student's t-test was used for the comparison of the quantitative data of the two groups that were normally distribution, and Mann–Whitney U test was used for the comparison of the data of the two groups that were not normally distribution. A paired samples t-test was used for the analysis of normally distributed dependent variables. Pearson chi-square test, Fisher Freeman Halton Exact test, and Fisher's Exact test were used to compare the qualitative data. P values < 0.05 were considered as statistically significant. Receiver operator characteristics curve (ROC) analysis was performed to obtain the optimal values for the radiological parameters.

RESULTS

Forty-three patients (21 females and 12 males) who met the criteria were included in the study. The mean age of the patients was 68.1 ± 7.4 (range, 60–86) years, mean time to surgery was 22.05 ± 12.42 (range, 10–52) weeks, and mean follow-up period was 22 ± 10 (range, 12–52) months after surgery (Table I).

In 20 patients, the 6-week thoracolumbar brace and medical treatments were successful, and these patients were able to return to their daily activities. Surgical intervention was performed in 23 patients with unresolved pain after at least 3 months of follow-up, gait disturbances, and nonunion (as observed on the radiographs).

In the 20 patients (13 females and 7 males) who were successfully treated with conservative treatment, the mean age was 67.4 years and mean follow-up period was 23.5 ± 6.1 (range, 14–36) months. Ten patients who were conservatively followed up had fractures at the T12 level, four had fractures at the T11–T12 level, and six had fractures at the L1 level.

The measurements of SB, DSVA, TLK, TK, T9SPI, TPA, and T1SPI showed significant differences between the two groups. However, no significant differences were observed in other sagittal parameters (Table II).

Among the conservatively treated group, 16 had neutral SB and 4 had positive SB. Sagittal imbalance was present in all the patients who required surgical treatment. Positive SB was noted in 18 patients and negative SB in 4. Neutral SB was achieved in 11 patients postoperatively.

The mean age of the 23 patients (18 females and 5 males) who underwent surgical treatment due to the failure of conservative treatment was 68.7 years and the mean follow-up period was 22.1 ± 10 (range, 12–35) months. Twelve patients had fractures

Table I: Demographic Data of All Patients

	Conservative Group (n=20)		Surgical Group (n=23)		p
	Mean \pm SD	Min – Max	Mean \pm SD	Min – Max	
Age, years	67.4 ± 7.5	60 – 85	68.8 ± 7.4	60 – 86	0.538
Gender, F/M	14/6		19/4		0.329
Follow-up, months	23.5 ± 6	12 – 36	22 ± 10	12 – 52	0.636

at the T12 level, nine had fractures at the T11–T12 level, and two had fractures at the L1 level. Posterior instrumentation was performed in all the patients. In addition, a cage was placed between the vertebral bodies due to vertebral collapse in four patients. By performing revision surgery, longer-level fusion was performed in 10 patients who had previously undergone short-level fusion due to adjacent segment degeneration and implant failure. Three of the patients who underwent revision surgery also had Parkinson's disease. Clinical improvement concerning preoperative walking difficulties was achieved in all the patients. The pain of the patients during the postoperative period was significantly reduced compared with that during

the preoperative period. The mean VAS scores significantly decreased from 7.78 ± 0.48 (6–9) to 2.32 ± 0.55 (0–3) in the final visit. The TLK and DSVA were significantly improved, however, the other parameters did not change (Table III) (Figure 1, 2).

ROC analysis demonstrated that the sensitivity and specificity of the DSVA for identifying high-risk patients for failed conservative treatment of osteoporotic thoracolumbar vertebral fractures were 100% and 95%, respectively, with an optimum diagnostic cutoff value of 6.5 mm (area under the ROC curve 0.999 95% confidence interval : 0.994–1.00) (Figure 3).

Table II: Comparison of Radiological Parameters Between Both Groups

	Conservative Group (n=20)		Surgical Group (n=23)		p
	Mean \pm SD	Min – Max	Mean \pm SD	Min – Max	
Pelvic Incidence, °	51.3 \pm 9.1	37 – 66	50.9 \pm 7.8	35 – 63	0.884
Pelvic Tilt, °	15.4 \pm 7.9	1 – 32	19.2 \pm 12.3	1 – 41	0.067
Sacral Slope, °	36.2 \pm 3.7	30 – 42	30.7 \pm 8.6	17 – 47	0.059
Lumbar Lordosis, °	43.2 \pm 8	34 – 62	45.8 \pm 19	5 – 70	0.656
Thoracolumbar kyphosis, °	22.7 \pm 7	8 – 32	41.1 \pm 20	4 – 80	0.026*
Thoracic kyphosis, °	29 \pm 7.3	18 – 45	40.8 \pm 20	4 – 85	0.001**
T1 spinopelvic inclination, °	3.1 \pm 2.4	1 – 12	5.62 \pm 4	0 – 14	0.034*
T9 spinopelvic inclination, °	5.7 \pm 3	1 – 15	13.5 \pm 7	0 – 25	0.001**
T1 pelvic angle, °	9.8 \pm 6.5	4 – 32	18,9 \pm 15	8 – 54	0.023*
DSVA, cm	4.01 \pm 1.5	2 – 7	11.04 \pm 3.2	7 – 18	0.001**
Sarcopenia, n	0		20		0.001**

DSVA: Distance from the center of the fractured vertebra to the plumb line, **cm:** centimeter. * $p < 0.05$ and ** $p < 0.001$

Table III: Comparison of Preoperative and Postoperative Radiological Parameters of Surgical Group

	Preoperative		Postoperative		p
	Mean \pm SD	Min – Max	Mean \pm SD	Min – Max	
Pelvic Incidence, °	50.9 \pm 7.8	35 – 63	50.6 \pm 7	32 – 64	0.669
Pelvic Tilt, °	19.2 \pm 12.3	1 – 41	19 \pm 6..6	5 – 29	0.992
Sacral Slope, °	30.7 \pm 8.6	17 – 47	31.8 \pm 5	20 – 41	0.568
Lumbar lordosis, °	45.8 \pm 19	5 – 70	49.4 \pm 7	37 – 63	0.445
Thoracolumbar kyphosis, °	41.1 \pm 20	4 – 80	22.6 \pm 12	1 – 39	0.001*
Thoracic kyphosis, °	40.8 \pm 20	4 – 85	39.3 \pm 8	21 – 52	0.775
T1 spinopelvic inclination, °	5.62 \pm 4	0 – 14	5.2 \pm 3	0 – 12	0.712
T9 spinopelvic inclination, °	13.5 \pm 7	0 – 25	12 \pm 4.5	3 – 20	0.502
T1 pelvic angle, °	18,9 \pm 15	8 – 54	15 \pm 6	6 – 33	0.208
DSVA, cm	11.04 \pm 3.2	7 – 18	6.4 \pm 2	3 – 11	0.001*

SD: Standard deviation, **Min:** Minimum, **Max:** Maximum; **cm:** centimeter. * $p < 0.05$ and ** $p < 0.001$.

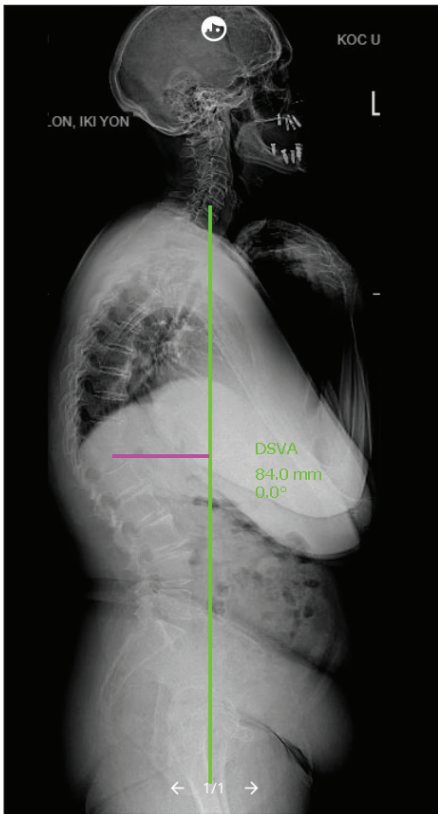


Figure 1: The preoperative distance from the center of the fractured vertebra to the plumb line was more than 65 mm in the patients with failed conservative management who were consequently treated with posterior instrumentation.

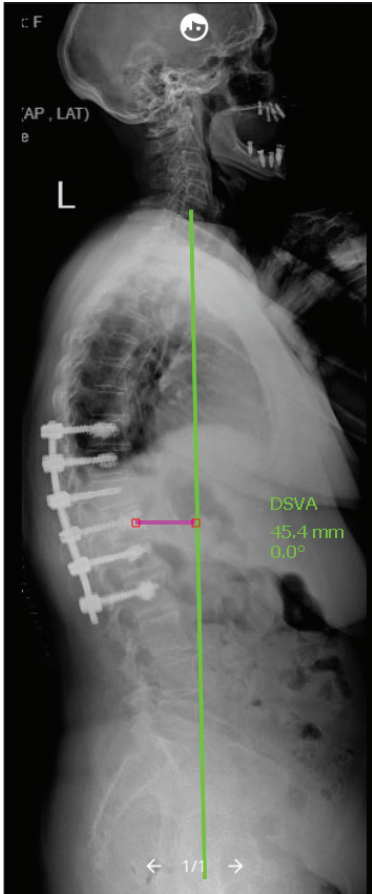


Figure 2: Postoperative lateral spinal radiographs; sagittal balance showed improvement after surgery.

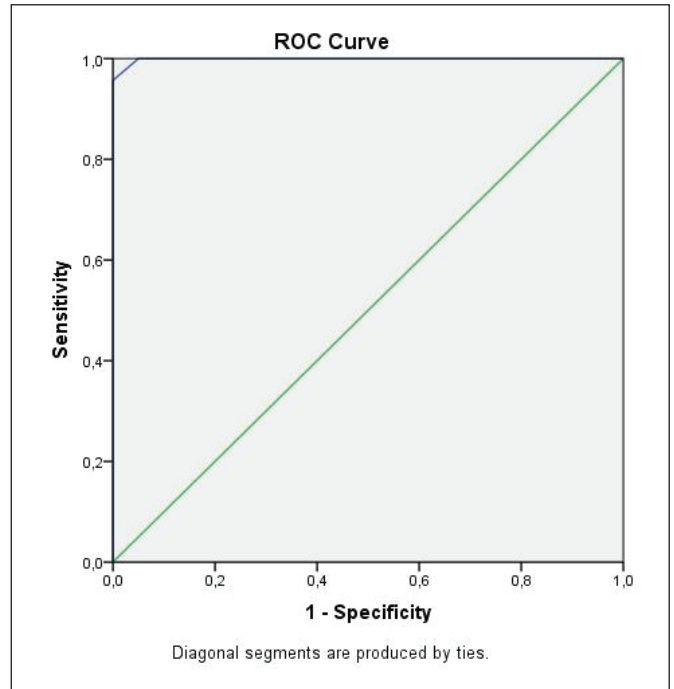


Figure 3: Receiver operating characteristic analysis of distance from the center of the fractured vertebra to the plumb line.

DISCUSSION

Although numerous studies in the existing literature report on osteoporotic vertebral fractures, there is no consensus on the criteria to be used for surgical treatment. Lee et al. stated that osteoporotic fractures cannot be prevented, and the important issue in such cases is to minimize potential complications (12). Predicting the complications that may be caused by conservative treatment and deciding which surgical treatment interventions should be performed in patients constitute the main aspects of the treatment approach for osteoporotic vertebral fractures. Our study is important in terms of demonstrating the risk factors of unsuccessful conservative treatment for osteoporotic fractures in the thoracolumbar region.

Most osteoporotic fractures occur in the thoracolumbar region. The thoracolumbar region is the area that carries the greatest dynamic load in the entire spine, making it prone to fracture nonunion (8). A systematic study examining the reasons for the failure of conservative treatment reported that fractures in the thoracolumbar region have a high risk of developing both pseudoarthrosis and kyphotic deformity (14). Because of the difference in their biomechanical properties, the treatment approaches utilized for fractures in the thoracolumbar transition region should be different from those utilized for fractures in other parts of the spine. For this reason, only fractures in the thoracolumbar region were included in our study.

The objective of conservative treatment of an osteoporotic vertebral fracture is to relieve the patient’s pain, provide early mobilization, and prevent new fractures. A meta-analysis by Gua et al. compared the efficacy and safety of conservative

and surgical treatments for osteoporotic vertebral fractures and demonstrated that surgical treatment was more effective in reducing pain; however, no significant differences in the quality of life of patients in the medium and long terms between the two treatment approaches was observed (7). In fact, treatment success depends on several factors. Our study results indicate SB, DSVa, TLK, TK, T9SPI, T1SPI, and sarcopenia as risk factors for unsuccessful conservative treatment.

One of the main purposes of treatment of osteoporotic vertebral fracture is to provide union and relief pain. Sagittal imbalance may impair union by increasing the load on the fracture line. In a study investigating the effects of SB disorder on fracture union in patients with osteoporotic vertebrae, the effect of the distance from the C7 plumb line to the fracture union site on the fracture union was investigated (9). This study showed that this distance was significantly greater among patients with osteoporotic vertebral fractures who developed vertebral collapse than in patients without collapse (15). Yet another study reported that a distance of >5 cm of the C7 plumb line from the center of the fractured vertebra is a risk factor for nonunion (9). In our study, this distance was 4.01 cm in the conservatively treated group and 11.02 cm in the surgically treated group. Sagittal imbalance was present in all the patients who required surgical treatment. TLK was significantly higher in the surgically treated group than in the conservatively treated group.

Fractures may not heal completely in approximately 15%–35% of conservatively treated patients (16). Percutaneous vertebral cementing techniques can be performed in patients with severe pain who do not respond to conservative treatment. Previous studies have indicated that patients undergoing vertebroplasty have better clinical and radiological outcomes compared to those treated conservatively (13,19). Although percutaneous interventions contribute to pain relief and correct local kyphosis at the fracture line, their effects on SB are limited. Kanayama et al. reported on the results of a mean 36-month follow-up of 56 patients diagnosed with osteoporotic vertebral fractures and treated with kyphoplasty. The results showed that although the pain of the patients decreased with kyphoplasty, there was no improvement in their global sagittal alignment (10). Percutaneous interventions were not preferred owing to their limited effects on SB correction in patients undergoing surgical treatment.

Sarcopenia is a syndrome characterized by a decrease in muscle volume and mass. Bone and muscle tissue are closely related owing to their chemical and metabolic properties. The strongest mechanical forces on bones are generated by muscle contractions (18). Therefore, any decrease in muscle strength and function increases the risk of osteoporosis. A study reported sarcopenia to be a determinant of mortality in patients with osteoporotic vertebral fractures (1). In our study, 10 patients from the sarcopenic group underwent revision surgery. Spinal instrumentation techniques should be applied in geriatric patients with spinal instability, vertebral column collapse, neurological deficits, kyphotic deformities,

and pseudoarthrosis. In patients with osteoporosis, adequate fixation may not be achieved in the pedicle screws due to the loss of bone structure. One of the most practical ways to increase pedicle screw stability is by using pedicle screws along with polymethyl methacrylate (6,17). In this study, cemented screws were used in 11 patients in whom insufficient screw stability was observed during surgery.

■ CONCLUSION

Because of the difference in their biomechanical properties, the treatment approaches utilized for fractures in the thoracolumbar transition region should be performed more carefully and with close follow-ups. In this study, we investigated the factors that influence the failure of conservative treatment of osteoporotic thoracolumbar vertebral fractures. Sarcopenia and the DSVa were significantly higher in the surgically treated group who underwent operation following the failure of the conservative method. ROC analysis demonstrated that the sensitivity and specificity of the DSVa for identifying patients at a high risk of failed conservative treatment of osteoporotic thoracolumbar vertebral fractures were 100% and 95%, respectively, with an optimum diagnostic cutoff value of 6.5 mm.

■ ACKNOWLEDGEMENT

The authors would like to thank Enago (www.enago.com) for the English language review.

■ AUTHORSHIP CONTRIBUTION

Study conception and design: MAO, SB

Data collection: MAO, SK

Analysis and interpretation of results: MK, IS

Draft manuscript preparation: SB, MK, TA

Critical revision of the article: SS and TA

All authors (MAO, SB, SK, MK, IS, SS, TA) reviewed the results and approved the final version of the manuscript.

■ REFERENCES

1. Bayram S, Akgul T, Adiyaman AE, Karalar S, Dolen D, Aydoseli A: Effect of sarcopenia on mortality after percutaneous vertebral augmentation treatment for osteoporotic vertebral compression fractures in elderly patients: A retrospective cohort study. *World Neurosurg* 138:e354–e360, 2020
2. Chapman J, Smith JS, Kopjar B, Vaccaro AR, Arnold P, Shaffrey CI, Fehlings MG: The AOSpine North America geriatric odontoid fracture mortality study: A retrospective review of mortality outcomes for operative versus nonoperative treatment of 322 patients with long-term follow-up. *Spine (Phila Pa 1976)* 38:1098–1104, 2013
3. Cosman F, de Beur SJ, LeBoff MS, Lewiecki EM, Tanner B, Randall S, Lindsay R: National Osteoporosis Foundation. Clinician's guide to prevention and treatment of osteoporosis. *Osteoporos Int* 25:2359–2381, 2014

4. Ebbeling L, Grabo DJ, Shashaty M, Dua R, Sonnad SS, Sims CA, Pascual JL, Schwab CW, Holena DN: Psoas: Lumbar vertebra index: Central sarcopenia independently predicts morbidity in elderly trauma patients. *Eur J Trauma Emerg Surg* 40:57-65, 2014
5. Ettinger B, Black DM, Nevitt MC, Rundle AC, Cauley JA, Cummings SR, Genant HK: Contribution of vertebral deformities to chronic back pain and disability. The study of osteoporotic fractures research group. *J Bone Miner Res* 7:449-456, 1992
6. Frankel BM, D'Agostino S, Wang C: A biomechanical cadaveric analysis of polymethylmethacrylate-augmented pedicle screw fixation. *J Neurosurg Spine* 7:47-53, 2007
7. Guo JB, Zhu Y, Chen BL, Xie B, Zhang WY, Yang YJ, Yue YS, Wang XQ: Surgical versus non-surgical treatment for vertebral compression fracture with osteopenia: A systematic review and meta-analysis. *PLoS One* 10: e0127145, 2015
8. Ismail AA, Cooper C, Felsenberg D, Varlow J, Kanis JA, Silman AJ, O'Neill TW: Number and type of vertebral deformities: epidemiological characteristics and relation to back pain and height loss. European vertebral osteoporosis study group. *Osteoporos Int* 9:206-213, 1999
9. Iwata A, Kanayama M, Oha F, Hashimoto T, Iwasaki N: Does spinopelvic alignment affect the union status in thoracolumbar osteoporotic vertebral compression fracture? *Eur J Orthop Surg Traumatol* 27:87-92, 2017
10. Kanayama M, Oha F, Iwata A, Hashimoto T: Does balloon kyphoplasty improve the global spinal alignment in osteoporotic vertebral fracture? *Int Orthop* 39:1137-1143, 2015
11. Kanis JA, Melton LJ 3rd, Christiansen C, Johnston CC, Khaltaev N: The diagnosis of osteoporosis. *J Bone Miner Res* 9:1137-1141, 1994
12. Lee YL, Yip KM: The osteoporotic spine. *Clin Orthop Relat Res* 323:91-97, 1996
13. Martikos K, Greggi T, Faldini C, Vommaro F, Scarale A: Osteoporotic thoracolumbar compression fractures: Long-term retrospective comparison between vertebroplasty and conservative treatment. *Eur Spine J* 27:244-247, 2018
14. Muratore M, Ferrera A, Masse A, Bistolfi A: Osteoporotic vertebral fractures: Predictive factors for conservative treatment failure. A systematic review. *Eur Spine J* 27:2565-2576, 2018
15. Ohnishi T, Iwata A, Kanayama M, Oha F, Hashimoto T, Iwasaki N: Impact of spino-pelvic and global spinal alignment on the risk of osteoporotic vertebral collapse. *Spine Surg Relat Res* 2:72-76, 2018
16. Rajasekaran S, Kanna RM, Schnake KJ, Vaccaro AR, Schroeder GD, Sadiqi S, Oner C: Osteoporotic thoracolumbar fractures-how are they different? Classification and treatment algorithm. *J Orthop Trauma* 31:S49-S56, 2017
17. Shea TM, Laun J, Gonzalez-Blohm SA, Doulgeris JJ, Lee WE 3rd, Aghayev K, Vrionis FD: Designs and techniques that improve the pullout strength of pedicle screws in osteoporotic vertebrae: Current status. *Biomed Res Int* 2014:748393, 2014
18. Wang WF, Lin CW, Xie CN, Liu HT, Zhu MY, Huang KL, Teng HL: The association between sarcopenia and osteoporotic vertebral compression refractures. *Osteoporos Int* 30:2459-2467, 2019
19. Yi HJ, Jeong JH, Im SB, Lee JK: Percutaneous vertebroplasty versus conservative treatment for one level thoracolumbar osteoporotic compression fracture: Results of an over 2-year follow-up. *Pain Physician* 19:E743-E750, 2016