

Surgical Treatment of Spinal Arachnoid Cysts: Cyst Excision or Fenestration?

Ali Fatih RAMAZANOGLU, Caner SARIKAYA, Eyup VAROL, Serdar Onur AYDIN, Mustafa Umut ETLI, Furkan AVCI, Sait NADERI

Umraniye Training and Research Hospital, Department of Neurosurgery, Istanbul, Turkey

Corresponding author: Mustafa Umut ETLI ✉ umutetli@gmail.com

ABSTRACT

AIM: To examine a series of surgically treated spinal arachnoid cysts in light of the literature.

MATERIAL and METHODS: This was a retrospective study of patients treated in the Istanbul Umraniye Training and Research Hospital Neurosurgery Clinic. A total of 18 patients with spinal arachnoid cysts underwent surgical treatment between January 2012 and December 2019. All patients were assessed before and after surgery for muscle strength, pain, sensory changes, and bowel-bladder symptoms. All patients underwent magnetic resonance imaging and computed tomography for diagnosis and treatment.

RESULTS: Among the 18 patients, 8 were men and 10 were women, with a mean age of 43.7 (25–66) years. Congenital conditions were discovered in 15 of the patients, 2 after lumbar drainage and 1 after spinal anesthesia. Intradural extramedullary and intradural cysts were found in 17 patients and 1 patient, respectively. The cyst was smaller than level 3 in 14 patients and greater than level 3 in 4 patients. Cyst excision and cyst fenestration were performed in 11 and 7 patients, respectively. Cyst excision was performed in four of the patients who underwent cyst fenestration because their complaints did not improve.

CONCLUSION: Surgery should be considered in patients with symptomatic spinal arachnoid cysts. Fenestration may be a suitable alternative, especially if magnetic resonance imaging reveals no intracystic adhesion or trabeculation. Residual and recurrence rates are high in patients with a history of intradural intervention, adhesions, or trabeculation. When there is trabeculation, the best option is cyst removal.

KEYWORDS: Spinal, Arachnoidal cyst, Cyst fenestration, Cyst excision

ABBREVIATIONS: CSF: Cerebrospinal fluid, MRI: Magnetic resonance imaging, VAS: Visual analog score

INTRODUCTION

Arachnoid cysts in the spinal canal account for 1%–3% of all spinal canal lesions. Congenital, secondary to earlier trauma, infection, or iatrogenic (post-lumbar puncture or post-surgical) reasons can all induce spinal arachnoid cysts (8,21,29). The mechanism of cyst formation remains unknown. Although the majority of cysts are congenital, they can also develop secondary to trauma, infection, inflammation, iatrogenic, or idiopathic reasons (8,21,31). The formation of spinal arachnoid cysts has been the subject of several hypotheses

(7,23). Basically, cysts are thought to occur as a result of herniation of the arachnoid tissue. Exercises that raise intracranial pressure and cerebrospinal fluid (CSF) flow promote the growth of spinal arachnoid cysts. Several theories have been presented regarding enlargement of cysts. One is that these cysts and the subarachnoid space are connected by a one-way valve and that a rise in intraspinal pressure increases the flow of CSF into the cyst, causing the cyst to grow (20). Another theory is that increased intracranial pressure can expand the cyst by increasing the volume of CSF that enters it (2).

Ali Fatih RAMAZANOGLU  : 0000-0001-6500-5070
Caner SARIKAYA  : 0000-0002-2325-3903
Eyup VAROL  : 0000-0002-3135 849X

Serdar Onur AYDIN  : 0000-0002-6698-4685
Mustafa Umut ETLI  : 0000-0003-0756-4274
Furkan AVCI  : 0000-0002-2485-8672

Sait NADERI  : 0000-0002-6784-4270

Spinal arachnoid cysts are generally asymptomatic, but symptomatic ones may be accompanied by complaints of pain, motor weakness, urinary incontinence, myelopathy, and sensory changes due to the mass effect and root compression (6,15,31). Nabor et al. described the classification commonly used in spinal arachnoid cysts: Type 1 cysts are extradural cysts without nerve root involvement, Type 2 cysts are extradural cysts with nerve root involvement, and Type 3 cysts are intradural meningeal cysts (21). There is no consensus on surgical treatment yet. Cystoperitoneal shunt, fenestration of the spinal arachnoid cyst (30), or total resection are among the preferred methods (32).

This study aimed to examine a series of surgically treated spinal arachnoid cysts in light of the literature.

■ MATERIAL and METHODS

This study was conducted retrospectively in the Istanbul Umraniye Training and Research Hospital Neurosurgery Clinic. A total of 18 patients with spinal arachnoid cysts who had undergone surgical treatment between January 2012 and December 2019 were included. All patients were assessed before and after surgery for muscle strength, pain, sensory changes, and bowel-bladder symptoms. All patients underwent magnetic resonance imaging and computed tomography for diagnosis and treatment. The patients were contacted 7 days and 6 months after surgery for a neurological examination and to assess complications. In the pain evaluations, a Visual Analog Score (VAS) was applied. VAS was questioned during the initial admission and follow-up examinations and reviewed retrospectively from the review charts.

Surgical Technique

Two different techniques were applied depending on the patient's condition. Hemilaminectomy was performed in the upper and lower segments. The upper and lower poles of the cyst were located, cysts were opened, and fenestration with the subarachnoid space was performed in patients in which the cyst was longer than the third level. A tiny catheter was then used to check the fenestration of the cyst wall and CSF passage. The dura was closed. In patients in which the cyst had fewer segments, the cyst was revealed and completely removed by performing a hemilaminectomy and durotomy. Intraoperative monitoring was used in all cases to evaluate the patients' neurological condition during the surgery.

■ RESULTS

Eight of the 18 patients were men and 10 were women, with a mean age of 43.7 (25–66) years. Congenital conditions were discovered in 15 of the patients, 2 after lumbar drainage and 1 after spinal anesthesia. Seventeen individuals had intradural extramedullary cysts, and one patient had an intra-extradural cyst. Among the cysts, three were cervical, nine were thoracic, four were lumbar, one was thoracolumbar, and one was lumbosacral. The cysts were smaller than level 3 in 14 patients and greater than level 3 in 4 patients. The patient data are summarized in Table I.

Pain was the primary complaint of 12 patients in the preoperative period, weakness in 4 patients, and urinary incontinence in 2 patients. The symptoms of the patients who complained of motor deficit and urinary incontinence improved at the 6th month postoperatively. While the mean preoperative VAS score was 7.2 (9–6), the mean postoperative VAS score was 3.4 (5–1) (Figures 1 and 2).

Cyst excision and cyst fenestration were performed in 11 and 7 patients, respectively. Four of the patients who had cyst fenestration had their cysts removed because their complaints did not improve. The mean follow-up period after surgery was 5 years (range: 245–523 days). CSF fistula complication was observed in two patients who underwent cyst excision after surgery.

In the preoperative radiological evaluation, myelopathy was observed in 2 patients and the syrinx was observed in 5 patients. In the postoperative period, myelopathy decreased

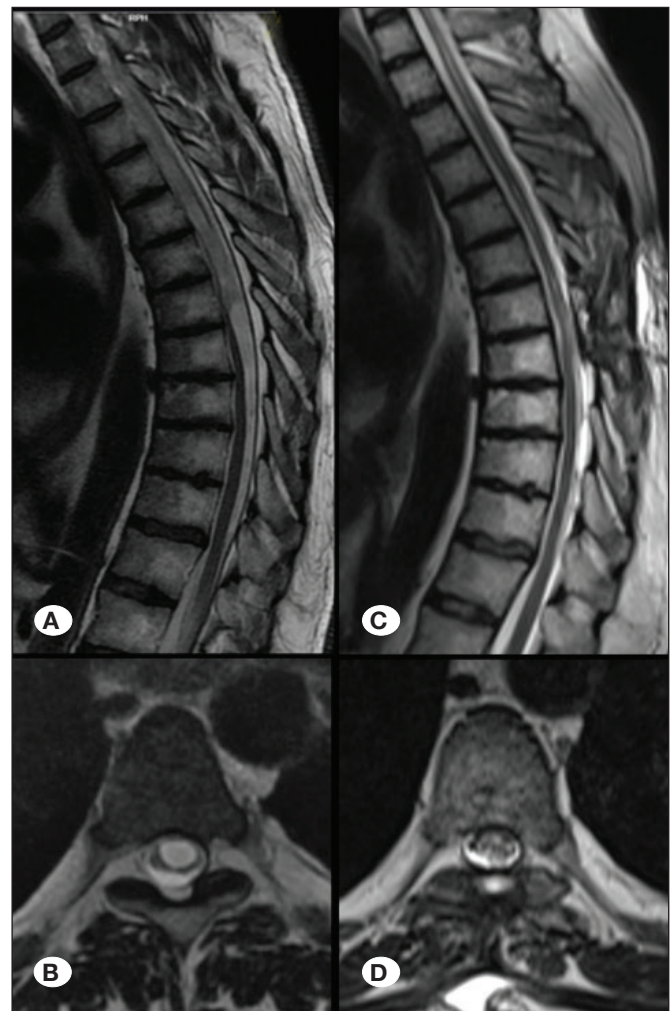


Figure 1: Case Sample 1: Preoperative sagittal (A) and axial (B) T2 MRI images of an arachnoidal cyst on thoracic level. 1st-year postoperative sagittal (C) and axial (D) T2 MRI images revealed complete excision of the cyst. It was observed that the syrinx decreased postoperatively.

Table I: Demonstration of Aetiology, Extent, Anatomical Location, Treatment, Recurrent Surgery and Complication of Operated Arachnoid Cyst Patients

Case Number	Aetiology	Elongation	Localization	Treatment	Recurrence 2 nd surgery	Complication
1	Congenital	T1-2	Intra-extradural	Resection-Ligation	Cyst Excision	
2	Congenital	T1-2	Intradural	Cyst Excision		
3	Congenital	T10-12	Intradural	Cyst Fenestration		
4	Congenital	L1-5	Intradural	Cyst Fenestration	Cyst Excision	
5	Congenital	C1-5	Intradural	Cyst Fenestration	Cyst Excision	
6	Congenital	T7-8	Intradural	Cyst Excision		
7	Congenital	L4-5	Intradural	Cyst Excision		
8	Congenital	T2-6	Intradural	Cyst Fenestration		
9	Congenital	C2-3	Intradural	Cyst Excision		
10	Congenital	T12-L2	Intra-extradural	Resection-Ligation		CSF fistula
11	Congenital	T5-6	Intra-extradural	Resection-Ligation		CSF fistula
12	Congenital	T4-9	Intradural	Cyst Fenestration	Cyst Excision	
13	After Lumbar Drainage	L3-4	Intradural	Cyst Excision		
14	Congenital	S1-2	Intradural	Cyst Fenestration		
15	After Spinal Anesthesia	T5-6	Intradural	Cyst Excision		
16	Congenital	T5-8	Intradural	Cyst Excision		
17	Congenital	C1-2	Intradural	Cyst Excision		
18	After Lumbar Drainage	L2-3	Intradural	Cyst Excision		

in 1 of the patients with myelopathy and remained the same in 1. The syrinx decreased in 4 of the patients with a syrinx and remained the same in 1.

■ DISCUSSION

The study results demonstrated that cyst excision was very efficient in the treatment of arachnoid cysts, the complication rate was minimal, and the fenestration operation failed in 57% (4/7) of the patients and required total excision. Spinal arachnoid cysts are rare lesions, so they only appear in limited series in the literature (1,2,4,11,21,22,24,26). Although these cysts can appear anywhere in the spine, they are typically found in the thoracic area, particularly in the posterior and posterior-lateral spinal cord. In the series of Cloward, 65% of the cysts were in the thoracic region (5), and in the series of Kriss and Kriss, 80% were in the thoracic region (14). It is thought that those findings were because the thoracic region has a long segment and a narrow diameter, which causes the symptoms induced by the mass effect on the spinal cord to occur earlier (2). In our series, 50% (9/18) of the cysts were

located in the thoracic region. Because of the postoperative problems induced by multi-level laminectomy in a kyphotic region, such as the thoracic region, it is essential to perform multi-level hemilaminectomy (13,19) or laminoplasty instead of total laminectomy in surgery (33). In our dataset, total laminectomy was performed in the first 4 patients requiring total excision, whereas hemilaminectomy was performed in the remaining 14.

Both intradural and extradural spinal arachnoid cysts can occur. Extradural (Types 1 and 2) arachnoid cysts were more common than intradural cysts in some studies (9,18). In some selected series, however, intradural arachnoid cysts were reported to be more common (2). Spinal arachnoid cysts are most commonly located in the posterior and posterior-lateral regions of the spinal cord. In our series, only one patient had an intradural-extradural cyst, which was probably because the intradural arachnoid defect was located in a certain region. It is critical to anticipate such a potential circumstance during the preoperative phase by performing a thorough magnetic resonance imaging (MRI) evaluation and make appropriate

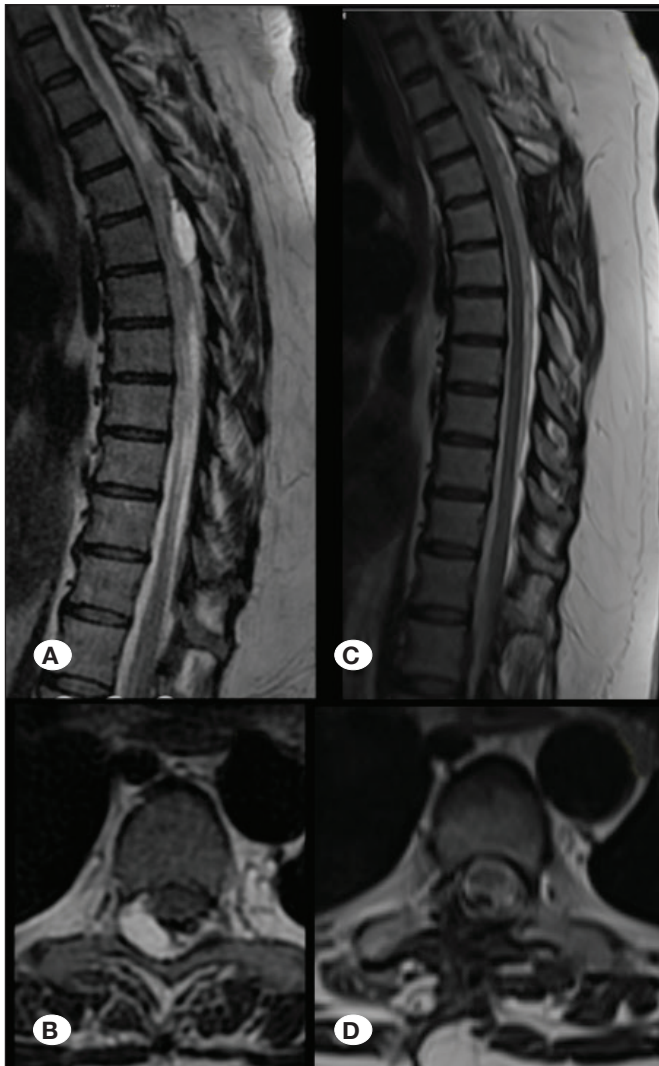


Figure 2: Case Sample 2: Preoperative sagittal (A) and axial (B) T2 MRI images of an arachnoid cyst on thoracic level. 1st-year postoperative sagittal (C) and axial (D) T2 MRI images revealed complete excision of the cyst.

plans. In these cases, fenestration does not work, so it is obligatory to open the cyst in all segments and perform the procedure. Although conservative management of patients with incidental or asymptomatic spinal arachnoid cysts can be effective, symptomatic spinal arachnoid cysts require surgical treatment. Cyst resection, cyst fenestration (10,24,28), and cystoperitoneal shunting are recommended procedures (2,3).

The diagnosis and location of an intradural arachnoid cyst during surgery and the use of intraoperative ultrasound to confirm the diagnosis are important (31). In our study, ultrasonography was performed for every patient who had a total cyst excision. In the literature, many series of successful fenestration results in the treatment of spinal arachnoid cysts have been documented. After 14 cyst fenestrations and partial resections performed by Viswanathan et al., there was an average increase of 2 points (1.3–3 and 1.3–3.0, respectively;

$p < 0.001$) in the modified Japanese Orthopaedic Association scale score of the patients. Postoperative MRIs of the patients revealed a decrease in the syrinx and an enlargement of the spinal cord (30). By decompressing the spinal cord, fenestration, and cyst wall excision help alleviate myelopathy symptoms.

In patients in which fenestration was performed, symptoms improved for a brief period before returning. In a study by Kumar et al., cysts were found to deflate quickly after surgical puncture and then enlarge again a few minutes later (16). These findings following intraoperative fenestration revealed that the osmotic pressure differential was effective in cyst formation, confirming that the fluid in the cyst keeps it from coming out through the valve mechanism, as reported by Rohrer et al (25). In our study, four of seven patients who received fenestration had to have it repeated because their symptoms persisted, and trabeculated cysts were found in all of them. Total excision helped these patients.

Indeed, our literature review showed that trabeculation and adhesions were present in patients with postinfectious or iatrogenic (spinal anesthesia, lumbar puncture, lumbar drainage) causes and idiopathic arachnoid cysts (10,12,17,27). Adhesions, in contrast, were observed in some cases that were thought to be idiopathic. Therefore, in patients with suspected adhesions, total cyst excision at the fenestration location appeared to be preferable when considering surgery.

■ CONCLUSION

Surgery should be considered for symptomatic spinal arachnoid cysts. Fenestration may be a suitable alternative, especially if an MRI examination reveals no intracystic adhesion or trabeculation. Residual and recurrence rates are high in patients with a history of intradural intervention, adhesions, and trabeculation. When there is trabeculation, the best option is cyst removal.

■ AUTHORSHIP CONTRIBUTION

Study conception and design: AFR

Data collection: CS

Analysis and interpretation of results: EV, SOA

Draft manuscript preparation: MUE, FA

Critical revision of the article: MUE

Other (study supervision, fundings, materials, etc...): SN

All authors (AFR, CS, EV, SOA, MUE, FA, SN) reviewed the results and approved the final version of the manuscript.

■ REFERENCES

1. Alvisi C, Cerisoli M, Giulioni M, Guerra L: Long-term results of surgically treated congenital intradural spinal arachnoid cysts. *J Neurosurg* 67:333-335, 1987
2. Bond AE, Zada G, Bowen I, McComb JG, Krieger MD: Spinal arachnoid cysts in the pediatric population: Report of 31 cases and a review of the literature. *J Neurosurg Pediatr* 9:432-441, 2012

3. Carrillo R: Lumbar cerebrospinal fluid drainage for symptomatic sacral nerve root cysts: An adjuvant diagnostic procedure and/or alternative treatment? Technical case report. *Neurosurgery* 42:952-953, 1998
4. Cilluffo JM, Gomez MR, Reese DF, Onofrio BM, Miller RH: Idiopathic ("congenital") spinal arachnoid diverticula. Clinical diagnosis and surgical results. *Mayo Clin Proc* 56:93-101, 1981
5. Cloward RB: Congenital spinal extradural cysts: Case report with review of literature. *Ann Surg* 168:851-864, 1968
6. Duncan AW, Hoare RD: Spinal arachnoid cysts in children. *Radiology* 126:423-429, 1978
7. Fortuna A, La Torre E, Ciappetta P: Arachnoid diverticula: A unitary approach to spinal cysts communicating with the subarachnoid space. *Acta Neurochir (Wien)* 39:259-268, 1977
8. Garg K, Borkar SA, Kale SS, Sharma BS: Spinal arachnoid cysts - our experience and review of literature. *Br J Neurosurg* 31:172-178, 2017
9. Goyal A, Singh AK, Singh D, Gupta V, Tatke M, Sinha S, Kumar S: Intramedullary arachnoid cyst. Case report. *J Neurosurg* 96:104-106, 2002
10. Kazan S, Ozdemir O, Akyuz M, Tuncer R: Spinal intradural arachnoid cysts located anterior to the cervical spinal cord. Report of two cases and review of the literature. *J Neurosurg* 91:211-215, 1999
11. Kendall BE, Valentine AR, Keis B: Spinal arachnoid cysts: Clinical and radiological correlation with prognosis. *Neuroradiology* 22:225-234, 1982
12. Kong WK, Cho KT, Hong SK: Spinal extradural arachnoid cyst: A case report. *Korean J Spine* 10:32-34, 2013
13. KrishnanKutty R, Sreemathyamma SB, Sivanandapanicker JL, Asher P, Prabhakar RB, Peethambaran A: Hemilaminectomy for spinal cord intradural tumors: An institutional experience. *Asian J Neurosurg* 13:760-765, 2018
14. Kriss TC, Kriss VM: Symptomatic spinal intradural arachnoid cyst development after lumbar myelography. Case report and review of the literature. *Spine (Phila Pa 1976)* 22:568-572, 1997
15. Krstacic A, Krstacic G, Butkovic Soldo S: Atypical cause of radiculopathy - Intradural spinal arachnoid cyst. *Acta Clin Belg* 71:267-268, 2016
16. Kumar A, Sakia R, Singh K, Sharma V: Spinal arachnoid cyst. *J Clin Neurosci* 18:1189-1192, 2011
17. Lee HJ, Cho DY: Symptomatic spinal intradural arachnoid cysts in the pediatric age group: description of three new cases and review of the literature. *Pediatr Neurosurg* 35:181-187, 2001
18. Lee TT, Alameda GJ, Gromelski EB, Green BA: Outcome after surgical treatment of progressive posttraumatic cystic myelopathy. *J Neurosurg* 92:149-154, 2000
19. Mazel C, Balabaud L, Bennis S, Hansen S: Cervical and thoracic spine tumor management: Surgical indications, techniques, and outcomes. *Orthop Clin North Am* 40:75-92, vi-vii, 2009
20. McCrum C, Williams B: Spinal extradural arachnoid pouches. Report of two cases. *J Neurosurg* 57:849-852, 1982
21. Nabors MW, Pait TG, Byrd EB, Karim NO, Davis DO, Kobrine AI, Rizzoli HV: Updated assessment and current classification of spinal meningeal cysts. *J Neurosurg* 68:366-377, 1988
22. Osenbach RK, Godersky JC, Traynelis VC, Schelper RD: Intradural extramedullary cysts of the spinal canal: Clinical presentation, radiographic diagnosis, and surgical management. *Neurosurgery* 30:35-42, 1992
23. Perret G, Green D, Keller J: Diagnosis and treatment of intradural arachnoid cysts of the thoracic spine. *Radiology* 79:425-429, 1962
24. Rabb CH, McComb JG, Raffel C, Kennedy JG: Spinal arachnoid cysts in the pediatric age group: An association with neural tube defects. *J Neurosurg* 77:369-372, 1992
25. Rohrer DC, Burchiel KJ, Gruber DP: Intraspinal extradural meningeal cyst demonstrating ball-valve mechanism of formation. Case report. *J Neurosurg* 78:122-125, 1993
26. Santamarta D, Morales F, Sierra JM, de Campos JM: Arachnoid cysts: Entrapped collections of cerebrospinal fluid variably communicating with the subarachnoid space. *Minim Invasive Neurosurg* 44:128-134, 2001
27. Suryaningtyas W, Arifin M: Multiple spinal extradural arachnoid cysts occurring in a child. Case report. *J Neurosurg* 106:158-161, 2007
28. Tarlov IM: Spinal perineurial and meningeal cysts. *J Neurol Neurosurg Psychiatry* 33:833-843, 1970
29. Turel MK, Kerolus MG, Deutsch H: Intradural spinal arachnoid cyst - A complication of lumbar epidural steroid injection. *Neurol India* 65:863-864, 2017
30. Viswanathan VK, Manoharan SR, Do H, Minnema A, Shaddy SM, Elder JB, Farhadi HF: Clinical and radiologic outcomes after fenestration and partial wall excision of idiopathic intradural spinal arachnoid cysts presenting with myelopathy. *World Neurosurg* 105:213-222, 2017
31. Wang MY, Levi AD, Green BA: Intradural spinal arachnoid cysts in adults. *Surg Neurol* 60:49-55, 2003
32. Woo JB, Son DW, Kang KT, Lee JS, Song GS, Sung SK, Lee SW: Spinal extradural arachnoid cyst. *Korean J Neurotrauma* 12:185-190, 2016
33. Zhuo H, Zhou Y, Chai X, Chang Q, Rao G: The application of ultrasonic bone curette in laminoplasty of spinal canal after resection of intraspinal tumors. *Zhongguo Xue Fu Chong Jian Wai Ke Za Zhi* 33:61-65, 2019