

The Effect of the Vertebral Artery Stenosis on the Basilar Artery Tortuosity

Hamza SAHIN¹, Mustafa GOKCE²

¹Kahramanmaraş Sutcu Imam University, Faculty of Medicine, Department of Neurology, Kahramanmaraş, Turkey

²Akhmet Yassawi University, Stroke Section, Turkestan, Kazakhstan

Corresponding author: Hamza SAHIN ✉ hamzasahin85@hotmail.com

ABSTRACT

AIM: The aim of the present study was to investigate the effect of vertebral artery stenosis (VAS) on the basilar artery tortuosity.

MATERIAL and METHODS: A total of 158 patients (101 males; 57 females) were divided into two main groups depending on existence of the in the vertebral artery (VA). Then, these groups were divided into two sub-groups according to the stenosis severity. All these groups were compared via the following variables: the gender, age, stroke risk factors, and basilar artery deflection angle.

RESULTS: The dominant VA was found more common on the left side; and most of the cases had an adverse directional correlation between the side of the dominant VA and basilar artery bending ($p= 0.002$). It was noticed that the mean value of the basilar artery deflection angle was higher in the patients with a VA stenosis rate below 70%. In the left VA, hypertension was found higher in the patients with VAS (92.3%, $p= 0.012$). Furthermore, C-shaped ($n=63$, 43%) was the most observing morphological change in the basilar artery (BA).

CONCLUSION: Consequently, this study suggests that the VA stenosis below 70% may contribute to the BA tortuosity by affecting asymmetric VA flow.

KEYWORDS: Asymmetric flow, Bending side, Deflection angle, Dominant vertebral artery

ABBREVIATIONS: BA: Basilar artery, BADA: Basilar artery deflection angle, Co-DVA: Co-dominant vertebral artery, CTA: Computed tomographic angiography, DSA: Digital subtraction angiography, DVA: Dominant vertebral artery, MRA: Magnetic resonance angiography, TIA: Transient Ischemic Attack, VAS: Vertebral artery stenosis, VBJ: Vertebro-basilar junction

INTRODUCTION

In the United States, stroke ranks as the fifth leading cause of death, and it affects approximately 795,000 people per year. The majority of the stroke cases is ischemic (87%), and only 15% to 20% of ischemic strokes are associated with posterior circulation (1-3). Posterior circulation infarcts have a higher mortality rate (86%) despite lower prevalence (1,4).

Posterior circulation is provided mainly by the basilar artery, and the two vertebral arteries form the BA at the vertebro-basilar junction (VBJ). There are various arterial variations at the VBJ; however, the causes of the variations have not been completely elucidated. One of the vertebral arteries commonly

has a larger diameter, and it is reported as the dominant VA (1,5-10). Furthermore, it is suggested that an asymmetric VA flow caused by the dominant VA may induce morphological consequences in the basilar artery such as BA elongation or bending.

Previous studies demonstrate that elongation or bending of the basilar artery is commonly observed in normal subjects by magnetic resonance angiography (11). Some other studies indicate that these morphologic transformations of the basilar artery may cause posterior circulation infarction (5-7,12,13). However, it has not been investigated whether there is an association between VA stenosis and BA tortuosity. The researchers mainly calculate basilar artery tortuosity index

and bending length in order to investigate the basilar artery tortuosity. However, in addition to these two parameters, the present study used a new parameter, the basilar artery deflection angle (BADA).

The aim of the present study was to investigate the effect of the vertebral artery stenosis on the basilar artery tortuosity via the BADA.

■ MATERIAL and METHOD

This study was designed retrospectively and approved by the Research Ethics Committee of a University Hospital, Faculty of Medicine (Session No: 2022/07, Decision No: 05, Date: 15.02.2022).

The Patients

A total of 158 consecutive patients who have referred due to the complaints of ischemic stroke (TIA or mild stroke) / stroke-like symptoms (dizziness, nausea, vomiting, or gait imbalance) were recruited. We chose the patients who had digital subtraction angiography (DSA) and brain magnetic resonance angiography (MRA), or brain computed tomographic angiography (CTA). The patients, who had insufficient data or detected any anatomical variations (VA hypoplasia, VA dissection, or aneurysm), were excluded from the study.

Dominant VA and BADA

The images of brain MRA or CTA were employed to define the dominant VA and calculate the BA deflection angle. However, there has been no widespread consensus on a standard definition of the dominant VA. Therefore, the method used in previous studies was performed (7,13-16). First, the diameters of both vertebral arteries were measured at 3 mm caudal from the VBJ. Then, the diameter over 0.3 mm larger than the contralateral VA was defined as the dominant VA (DVA). If there was no diameter difference between vertebral arteries, we used the term of the co-dominant VA (co-DVA) for both sides. Basilar artery deflection angle was referred to as an angle between the straightened basilar artery and the line from the VBJ to the greatest bending point of the BA (Figure 1).

Groups

One hundred and fifty eight patients were divided into two main groups according to the VAS in the right or left VA through the DSA study. Moreover, three sub-groups were determined (with <70% stenosis, with $\geq 70\%$ stenosis, or without stenosis), as it was known that the patient who has stenosis at and above 70% might tend to be more symptomatic (17). Then we compared all these groups according to the following variables: gender, age, stroke risk factors, and BADA values.

Statistical analysis

The data were evaluated through the IBM SPSS (Statistical Package for Social Sciences) 20 software. For continuous variables, Mann-Whitney U test was used; Chi-Square test was utilized for categorical variables; Spearman's rho test was used for correlation. Binary logistic regression was used for

regression analysis. Any p value below 0.05 was considered significant in all analyzes.

■ RESULTS

In this study, 45 CTA and 113 MRA findings were analyzed to investigate BA tortuosity and dominant VA, and simultaneously 158 DSA findings were explored in order to detect any stenosis in the VAs. The mean age of the 158 patients was 67.01 ± 14.72 years (range 23-96), and 101 (63.9%) were male. Among the patients, 63 cases were left-sided DVA (39.9%), 43 cases were right-sided DVA (27.2%), and 52 cases were co-DVA (32.9%). The DSA was used to evaluate 316 arteries. The results of DSA revealed 74 and 242 cases with and without VAS, respectively (23.4% vs. 76.6%). The right-sided VAS (n=35) consisted of 22 patients with <70% stenosis and 13 patients with $\geq 70\%$ stenosis. The left-sided VAS (n=39) consisted of 13 patients with <70% stenosis and 26 patients with $\geq 70\%$ stenosis. However, there was no significant difference between the groups with and without VAS regarding dominant VA (54 vs. 52, $p=0.140$).

There was not any significant difference between the groups with and without VAS in the right and left VA in the range of gender, diabetes mellitus, coronary artery disease, hyperlipidemia, and smoking (X^2 , $p>0.05$). In the left VA, hypertension (HTN) was found to be significantly higher in the patients with VAS (N=36; 92.3%) than in those without VAS (N=87; 73.1%) (X^2 , $p=0.012$). Nonetheless, no such significant difference was found in the Right VA. In the left VA, the BADA average was found 25.26 ± 13.64 in patients with VAS and 19.84 ± 17.29 in patients without VAS (Mann-Whitney U test, $p=0.008$) (Table I).

In the subgroup analysis, in the left VA, the group with <70% VAS had the means of BADA significantly higher than the group without VAS (Mann-Whitney U test, $p=0.012$) (Table II).

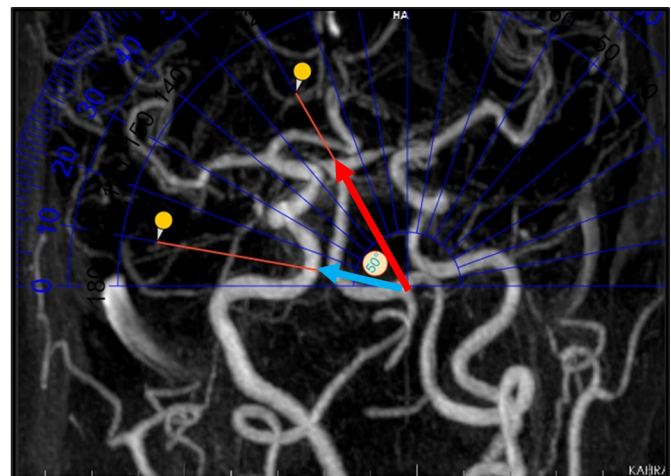


Figure 1: Basilar artery deflection angle (BADA): An angle between the straightened basilar artery (red arrow) and the line from the vertebrobasilar junction to the greatest bending point of the basilar artery (blue arrow).

Table I: Comparison of the Right or Left Vertebral Artery with VAS (+) and without VAS (-) Groups in Terms of the Following Variables: Sex, Age, Stroke Risk Factors, and Basilar Artery Deflection Angles

	Right VA (VAS + / -)	p	Left VA (VAS + / -)	p
Sex (male)	77.1% - 60.2%	0.065	69.2% - 62.2%	0.180
Age (years)	69.51 ± 12.28 / 66.30 ± 15.30	0.418	68.36 ± 12.06 / 66.57 ± 15.50	0.784
DM	45.7% - 39.0%	0.477	43.6% - 39.5%	0.651
CAD	37.1% - 38.2%	0.909	35.9% - 38.7%	0.758
Stroke	65.7% - 78.0%	0.135	79.5% - 73.9%	0.486
HTN	88.6% - 74.8%	0.083	92.3% - 73.1%	0.012
Smoking	14.3% - 11.4%	0.416	10.3% - 12.6%	0.472
BADA (°)	22.60 ± 15.89 / 20.77 ± 16.83	0.455	25.26 ± 13.64 / 19.84 ± 17.29	0.008
HL (LDL mg/dl)	117.59 ± 31.74 118.90 ± 37.73	0.996	120.46 ± 42.34 118.00 ± 34.38	0.858

a. **DM:** diabetes mellitus, **CAD:** Coronary artery disease, **HTN:** Hypertension, **VAS:** Vertebral artery stenosis, **BADA:** Basilar artery deflection angle, **HL:** Hyperlipidemia, **LDL:** Low density lipoprotein.

Table II: The Subgroup Analysis Shows a Pairwise Comparisons of the Three Groups on Both Sides (VA without stenosis (-), VA with <70% stenosis, VA with ≥70% stenosis)

RVA	BADA (°)	p
VAS (-) / VAS (< 70%)	20.77 ± 16.83 / 24.55 ± 15.11	0.215
VAS (-) / VAS (≥ 70%)	20.77 ± 16.83 / 19.31 ± 17.23	0.731
VAS (< %70) / VAS (≥ 70%)	24.55 ± 15.11 / 19.31 ± 17.23	0.267
LVA	BADA (°)	p
VAS (-) / VAS (< 70%)	19.84 ± 17.29 / 30.38 ± 14.70	0.012
VAS (-) / VAS (≥ 70%)	19.84 ± 17.29 / 22.69 ± 12.59	0.087
VAS (< %70) / VAS (≥ 70%)	30.38 ± 14.70 / 22.69 ± 12.59	0.089

a. **VAS:** Vertebral artery stenosis, **RVA:** Right vertebral artery, **LVA:** Left vertebral artery, **BADA:** Basilar artery deflection angle.

The association between the side of the dominant vertebral artery and bending of the basilar artery was also investigated. A significantly negative correlation was found between both sides ($r=-0.239$, $p=0.002$) (Table III). The following morphological changes in the BA were also detected: 68 C-shaped (43%), 22 J-shaped (13.9%), 16 S-shaped (10.1%), 25 diagonal line-shaped (15.8%), and 27 straight (17.1%).

A significant but quite lower correlation was detected between the diameter of the left VA and the means of BADA ($\rho=0.189$, $p=0.018$). In the binary logistic regression analysis, the frequency of HTN was 5.4 times higher in those patients with left-sided VAS than those without VAS (OR= 5.395; 95% confidence interval 1.440 - 20.213; $p=0.012$) (Table IV).

DISCUSSION

The age average found in the present study was 67.01 ± 14.72 years; and 63.9% of patients were male. Nevertheless, there was not any difference between the groups regarding the age and gender. Among the 158 patients, it was also noted 106 DVAs (67.1%), and most of them were left-sided

(39.9%). Furthermore, it was observed that there was not any significant difference between the groups with and without VAS regarding dominant VA ($p=0.140$).

Some previous studies investigated the correlation between dominant VA and BA tortuosity (18-22). Most of these studies showed that the bending direction of the basilar artery was significantly on the opposite side of the dominant vertebral artery (8,11,14). In our study, it was found that there was a significantly negative correlation between the side of the dominant vertebral artery and bending of the basilar artery ($p=0.002$).

In invasive and non-invasive imaging studies, tortuosity of the basilar artery is frequently observed in both normal and sick individuals. However, the mechanisms of the tortuosity remain unclear (11). In recent studies, several mechanisms are suggested to explain the basilar artery tortuosity. However, BA tortuosity may be mostly related to the hemodynamic and vascular remodeling theories. Previous studies reported that one of the vertebral arteries (mainly the left VA) was anatomical dominant among most individuals, and this finding was consistent with the present study. However, there is

Table III: Correlation Between the Side of the Vertebral Artery Dominance and the Basilar Artery Bending

	Vertebral artery dominance			Total
	Co-dominant	Right-dominant	Left-dominant	
Basilar artery bending				
Right-bending	38	17	50	105
Left-bending	10	22	12	44
Straight	4	4	1	9
Total	52	43	63	158

a. Spearman's rank correlation, $r: -0.239$, $p: 0.002$.

Table IV: Binary Logistic Regression Analysis

Left VAS	B	S.E.	Wald	p	OR	95% C.I.for EXP(B)	
						Lower	Upper
Dominant VA	0.638	0.439	2.105	0.147	1.892	0.800	4.477
HTN	1.685	0.674	6.254	0.012	5.395	1.440	20.213
DM	-0.135	0.405	0.111	0.740	0.874	0.395	1.935
Stroke	0.369	0.466	0.627	0.428	1.446	0.580	3.604
CAD	-0.481	0.409	1.383	0.240	0.618	0.277	1.378
Smoking	-0.173	0.624	0.076	0.782	0.841	0.247	2.861

a. **VAS:** Vertebral artery stenosis; **B:** coefficient; **S.E.:** standard error; **OR:** odds ratio; **Exp (B):** Exponentiation of the B coefficient; **C.I.:** confidence interval. **VA:** vertebral artery; **HTN:** hypertension; **DM:** diabetes mellitus; **CAD:** coronary artery disease.

no consensus about the standard definition of DVA. Some studies use the term dominant VA when one of the VAs has a diameter difference, at least 0.3 mm, from the contralateral side. Other studies use the criteria of dominant VA when there is a 1.2 mm or at least 30% diameter difference between two VAs (2,7,8). Besides these methodological differences, the unequal diameters of the VAs may cause an asymmetric VA flow through to the BA; therefore, the BA may bend to the direction of the smaller VA side (hemodynamic theory). Furthermore, the asymmetric blood flow of VAs may directly simulate the pressure on the vessel wall of the BA. The blood vessels in the vertebro-basilar system may change to adapt to the long-term impact of the asymmetric blood flow (vascular remodeling theory) (5,14,20,23,24). A significant but lower correlation was detected between the diameter of the left VA and the BADA average in this study ($p=0.018$).

Recent studies have shown that VA asymmetry might be a risk factor in the etiology of posterior circulation stroke, although it was previously considered as a congenital variant without vertebro-basilar insufficiency (25). It was also reported that tortuosity and hypoplasia in the vertebro-basilar arteries might promote infarctions of the posterior circulation by changing hemodynamics. Nevertheless, most of these studies have investigated the association between tortuosity and intracranial atherosclerotic events (pontine infarctions) (20,23,26,27). Therefore, the present study investigated whether there was

a relationship between BA tortuosity and extracranial atherosclerotic events (vertebral artery stenosis). In the left-sided VA, it was observed that 39 patients with VAS had significantly more BADA average than the others ($p=0.008$). According to the subgroup analysis, in the left-sided VA, the mean values of BADA were significantly higher in the patients with $<70\%$ VAS than the patients without VAS (-) ($p=0.012$). In the light of these results, it could be concluded that VAS below 70% VAS may contribute to the force of asymmetric VA flow and increase the risk of the BA tortuosity.

In previous studies, the BA bending length was usually used to evaluate the BA tortuosity. However, it was also noticed that the BA bending length might be changed by the different measurement methods in different studies. Therefore, a new parameter (BADA) was applied in the present study, because BADA might be simply calculated by using only one standard measurement method.

In this study, it was found that the patients with VAS had higher HTN prevalence than the patients without VAS; however, this difference was only significant in the left-sided VA ($p=0.012$). On the left side, the patients with VAS had 5.4 times higher HTN prevalence than the patients without VAS ($OR=5.395$; 95% confidence interval 1.440 - 20.213). This was tried to explain by the difference in the origins of the bilateral vertebral arteries. It is known that the left and the right vertebral arteries are the second and third branches of the

aorta, respectively. Hence, the left VA originates directly from the aorta, and it is more sensitive to blood pressure changes. Furthermore, some studies claimed that age, hypertension, and atherosclerosis are the major causes of vertebral and basilar arteries curvature (5,12,13). Regardless of HTN, there were no differences between the patients with VAS and those without VAS according to other acute stroke risk factors in this study. The C-Shaped BA (43%) was the most common morphology change of the BA in our study, similar to the result obtained by Hong et al. (6).

There are some limitations of this study. The retrospective study is the first limitation; therefore, there may be the possibility of selection bias. Second, the subjects had more vascular risks than the general population were included to the study. Third, the BADA measurement method was used for the first time in the present study. Hence, this method needs more studies to prove its reliability in the future.

■ CONCLUSION

Our results suggest that VA stenosis (<70%) may be one of the substantial causes of the BA tortuosity because of affecting the VA flow, especially on the left side. Furthermore, BADA may be a feasible and reliable parameter to investigate this tortuosity. To the best of our knowledge, this study may be the first report on the correlation between BA tortuosity and VA stenosis, despite the lower prevalence of VA stenosis.

■ AUTHORSHIP CONTRIBUTION

Study conception and design: HS

Data collection: HS

Analysis and interpretation of results: HS

Draft manuscript preparation: HS

Critical revision of the article: HS, MG

Other (study supervision, fundings, materials, etc...): HS, MG

All authors (HS, MG) reviewed the results and approved the final version of the manuscript.

■ REFERENCES

- Burulday V, Doğan A, Akgül MH, Alpua M, Çankaya I: Is there a relationship between basilar artery tortuosity and vertigo? *Clin Neurol Neurosurg* 178: 97-100, 2019
- Cagnie B, Petrovic M, Voet D, Barbaix E, Cambier D: Vertebral artery dominance and hand preference: is there a correlation? *Man Ther* 11: 153-156, 2006
- Cao SG, Ni X, Wu Q, He J, Cui P, Ge T, Li Y, Wang J, Wen'an XU, Xia M: Basilar artery dolichosis is associated with a poor 90-day outcome in acute isolated pontine infarction. *Sci Rep* 10: 6557, 2020
- Chang JY, Jung S, Jung C, Bae HJ, Kwon O, Han MK: Dominant vertebral artery status and functional outcome after endovascular therapy of symptomatic basilar artery occlusion. *J Neuroradiol* 44: 151-157, 2017
- Cosar M, Yaman M, Eser O, Songur A, Ozen OA: Basilar artery angulation and vertigo due to the hemodynamic effect of dominant vertebral artery. *Med Hypotheses* 70: 941-943, 2008
- Del Brutto VJ, Prabhakaran S, Liebeskind DS: Intracranial dolichoectasia in patients with symptomatic intracranial atherosclerotic disease: Results from the MYRIAD study 31: 931-939, 2021
- Ding S, Yan X, Guo H, Yin F, Sun X, Yang A, Yao W, Zhang J: Morphological characteristics of the vertebrobasilar artery system in patients with hemifacial spasm and measurement of bending length for evaluation of tortuosity. *Clin Neurol Neurosurg* 198: 106144, 2020
- Edmond EC, Sim SX, Li HH, Tan EK, Chan LL: Vascular tortuosity in relationship with hypertension and posterior fossa volume in hemifacial spasm. *BMC Neurol* 16: 120, 2016
- Hong JM, Chung CS, Bang OY, Yong SW, Joo IS, Huh K: Vertebral artery dominance contributes to basilar artery curvature and peri-vertebrobasilar junctional infarcts. *J Neurol Neurosurg Psychiatry* 80: 1087-1092, 2009
- Hori S, Hori E, Umemura K, Shibata T, Okamoto S, Kubo M, Horie Y, Kuroda S: Anatomical Variations of Vertebrobasilar Artery are Closely Related to the Occurrence of Vertebral Artery Dissection-An MR Angiography Study. *J Stroke Cerebrovasc Dis* 29: 104636, 2020
- Jeong SK, Lee JH, Nam DH, Kim JT, Ha YS, Oh SY, Park SH, Lee SH, Hur N, Kwak HS, Chung GH: Basilar artery angulation in association with aging and pontine lacunar infarction: a multicenter observational study. *J Atheroscler Thromb* 22: 509-517, 2015
- Kliś KM, Krzyżewski RM: Increased tortuosity of basilar artery might be associated with higher risk of aneurysm development. *30: 5625-5632, 2020*
- Li X, Guan L, Zilundu PLM, Chen J, Chen Z, Ma M, Zhuang H, Zhuang Z, Qiu Y, Ye F, Wu X, Sang H, Ye Y, Han Y, Yao H, Li H, Zhong G, Wu H, Jiang Z, Chu G, Xu D, Zhou L: The applied anatomy and clinical significance of the proximal, V1 segment of vertebral artery. *Folia Morphol (Warsz)* 78: 710-719, 2019
- Meng X, Ding W, Wu X, Di P: Clinical investigation and characterization of vertebrobasilar dolichoectasia and vertebral artery dominance. *Discov Med* 25: 151-158, 2018
- Moneta GL, Edwards JM, Chitwood RW, Taylor LM, Jr., Lee RW, Cummings CA, Porter JM: Correlation of North American Symptomatic Carotid Endarterectomy Trial (NASCET) angiographic definition of 70% to 99% internal carotid artery stenosis with duplex scanning. *Journal of vascular surgery* 17: 152-157; discussion 157-159, 1993
- Ngo MT, Kwak HS, Chung GH: Change in basilar artery length and bending according to aging and vertebral artery dominance: A longitudinal study. *Sci Rep* 10: 8904, 2020
- Nishikata M, Hirashima Y, Tomita T, Futatsuya R, Horie Y, Endo S: Measurement of basilar artery bending and elongation by magnetic resonance cerebral angiography: relationship to age, sex and vertebral artery dominance. *Arch Gerontol Geriatr* 38: 251-259, 2004
- Novakovic-White R, Corona JM, White JA: Posterior Circulation Ischemia in the Endovascular Era. *Neurology* 97: 158-169, 2021

19. Sun J, Liu G, Zhang D, Wu Z, Liu J, Wang W: The Longitudinal Distribution and Stability of Curved Basilar Artery Plaque: A Study Based on HR-MRI. *J Atheroscler Thromb* 28: 1333-1339, 2021
20. Wang QP, Yuan Y, Xiong NX, Fu P, Huang T, Yang B, Liu J, Chu X, Zhao HY: Anatomic Variation and Hemodynamic Evolution of Vertebrobasilar Arterial System May Contribute to the Development of Vascular Compression in Hemifacial Spasm. *World Neurosurg.* 26: 1878-8750, 2018
21. Yu J, Zhang S, Li ML, Ma Y, Dong YR, Lou M, Feng F, Gao S, Wu SW, Xu WH: Relationship between the geometry patterns of vertebrobasilar artery and atherosclerosis. *BMC Neurol* 18: 83, 2018
22. Zhang DP, Peng YF, Zhang HL, Ma JG, Zhao M, Yin S, Wei TT: Basilar Artery Tortuosity Is Associated With White Matter Hyperintensities by TIMP-1. *Front Neurosci* 13: 836, 2019
23. Zhang DP, Zhang SL, Zhang HT, Zhang SJ: Vertebral artery dominance, brainstem auditory evoked potential, and vertigo of vascular origin. *Neurol Res* 34: 498-503, 2012
24. Zhang DP, Zhang SL, Zhang JW, Zhang HT, Fu SQ, Yu M, Ren YF, Ji P: Basilar artery bending length, vascular risk factors, and pontine infarction. *J Neurol Sci* 338: 142-147, 2014
25. Zhang HL, Peng YF, Zhang DP, Li D, Liu FX, Zhao M, Yin S, Liang JX, Wei TT: MMP-9, Vertebrobasilar Ectasia and Vertebral Artery Dominance in Vertigo or Dizziness Patients With Vascular Risk Factors. *Front Neurol* 11: 931, 2020
26. Zhou L, Yan Y, Du H, Ni X, Wang G, Wang Q: Plaque features and vascular geometry in basilar artery atherosclerosis. *Medicine (Baltimore)* 99: e19742, 2020
27. Zhu W, Wang YF, Dong XF, Feng HX, Zhao HQ, Liu CF: Study on the correlation of vertebral artery dominance, basilar artery curvature and posterior circulation infarction. *Acta Neurol Belg* 116: 287-293, 2016