



A Nomogram for Prediction of Patients with Anaplastic Ependymoma in the Brain and Spinal Cord Survival

Hui LIU, Peng SUN

Affiliated Hospital of Qingdao University, Department of Neurosurgery, Qingdao, China

Corresponding author: Peng SUN ✉ sunpeng@qdu.edu.cn

ABSTRACT

AIM: To establish a model of intracranial and spinal cord anaplastic ependymomas, and to find out their independent prognostic factors.

MATERIAL and METHODS: Data from 305 patients with anaplastic ependymoma in the brain and spinal cord from the Surveillance, Epidemiology, and End Results (SEER) database between 1988 and 2015 were retrospectively extracted and analyzed using the R software. Statistical significance indicators were identified using the Cox regression analysis. The nomogram visualized the model and was corrected using the concordance index (C-index), area under the curve (AUC), and calibration curve.

RESULTS: Analysis revealed that age and treatment were found to be of statistical significance in this study. On the basis of the results of the present study, the model's C-index was 0.777 and the AUC value of the time-dependent receiver operating characteristic curve at 2, 3, and 5 years were 0.758, 0.775, and 0.788, respectively, demonstrating a decent discriminatory ability. Finally, a nomogram was constructed and validated using a validation curve.

CONCLUSION: In summary, the present study revealed the two risk factors (including age and treatment) as independent prognostic factors for patients with anaplastic ependymoma in the spinal cord and brain. The suggested model can accurately assess the disease-specific survival rate of these patients and can provide recommendations for optimal treatment options.

KEYWORDS: Anaplastic ependymoma, Postoperative, Nomogram, Prognostic factors, Time-dependent receiver operating characteristic (ROC)

ABBREVIATIONS: SEER: The surveillance, epidemiology, and end results, WHO: World health organization, C-index: Concordance index, ROC: The time-dependent receiver operating characteristic, AUC: Area under the curve, HR: Hazard ratio

INTRODUCTION

Ependymoma is the second most common brain tumor in children and accounts for approximately 3%–5% of central nervous system tumors in adults (12,13,24). Now ependymoma is divided into supratentorial, posterior fossa (PF) and spinal cord molecular groups according to histopathology, molecular characteristics and anatomical location (36). Intramedullary ependymoma accounts for approximately 50% of intramedullary tumors in adults (7,11,26,32).

With respect to imaging diagnosis, enhanced MRI is the main diagnostic method for diagnosing ependymoma (20,39). The most common calcification in subependymal tumors can be visualized more optimally by computed tomography (27). With respect to pathological characteristics, for anaplastic ependymoma, WHO grade III includes the characteristics of high mitotic activity and microvascular proliferation. Moreover, pseudopalisading necrosis may also be observed. Nevertheless, the precise histological differentiation of WHO grade II and III ependymoma is challenging, and its role in predicting survival has been controversial (6).

On the basis of the literature, prognosis of this disease is more optimal than that of other intramedullary tumors (34) as there are guidelines recommending postoperative ependymoma at grade II while all patients with ependymoma at grade III undergo radiotherapy (2,15,25). Previous studies demonstrated that temozolomide has been the primary treatment for adult patients (27) although larger studies are required for confirmation. Importantly, surgery is still vital for ependymoma in adult patients (27). However, surgery and radiotherapy are the primary treatment options for children with ependymoma (23). On the basis of all of the above, it can be concluded that there is not yet a universal treatment option.

Although there are various studies regarding anaplastic ependymoma in the brain or spinal cord, our group was the first to establish a model of spinal cord and intracranial anaplastic ependymoma.

In the present study, data from 305 cases of anaplastic ependymoma in the spinal cord and brain were retrospectively extracted from the SEER database and R software was used to screen out statistical variables as independent prognostic factors. The prognosis of patients was performed using a nomogram, and the model was calibrated using a calibration curve.

MATERIAL and METHODS

Data Sources

Spinal cord and intracranial anaplastic ependymoma data between 1988 and 2015 were retrospectively obtained from the SEER database using SEER*Sat version 8.3.8 (<https://seer.cancer.gov/>), including 18 seer registry studies.

Inclusion and Exclusion Criteria

Assessment of spinal cord and intracranial anaplastic ependymoma was focused in obtaining the independent prognostic risk factors. The inclusion criteria included (a) positive histological examination of anaplastic ependymoma diagnosed between 1988 and 2015 with histology code 2000 and all cases with (b) treatment information, (c) detailed follow-up date; and (d) anaplastic behavior recode. Exclusion criteria included those with (a) unknown survival time; (b) unknown extension; (c) only chemotherapy treatment; (d) no treatment; (e) surgery radiation; and (f) surgery contraindications due to other conditionconditions; autopsy only (Figure 1).

Data Variables

Data concerning age, sex, race, year of diagnosis, treatment (including surgery chemotherapy sequence unknown, surgery, radiation after surgery, radiation after surgery chemotherapy sequence unknown, and radiation), location (brain and spinal cord), situation (posterior fossa and other), and tumor extension (including localized and further extension) were collected. All cases had a well-defined return date.

Statistical Analysis

Initially, univariate Cox regression analysis was used to identify possible prognostic risk factors and those with $p < 0.05$ selected as potential risk factors in univariate analysis. Finally, a prediction model was developed on the basis of all risk factors with $p < 0.05$, the best prediction model was gradually selected on the basis of the Akaike information criterion results (10), and the model was visualized on a nomogram. Concordance index (C-index) and time-dependent receiver operating characteristic (ROC) curves were used to valuate

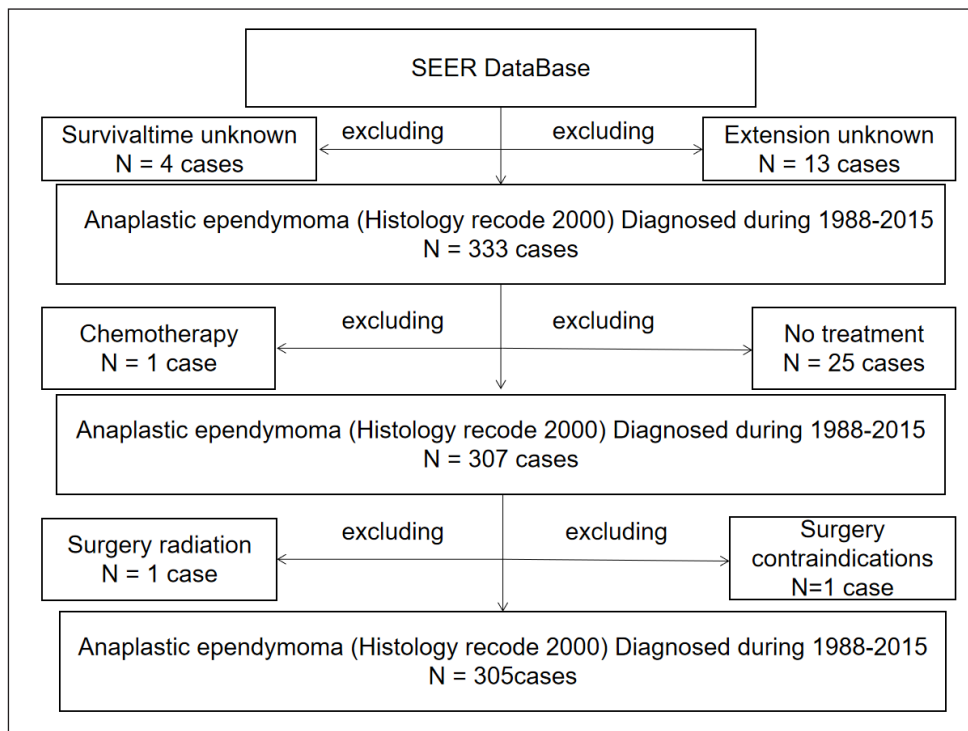


Figure 1: Flow chart of patient selection.

precision and discrimination (9,38). The comparison among the actual probability and predicted outcomes of the model can be visualized using calibration curves (4). One hundred resampling methods were used to evaluate the calibration curves and discrimination, and the most optimal cutoff value was obtained using X-tile software.

All statistical analyses were performed on R software version 4.0.5 (<http://www.r-project.org/>).

RESULTS

Clinicopathological Characteristics of Patients

Three hundred five patients with anaplastic ependymoma were enrolled in the present study. The basic information of the patients is presented in Table I. The ratio of females to males was 1:1.26. The majority of patients were white (n=232 cases, 76.1%). The ratio of patients above and below 10 years old was 1:4.55. Moreover, the majority of tumors were localized (n=261 cases, 85.6%). The ratio of tumors identified before and after the year 1992 was 1:3.92. The ratio of brain to spinal cord ependymoma was 1:1. All patients were diagnosed using positive histology.

Univariate Analysis

Age, time of diagnosis, location, situation, and treatment showed statistical significance on Cox univariate analysis. The results of the univariate analysis are presented in Figure 2. Other factors were excluded from the multivariate analysis because of selection bias.

Independent Prognostic Factors in the Cohort

The results of the multivariate analysis of the cohort are presented in Figure 3. Age and treatment were found to be statistically significant. The multivariate analysis involved treatment [surgery chemotherapy sequence unknown: hazard ratio (HR) (95% CI)=0.1575 (0.03207–0.7733), p=0.02281; radiation after surgery: HR (95% CI)=0.1405 (0.03691–0.5352), p=0.00402; radiation after surgery chemotherapy sequence unknown: HR (95% CI)=0.2274 (0.05529–0.9354), p=0.04013; surgery: HR (95% CI)=0.1242 (0.02952–0.5228), p=0.00445] and age [≥ 10 years: HR (95% CI)=0.3575 (0.17344–0.7369), p=0.00531]. Finally, the effect of all dependent prognostic factors on patient survival was represented using a Kaplan-Meier curve (Figure 4).

Prognostic Nomogram of Overall Survival

The independent prognostic factors of the cohort are shown in the nomogram (Figure 5). In the nomogram, each variable corresponded to a score on the scale, and scores of the individual variables were added to obtain the total score. Finally, the survival rate was defined by corresponding the total score to the score scale. Treatment and age had the highest and lowest percentages, respectively.

Validation of the Nomogram

The C-index for the cohort was defined as 0.777. Furthermore, the time-dependent ROC and the area under the curve value at 2, 3, and 5 years were 0.758, 0.775, and 0.788,

Table I: Baseline Clinicopathological Features and Treatments

Variables	Number of patients
Age (years)	305
<10	55
≥ 10	250
Race	305
White	232
Other	73
The time of diagnosis	305
>1992	243
≤ 1992	62
Location	305
Brain	165
Spinal cord	140
Sex	305
Female	135
Male	170
Situation	305
Posterior fossa	69
Other	236
Extension	305
Further extension	44
Localized	261
Treatment	305
Radiation after surgery	92
Radiation after surgery chemotherapy sequence unknown	27
Surgery Chemotherapy sequence unknown	17
Surgery	164
Radiation	5

respectively, demonstrated a decent discriminatory potential (Figure 6). Calibration curves were utilized to demonstrate the comparison between the actual probability and predicted outcomes (Figure 7).

DISCUSSION

Anaplastic ependymoma is a rare type of cancer, and identification of the risk factors affecting disease prognosis is essential. For the present study, high-quality clinical data were

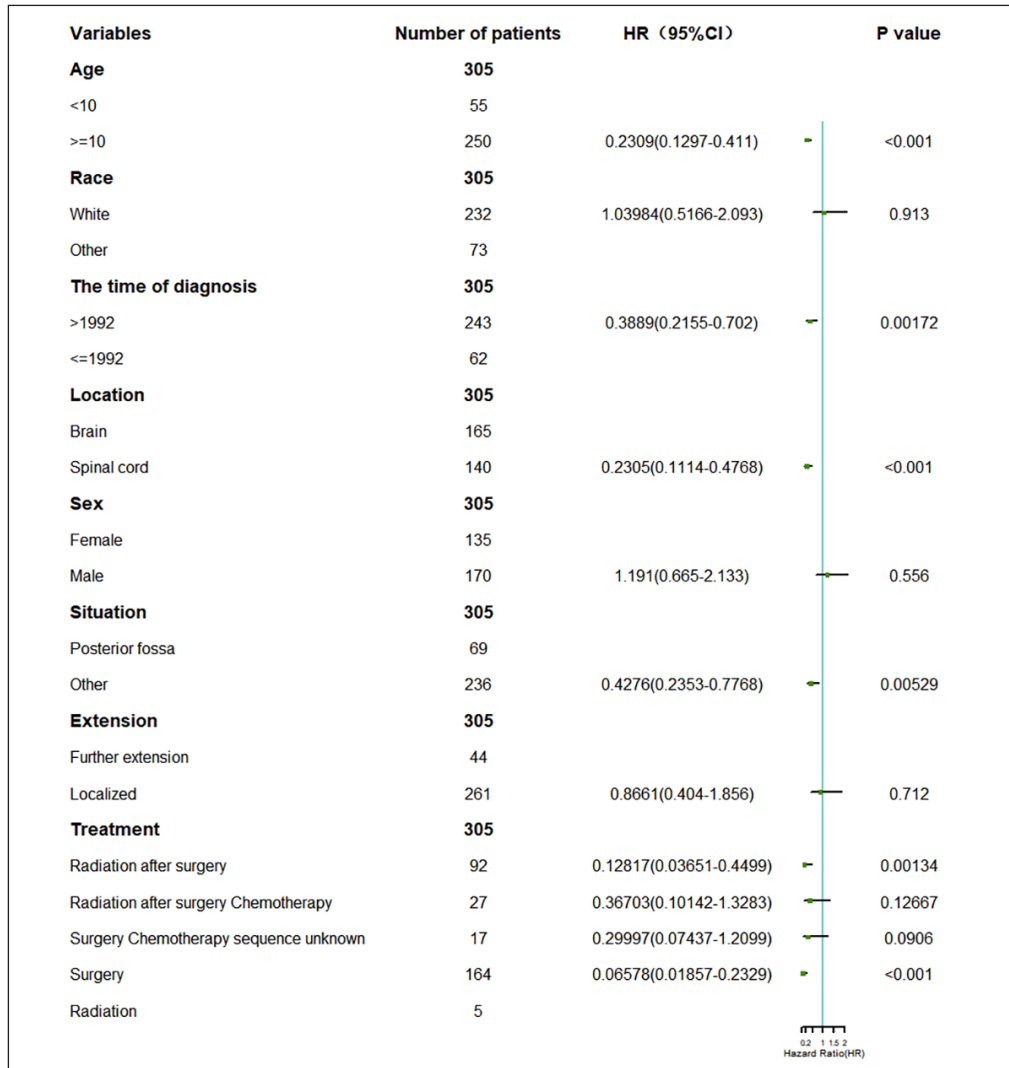


Figure 2: Clinicopathological features of the patients and results of the univariate COX proportional hazards analysis (HR, 95%confidence interval).

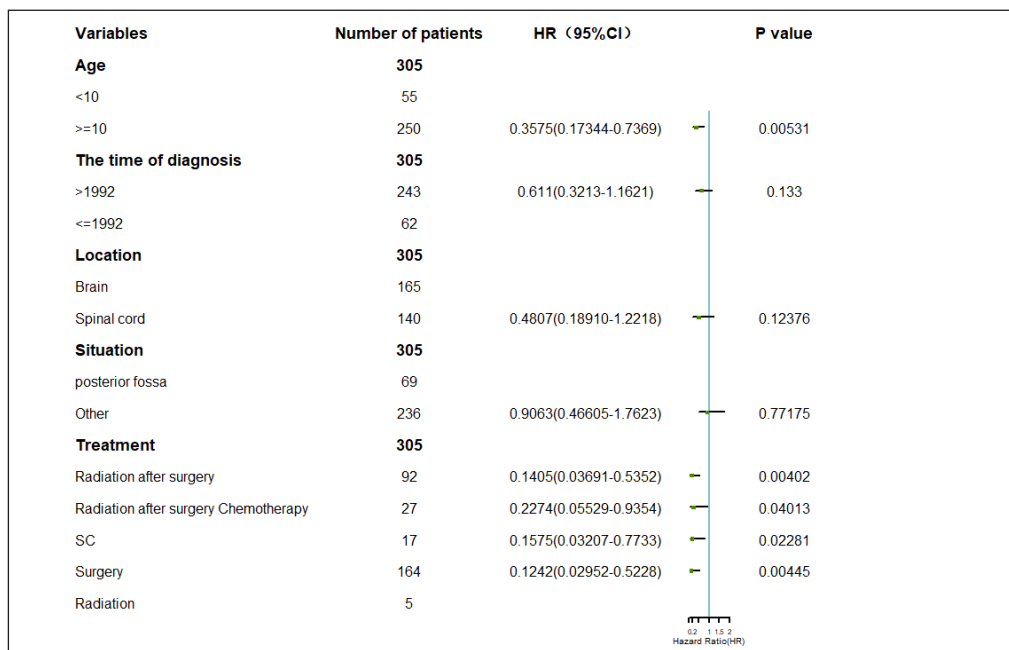


Figure 3: Results of the multivariate analysis of various factors (HR, 95% confidence interval).

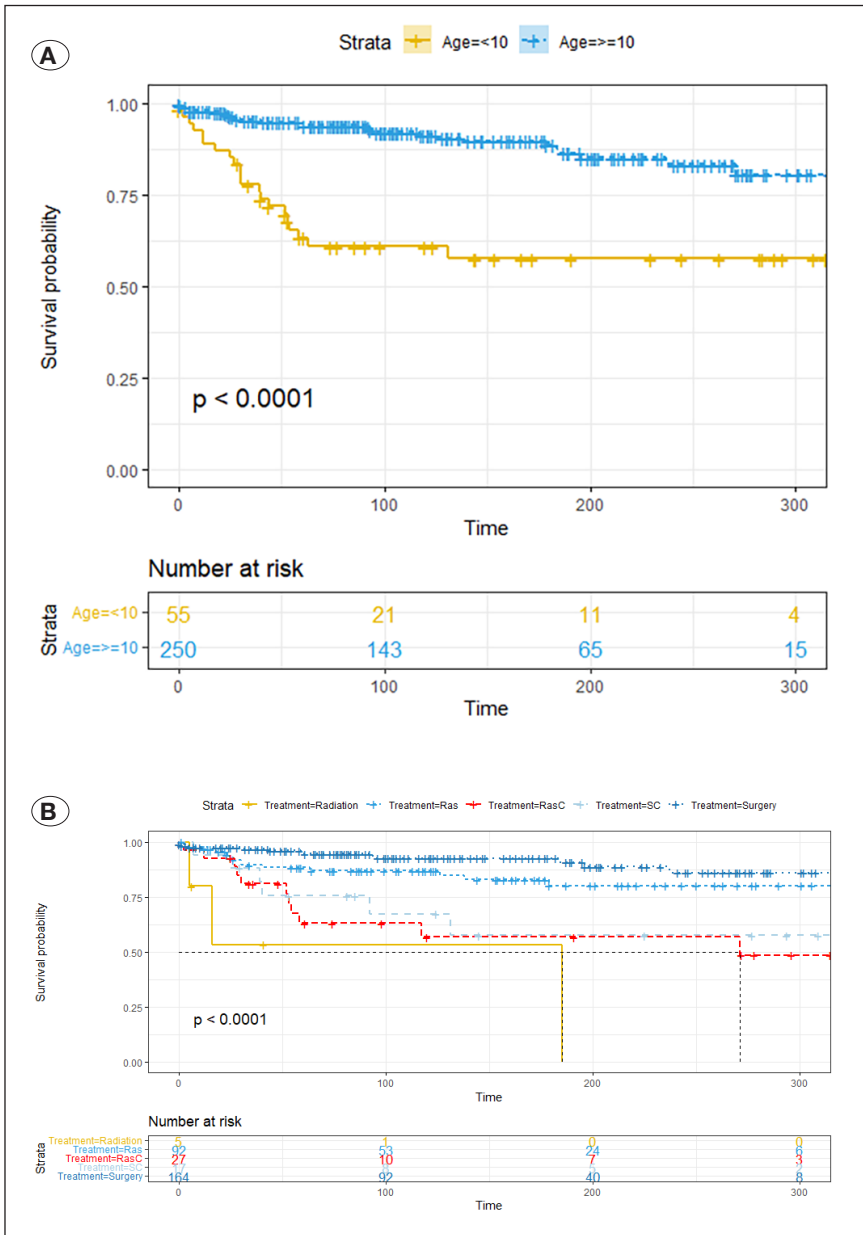


Figure 4: Kaplan-Meier curves for patients with anaplastic ependymoma. Age (A), Treatment (B). **Ras:** Radiation after surgery, **RasC:** Radiation after surgery Chemotherapy sequence unknown, **SC:** Surgery Chemotherapy sequence unknown. The time unit is month.

vital. Nevertheless, examining ependymoma prospectively is challenging because of the disease rarity. Data from 305 cases of anaplastic ependymoma in the brain and spinal cord were thus extracted from the SEER database. The results of the multivariate analysis revealed that treatment and age were statistically significant factors in this study.

Limited data on the clinical features and prognostic models in postoperative anaplastic ependymoma are available. The nomogram has been previously used to present improved predictive value than the traditional model (3,16). A nomogram was thus constructed for the purposes of the present study using data from 305 patients with anaplastic ependymoma in the brain and the spinal cord. Additionally, its differentiating ability and accuracy were assessed using AUC, C-index, and calibration curves.

Age is thought as a crucial prognostic factor in cancer (29). In the present study, age was not a statistically significant prognostic factor based on univariate Cox analysis. The HR of age ≥ 10 years was 0.3575 compared with that of age < 10 years ($p=0.00531$). Previous studies discovered lower survival rates in children (22). Various other studies have reported that intracranial ependymoma in children under 3 years of age was correlated to more aggressive histology, advanced disease at diagnosis, and higher recurrence rates (17,19,33,37).

Tumor size information was not involved in the statistical analysis as it was not available during the study.

On the basis of previous studies, spinal cord ependymoma presents a longer survival time and a low recurrence rate (18,28,30,31,37). However, in the present study, patients with

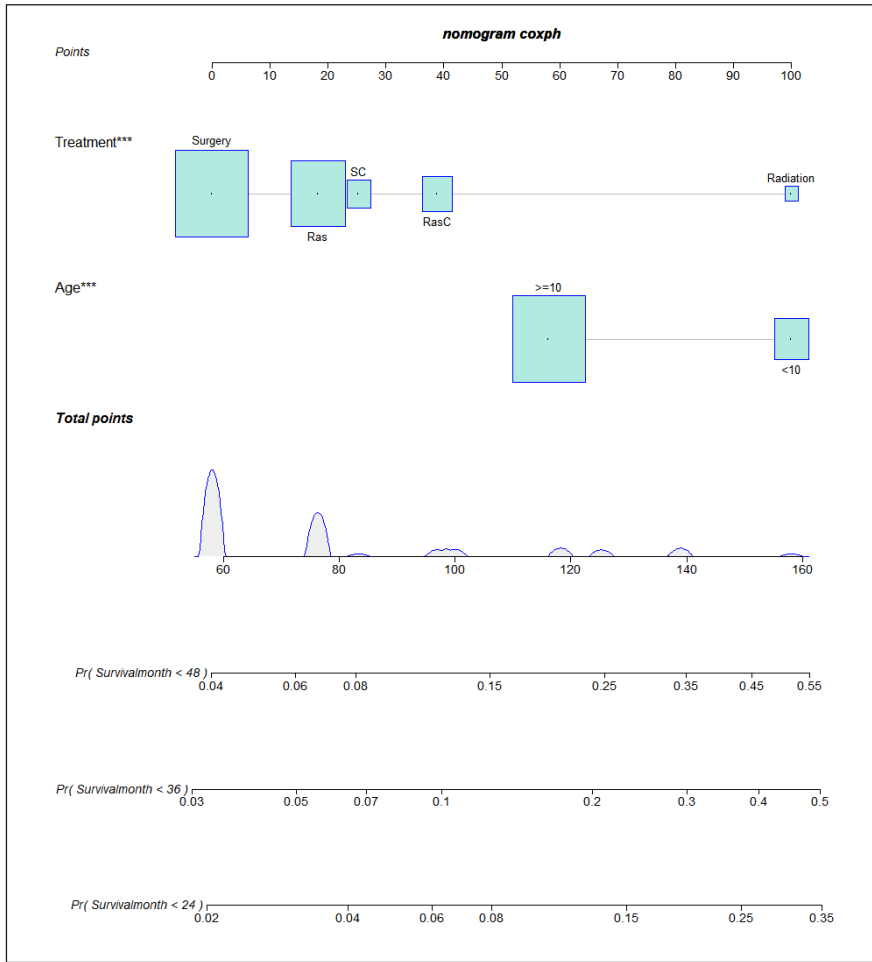


Figure 5: Nomogram predicting cancer-specific death at 24, 36, 60 months in anaplastic ependymoma patients. Prognostic factors included Age and Treatment. Each variable on the nomogram could match the scores on the scale and overall scores could be obtained by summing the scores for each variable. **Ras:** Radiation after surgery **RasC:** Radiation after surgery Chemotherapy sequence unknown. The time unit is month.

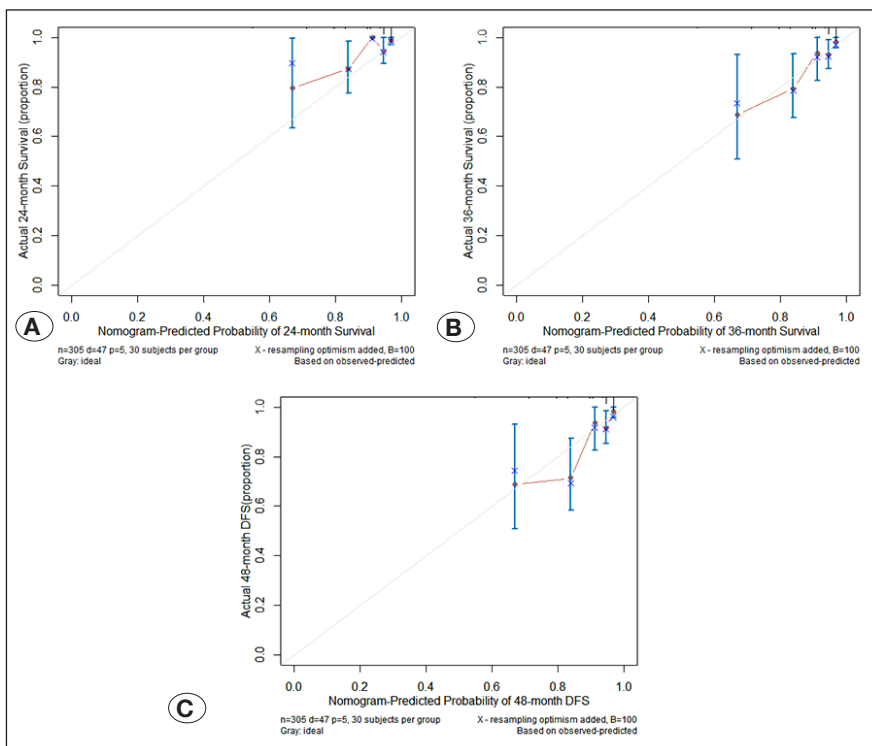


Figure 6: Calibration of nomogram.

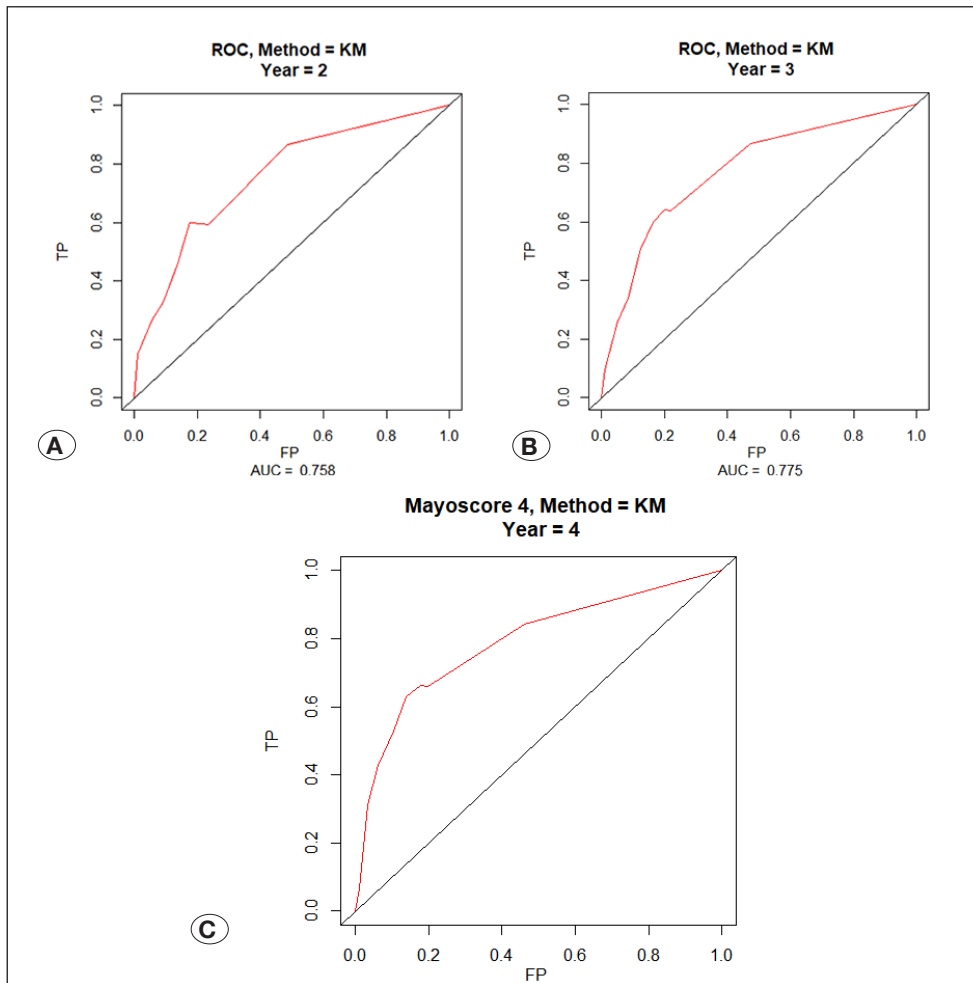


Figure 7: ROC at 2-Year, 3-Year and 5-Year.

tumors in the spinal cord were not observed to present a higher and statistically significant survival rate compared with patients with tumors in the brain ($p=0.12376$). The latter may require additional verification data.

In the present study, the year of diagnosis was a statistically significant prognostic factor based on univariate Cox analysis ($p=0.00172$). Nevertheless, in multivariate Cox analysis, it did not present any statistical significance, something that could be associated with the limited data.

Results of multivariate analysis revealed a statistically significant difference for the treatment [surgery chemotherapy sequence unknown: HR (95% CI)=0.1575 (0.03207–0.7733), $p=0.02281$; radiation after surgery: HR (95% CI)=0.1405 (0.03691–0.5352), $p=0.00402$; radiation after surgery chemotherapy sequence unknown: HR (95% CI)=0.2274 (0.05529–0.9354), $p=0.04013$; surgery: HR (95% CI)=0.1242 (0.02952–0.5228), $p=0.00445$]. In the past, surgery had been considered the standard of treatment for ependymoma (27). According to relevant available information, various guidelines recommend adjuvant radiotherapy for primary intramedullary spinal cord ependymoma (grade II) after surgical treatment and adjuvant radiotherapy for all grade III ependymoma (2,15,25). Never-

theless, various studies did not demonstrate any significant survival benefit with radiotherapy in ependymoma (1,14). Chemotherapy, as an adjuvant therapy, does not appear to offer additional benefits, but it could play a new adjuvant role in the second resection and recurrence of tumors (5). Survival benefit with radiation after surgery and chemotherapy (of unknown sequence) was statistically significant compared with that with radiation in the present study. Nevertheless, this discovery may be associated with the limited sample size, selection bias, missing data, inaccurate records, and the study population. In the present study, the treatment modalities were not personalized to maximize the benefit. Furthermore, the WHO classification was not adequate for reliable prediction of outcomes in individual patients, and molecular subgroups or single molecular markers could offer novel perspectives for improving prognostic stratification (8,13,21,35), although additional data are required for verification.

The current study is the first study of its kind as it led to the construction of a nomogram in anaplastic ependymoma in the brain and spinal cord. Most importantly, nomogram assisted clinicians in the prediction of patients' prognosis and provided treatment plans. This research thus offers important clinical application value.

Undoubtedly, this study had specific limitations. Initially, due to the large time span, there are variations in disease examination, diagnosis, and treatment. Additionally, valid data did not include genotype, and selection bias could not be avoided in a retrospective study. However, it is clear that this research offered important benefits.

CONCLUSION

This study revealed that treatment and age were independent prognostic factors in anaplastic ependymoma of the brain and spinal cord. The nomogram prepared for the purposes of this study could visualize these prognostic factors and predict patient's prognosis while offering clinicians with patient prognostic information and treatment measures.

AUTHORSHIP CONTRIBUTION

Study conception and design: HL

Data collection: HL

Analysis and interpretation of results: HL

Draft manuscript preparation: PS

Critical revision of the article: PS

All authors (HL, PS) reviewed the results and approved the final version of the manuscript.

REFERENCES

- Brown DA, Goyal A, Takami H, Graffeo CS, Mahajan A, Krauss WE, Bydon M: Radiotherapy in addition to surgical resection may not improve overall survival in WHO grade II spinal ependymomas. *Clin Neurol Neurosurg* 189:105632, 2020
- Chamberlain MC, Tredway TL: Adult primary intradural spinal cord tumors: A review. *Curr Neurol Neurosci Rep* 11:320-328, 2011
- Chen S, Liu Y, Yang J, Liu Q, You H, Dong Y, Lyu J: Development and validation of a nomogram for predicting survival in male patients with breast cancer. *Front Oncol* 9:361, 2019
- Coutant C, Olivier C, Lambaudie E, Fondrinier E, Marchal F, Guillemin F, Seince N, Thomas V, Levêque J, Barranger E, Darai E, Uzan S, Houvenaeghel G, Rouzier R: Comparison of models to predict nonsentinel lymph node status in breast cancer patients with metastatic sentinel lymph nodes: A prospective multicenter study. *J Clin Oncol* 27:2800-2808, 2009
- Delgado-López PD, Corrales-García EM, Alonso-García E, García-Leal R, González-Rodríguez R, Araus-Galdós E, Martín-Alonso J: Central nervous system ependymoma: Clinical implications of the new molecular classification, treatment guidelines and controversial issues. *Clin Transl Oncol* 21:1450-1463, 2019
- Ellison DW, Kocak M, Figarella-Branger D, Felice G, Catherine G, Pietsch T, Frappaz D, Massimino M, Grill J, Boyett JM, Grundy RG: Histopathological grading of pediatric ependymoma: Reproducibility and clinical relevance in European trial cohorts. *J Negat Results Biomed* 10:7, 2011
- Gilbert MR, Ruda R, Soffiotti R: Ependymomas in adults. *Curr Neurol Neurosci Rep* 10:240-247, 2010
- Godfraind C, Kaczmarek JM, Kocak M, Dalton J, Wright KD, Sanford RA, Boop FA, Gajjar A, Merchant TE, Ellison DW: Distinct disease-risk groups in pediatric supratentorial and posterior fossa ependymomas. *Acta Neuropathol* 124:247-257, 2012
- Hanley JA, McNeil BJ: The meaning and use of the area under a receiver operating characteristic (ROC) curve. *Radiology* 143:29-36, 1982
- Harrell FE Jr, Lee KL, Mark DB: Multivariable prognostic models: Issues in developing models, evaluating assumptions and adequacy, and measuring and reducing errors. *Stat Med* 15:361-387, 1996
- Karikari IO, Nimjee SM, Hodges TR, Cutrell E, Hughes BD, Powers CJ, Mehta AI, Hardin C, Bagley CA, Isaacs RE, Haglund MM, Friedman AH: Impact of tumor histology on resectability and neurological outcome in primary intramedullary spinal cord tumors: A single-center experience with 102 patients. *Neurosurgery* 68:188-197; discussion 197, 2011
- Khatua S, Ramaswamy V, Bouffet E: Current therapy and the evolving molecular landscape of paediatric ependymoma. *Eur J Cancer* 70:34-41, 2017
- Korshunov A, Witt H, Hielscher T, Benner A, Remke M, Ryzhova M, Milde T, Bender S, Wittmann A, Schöttler A, Kulozik AE, Witt O, von Deimling A, Lichter P, Pfister S: Molecular staging of intracranial ependymoma in children and adults. *J Clin Oncol* 28:3182-3190, 2010
- Lee SH, Chung CK, Kim CH, Yoon SH, Hyun SJ, Kim KJ, Kim ES, Eoh W, Kim HJ: Long-term outcomes of surgical resection with or without adjuvant radiation therapy for treatment of spinal ependymoma: A retrospective multicenter study by the Korea Spinal Oncology Research Group. *Neuro Oncol* 15:921-929, 2013
- Mansur DB, Perry A, Rajaram V, Michalski JM, Park TS, Leonard JR, Luchtman-Jones L, Rich KM, Grigsby PW, Lockett MA, Wahab SH, Simpson JR: Postoperative radiation therapy for grade II and III intracranial ependymoma. *Int J Radiat Oncol Biol Phys* 61:387-391, 2005
- Martini A, Cumarasamy S, Beksac AT, Abaza R, Eun DD, Bhandari A, Hemal AK, Porter JR, Badani KK: A nomogram to predict significant estimated glomerular filtration rate reduction after robotic partial nephrectomy. *Eur Urol* 74:833-839, 2018
- McGuire CS, Sainani KL, Fisher PG: Both location and age predict survival in ependymoma: A SEER study. *Pediatr Blood Cancer* 52:65-69, 2009
- McLaughlin MP, Marcus RB Jr, Buatti JM, McCollough WM, Mickle JP, Kedar A, Maria BL, Million RR: Ependymoma: Results, prognostic factors and treatment recommendations. *Int J Radiat Oncol Biol Phys* 40:845-850, 1998
- Nazar GB, Hoffman HJ, Becker LE, Jenkin D, Humphreys RP, Hendrick EB: Infratentorial ependymomas in childhood: Prognostic factors and treatment. *J Neurosurg* 72:408-417, 1990

20. Nowak J, Seidel C, Pietsch T, Alkonyi B, Fuss TL, Friedrich C, von Hoff K, Rutkowski S, Warmuth-Metz M: Systematic comparison of MRI findings in pediatric ependymblastoma with ependymoma and CNS primitive neuroectodermal tumor not otherwise specified. *Neuro Oncol* 17:1157-1165, 2015
21. Pajtler KW, Witt H, Sill M, Jones DT, Hovestadt V, Kratochwil F, Wani K, Tatevossian R, Punchedewa C, Johann P, Reimand J, Warnatz HJ, Ryzhova M, Mack S, Ramaswamy V, Capper D, Schweizer L, Sieber L, Wittmann A, Huang Z, van Sluis P, Volckmann R, Koster J, Versteeg R, Fuhs D, Toledano H, Avigad S, Hoffman LM, Donson AM, Foreman N, Hewer E, Zitterbart K, Gilbert M, Armstrong TS, Gupta N, Allen JC, Karajannis MA, Zagzag D, Hasselblatt M, Kulozik AE, Witt O, Collins VP, von Hoff K, Rutkowski S, Pietsch T, Bader G, Yaspo ML, von Deimling A, Lichter P, Taylor MD, Gilbertson R, Ellison DW, Aldape K, Korshunov A, Kool M, Pfister SM: Molecular classification of ependymal tumors across all CNS compartments, histopathological grades, and age groups. *Cancer Cell* 27:728-743, 2015
22. Paulino AC, Wen BC: The significance of radiotherapy treatment duration in intracranial ependymoma. *Int J Radiat Oncol Biol Phys* 47:585-589, 2000
23. Pejavar S, Polley MY, Rosenberg-Wohl S, Chennupati S, Prados MD, Berger MS, Banerjee A, Gupta N, Haas-Kogan D: Pediatric intracranial ependymoma: The roles of surgery, radiation and chemotherapy. *J Neuro Oncol* 106:367-375, 2012
24. Raghunathan A, Wani K, Armstrong TS, Vera-Bolanos E, Fouladi M, Gilbertson R, Gajjar A, Goldman S, Lehman NL, Metellus P, Mikkelsen T, Necesito-Reyes MJ, Omuro A, Packer RJ, Partap S, Pollack IF, Prados MD, Robins HI, Soffiatti R, Wu J, Miller CR, Gilbert MR, Aldape KD: Histological predictors of outcome in ependymoma are dependent on anatomic site within the central nervous system. *Brain Pathol* 23:584-594, 2013
25. Rogers L, Puschel J, Spetzler R, Shapiro W, Coons S, Thomas T, Speiser B: Is gross-total resection sufficient treatment for posterior fossa ependymomas? *J Neurosurg* 102:629-636, 2005
26. Rudà R, Gilbert M, Soffiatti R: Ependymomas of the adult: Molecular biology and treatment. *Curr Opin Neurol* 21:754-761, 2008
27. Rudà R, Reifenberger G, Frappaz D, Pfister SM, Laprie A, Santarius T, Roth P, Tonn JC, Soffiatti R, Weller M, Moyal EC: EANO guidelines for the diagnosis and treatment of ependymal tumors. *Neuro Oncol* 20:445-456, 2018
28. Schiffer D, Chiò A, Giordana MT, Migheli A, Palma L, Pollo B, Soffiatti R, Tribolo A: Histologic prognostic factors in ependymoma. *Childs Nerv Syst* 7:177-182, 1991
29. Schiffer D, Dutto A, Cavalla P, Bosone I, Chiò A, Villani R, Bellotti C: Prognostic factors in oligodendroglioma. *Can J Neurol Sci* 24:313-319, 1997
30. Schüller P, Schäfer U, Micke O, Willich N: Radiotherapy for intracranial and spinal ependymomas. A retrospective analysis. *Strahlenther Onkol* 175:105-111, 1999
31. Schwartz TH, Kim S, Glick RS, Bagiella E, Balmaceda C, Fetell MR, Stein BM, Sisti MB, Bruce JN: Supratentorial ependymomas in adult patients. *Neurosurgery* 44:721-731, 1999
32. Stauder MC, Ni Laack N, Ahmed KA, Link MJ, Schomberg PJ, Pollock BE: Stereotactic radiosurgery for patients with recurrent intracranial ependymomas. *J Neuro Oncol* 108:507-512, 2012
33. Wallner KE, Wara WM, Sheline GE, Davis RL: Intracranial ependymomas: Results of treatment with partial or whole brain irradiation without spinal irradiation. *Int J Radiat Oncol Biol Phys* 12:1937-1941, 1986
34. Wang C, Yuan X, Zuo J: Individualized prediction of overall survival for primary intramedullary spinal cord grade ii/iii ependymoma. *World Neurosurg* 143:e149-e156, 2020
35. Wani K, Armstrong TS, Vera-Bolanos E, Raghunathan A, Ellison D, Gilbertson R, Vaillant B, Goldman S, Packer RJ, Fouladi M, Pollack I, Mikkelsen T, Prados M, Omuro A, Soffiatti R, Ledoux A, Wilson C, Long L, Gilbert MR, Aldape K: A prognostic gene expression signature in infratentorial ependymoma. *Acta Neuropathologica* 123:727-738, 2012
36. Louis DN, Perry A, Wesseling P, Brat DJ, Cree IA, Figarella-Branger D, Hawkins C, Ng HK, Pfister SM, Reifenberger G, Soffiatti R, von Deimling A, Ellison DW: The 2021 WHO Classification of Tumors of the Central Nervous System: a summary. *Neuro-oncology* 23:1231-1251, 2021
37. West CR, Bruce DA, Duffner PK: Ependymomas. Factors in clinical and diagnostic staging. *Cancer* 56:1812-1816, 1985
38. Wolbers M, Koller MT, Wittteman JC, Steyerberg EW: Prognostic models with competing risks: Methods and application to coronary risk prediction. *Epidemiology* 20:555-561, 2009
39. Yuh EL, Barkovich AJ, Gupta N: Imaging of ependymomas: MRI and CT. *Child's Nerv Syst* 25:1203-1213, 2009