



The Matrix Metalloproteinase Inhibitor Batimastat Reduces Epidural Fibrosis After Laminectomy in Rats

Ziya YURTAL¹, Huseyin OZKAN², Tuncer KUTLU³, Mehmet Zeki Yilmaz DEVECİ¹, Boran URFALI⁴, Senem URFALI⁵

¹Hatay Mustafa Kemal University Faculty of Veterinary Medicine, Department of Surgery, Hatay, Turkey

²Hatay Mustafa Kemal University Faculty of Veterinary Medicine, Department of Genetics, Hatay, Turkey

³Hatay Mustafa Kemal University Faculty of Veterinary Medicine, Department of Pathology, Hatay, Turkey

⁴Hatay Mustafa Kemal University Faculty of Medicine, Department of Neurosurgery, Hatay, Turkey

⁵Hatay Mustafa Kemal University Faculty of Medicine, Department of Anaesthesia and Reanimation, Hatay, Turkey

Corresponding author: Ziya YURTAL ✉ ziyayurtal@gmail.com

ABSTRACT

AIM: To investigate the efficacy of locally applied batimastat after laminectomy in preventing postoperative epidural fibrosis.

MATERIAL and METHODS: Thirty-two Wistar albino male rats weighing 200–250 g were used. The rats were assigned to four different groups (I-Control group, II-sham group, III-Laminectomy+Batimastat group, and IV-Laminectomy+Spongostan™ group). The rats were euthanized 28 days after surgery before TNF- α , IL6, IL-1 β , IL10, TGF- β 1, and MMP9 gene expression levels of tissue in the surgical area were determined with qPCR. TNF- α , IL6, and IL10 protein levels were also measured in both tissue and plasma. In addition, the surgical area was evaluated by histopathological and immunohistochemical methods.

RESULTS: TNF- α , IL6, and IL-1 β gene expression levels were higher in the batimastat group than in the control group. Whereas IL10 gene expression levels increased about two-fold in the sham and Spongostan™ groups, in the batimastat group, it was similar to that in the control group. TGF- β 1 gene expression was three-fold higher in the sham group but was similar to that in the control group in both batimastat and Spongostan™ groups. MMP9 gene expression levels significantly decreased only in the batimastat group. In addition, fibrosis score, fibroblast cell count, inflammatory cell count, and CD105 expression decreased in the batimastat group relative to the control.

CONCLUSION: Molecular and pathological examination results suggested that batimastat is an effective agent in reducing the occurrence of epidural fibrosis after laminectomy.

KEYWORDS: Batimastat, CD105, Epidural fibrosis, Postlaminectomy Syndrome, Laminectomy

INTRODUCTION

Epidural fibrosis (EF) is a major cause of postlaminectomy syndrome or “failed back surgery syndrome” (FBSS), which may occur after spinal surgical interventions (42). It reduces the quality of life, and is characterized by persistent back/low back pain and radicular leg pain (42). FBSS develops in 4 to 50% of cases after lumbar spinal surgery (40). Spinal surgical interventions are repeated to improve symptoms

after FBSS, and the success rates decrease to 30% in the second, 15% in the third, and 5% in the fourth of the recurrent surgeries (12).

EF is a regenerative process characterized by the formation of extradural fibrous tissue after spinal surgery (5,17). In this process, tension and/or compression occurs on the nerve roots and/or dura mater, and as a result of this histopathological condition, permanent back/low back pain and leg pain may

Ziya YURTAL : 0000-0001-6080-1860
Huseyin OZKAN : 0000-0001-5753-8985
Tuncer KUTLU : 0000-0002-8771-1256

Mehmet Zeki Yilmaz DEVECİ : 0000-0002-9532-247X
Boran URFALI : 0000-0003-2854-6833
Senem URFALI : 0000-0003-4500-2408

occur (4,8,25). It was first defined as laminectomy membrane by LaRocca and Macnab (15) in 1974.

Fibrosis is a primary connective tissue lesion characterized by an increase in fibrillar extracellular matrix components in the tissue or organ. Matrix metalloproteinases (MMPs) are a large group of proteases that regulate the turnover of the extracellular matrix (33). The most important factor in the development of EF is the excessive deposition of extracellular matrix elements and the resultant decreased tissue cellularity (16,27,29,35). Metalloproteinase also mediate many diseases such as cancer, atheroma, arthritis, atherosclerosis, aneurysms, nephritis, tissue ulcers, and fibrosis. Therefore, metalloproteinase inhibitors play an important role in alleviating pathological effects (34).

EF is a complex process in which inflammation and fibrosis progress together. Various cytokines and growth factors play a role in the initiation and progression of fibrosis (27,34,49). Production of the transforming growth factor- β 1 (TGF- β 1) is one of the important factors in the development of EF (45). Interleukin 1-beta (IL-1 β) is a cytokine that plays important roles in inflammation and fibrosis. This cytokine is produced by activated monocytes, macrophages, and dendritic cells. Interleukin 1-beta induces the production of cytokines such as tumor necrosis factor-alpha (TNF- α) and interleukin-6 (IL-6), and proteases such as MMPs, which are mainly associated with proliferation of fibroblasts (33). Interleukin 1-beta and IL-6 contribute to regulation of proliferation and extracellular synthesis of fibroblasts (18). MMPs play an important role in the remodeling process of connective tissue in both physiological and pathological conditions and in the regulation of the extracellular matrix cycle in fibrotic tissues (14,17,20). MMPs are effective in inflammatory cell infiltration, smooth muscle cell migration and proliferation, collagen production, and fibroblast contraction. Specifically, TGF- β 1, which is a profibrotic agent, is converted from its precursor form to its active form through MMP-2, MMP-3, MMP-9, MMP-13, MMP-30 (22). MMP-9 increases the inflammatory response and fibrosis (14).

Therapeutic effects of many agents have been investigated in studies on EF. Batimastat, also known as BB-94 and used in the treatment of cancer, is a synthetic MMP enzyme inhibitor that inhibits the activities of most MMPs (11,34). Batimastat has a collagen-like backbone that facilitates binding to the active site of MMP. It potently and specifically inhibits MMPs (44), and like other MMP inhibitors, has a potent anti-angiogenic activity (1,23,41). Batimastat is not preferred for systemic use due to a multiplicity of its side effects and low solubility. Thus, it is used by injecting into body cavities (2,31).

Many previous studies have tried to elucidate the mechanism of formation of EF and potential treatment options. However, no study has, so far, looked at effects of batimastat on EF. Therefore, this study aimed to investigate the effects of batimastat, a synthetic MMP enzyme inhibitor, on the formation of EF at molecular, immunohistochemical, and histopathological levels.

■ MATERIAL and METHODS

This *in vivo* study was approved by the Hatay Mustafa Kemal University (HMKU) Animal Experiments Local Ethics Committee (dated 19/02/2020 and decision no: 2020/02-9). Thirty-two rats obtained from HMKU Experimental Research Application and Research Center were divided into four groups and the living conditions in the routine program of the unit were provided. The rats were housed at 22°C \pm 2°C room temperature under 12-hour night and 12-hour day conditions. Food and water were provided *ad libitum*. Before starting the experimental treatments, the animals were adapted to the environment for one week. Groups were formed in such a way that there was no significant difference in mean body weight of the rats to be used in the study (200–250 g). The animals were divided into the following four groups. Group I (Control group): the rats in this group received no treatment; they were housed in the routine conditions of the unit. II. Sham group: The rats in this group underwent laminectomy, and they received no treatment afterwards. Group III (Laminectomy+Batimastat group): local batimastat (30 mg/kg, BB-94, Cat no: MBS384336, MYBIOSOURCE) was administered to rats in this group after laminectomy (43). Group IV (Laminectomy+Spongostan™ group): the rats in this group underwent laminectomy and received 2 ml/kg saline-impregnated Spongostan™ (27). In all groups, intracardiac blood was collected for analysis under anesthesia on the 28th day after the surgical procedure, and the rats were sacrificed. Tissue samples were taken from the surgical area.

Anesthesia and Surgical Procedure

For general anesthesia, 10 mg/kg Xylazine hydrochloride (ip) and 50 mg/kg Ketamine hydrochloride (ip) were administered to the rats in all groups that would undergo surgical procedure. The surgical field of the rats was shaved and the area was disinfected with povidone iodine. We performed a midline skin incision on L3-L5 before we dissected the paravertebral muscles and reached the laminae of L3-L5. We performed total laminectomy at the L3 level using the operating microscope ensuring that the total laminectomy did not compromise the integrity of the dura mater (Figure 1). After the procedure, we applied sterilized local batimastat (30 mg/kg) to the batimastat group, 2 ml/kg of saline-impregnated Spongostan™ to the Spongostan™ group, and closed the area with 4/0 polypropylene surgical thread.

Molecular Analysis, RNA Isolation, and cDNA Synthesis

After blood samples were centrifuged at 3000 xg for 10 min, plasma samples were transferred into 1.5 ml nuclease-free tubes and stored at -86°C until protein analysis. Tissues taken after euthanasia were transferred to nuclease-free tubes and quickly frozen in liquid nitrogen. The samples were stored at -86°C until molecular analysis. Total RNA isolation from samples was performed using the modified Trizol method (32). For this purpose, approximately 50 mg of tissue from each sample was homogenized in 1 ml of Trizol. The total RNAs obtained after trizol-chloroform-isopropyl alcohol and ethyl alcohol steps were diluted using 30 to 100 μ l of nuclease-free water depending on the pellet size. The

purity and concentration of the isolated total RNA for each sample were measured with a nucleic acid meter (Merinton SMA 1000). In addition, the quality of RNA was checked using electrophoresis at 100V and 25 min. The RNA isolation was reperformed for the inappropriate samples.

Possible DNA contamination in the samples was eliminated through DNA digestion (DNase I, RNase free, ThermoFischer Scientific, USA). We performed cDNA synthesis following the protocol in the high capacity cDNA synthesis kit

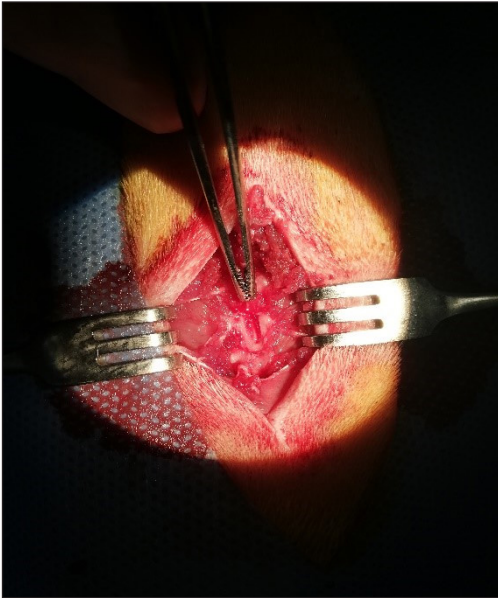


Figure 1: Laminectomy performed at L3 level.

(ThermoFischer Scientific, USA). Thermo-cylce reaction conditions for cDNA synthesis were set as follows: 60 min at 42°C, 5 min at 25°C, and 5 min at 70°C. After the reaction, the volume of each cDNA sample was made up to a final volume of 200 µL and the samples were stored at -86°C until gene expression analysis.

qPCR Application and Gene Expression Analyzes

Gene expression levels of *TNF-α*, *IL6*, *IL-1β*, *IL10*, *TGF-1β* and *MMP9* in the samples were determined using qPCR (Rotorgene Qiagen, USA). After 10 min of denaturation, the qPCR protocol was set as follows: 40 cycles at 95°C for 15 seconds and at 60°C for 60 s. A kit containing SYBR Green dye was used for amplification (Power SYBR Green PCR Master Mix, ThermoFischer Scientific, USA). *ACTB* and *PPIA* housekeeping genes indicated in Table I were used for internal control.

ELISA Application

The *TNF-α*, *IL6*, and *IL10* protein levels in tissue and plasma samples were determined by ELISA method. After the tissues stored at -86°C were homogenized in Phosphate Buffered Saline (PBS), total protein analyzes were performed according to the Lowry method (19). Levels of related proteins were measured using rat specific ELISA kits (Bioassay Technology Laboratory, China, E0764Ra, E0135Ra, E0108Ra). Finally, the content of targeted proteins in tissues was calculated as ng/mg protein.

Histopathological Examination

After euthanasia, the vertebrae, paraspinal muscles, and epidural scar tissue in the operative field were removed and

Table I. Forward and Reverse Sequences of Target and Housekeeping Genes

Genes	Forward and Reverse Primer Sequences	Reference
PPIA	F: 5'-CAGACAAAGTTCCAAAGACAGCA-3' R: 5'-CACCTGGCACATGAATCCT-3'	Dos Santos et al. (9).
ACTB	F: 5'-GCAGGAGTACGATGAGTCCG-3' R: 5'-ACGCAGCTCAGTAACAGTCC-3'	Ozkan and Kerman (26).
TNF-α	F: 5'-ACTGAACTTCGGGGTGATCG-3' R: 5'-GCTTGGTGGTTTGCTACGAC-3'	*
IL6	F: 5'-CTCTCCGCAAGAGACTTCCA-3' R: 5'-TCTCCTCTCCGGACTTGTGAA-3'	*
IL-1β	F: 5'-ACAAGGAGAGACAAGCAACGAC-3' R: 5'-TCTTCTTTGGGTATTGTTTGGG-3'	Castro et al. (3).
IL10	F: 5'-TTGAACCACCCGGCATCTAC-3' R: 5'-CCAAGGAGTTGCTCCCGTTA-3'	*
MMP9	F: 5'-CTGTATGGTCGTGGCTCTAAAC-3' R: 5'-GAGGTGCAGTGGGACACATAG-3'	Yin et al. (47).
TGF-β1	F: 5'-TGACGTCACCTGGAGTTGTCC-3' R: 5'-CCTCGACGTTTGGGACTGAT-3'	*

*: Designed by the authors.

fixed in 10% buffered formalin before they were decalcified in an equal amount of 8% Hidrojen klorür (HCl) and 8% formic acid solution for one day. According to routine methods, after alcohol and xylol series, they were embedded in paraffin and the sections taken at 5 µm intervals were deparaffinized in xylol. After passing through 100, 96, 80, and 70 alcohol series, they were stained with Hematoxylin-Eosin (H&E). In addition, Masson's trichrome staining was performed for connective tissue. After examining under a light microscope (Olympus CX31), microphotographs (Olympus DP12) were taken.

The grade of fibrosis tissue was evaluated as follows: Grade 0 means no scar tissue in the dura mater; Grade I means thin fibrous bands between the scar tissue and the dura mater; Grade II means adhesions in <2/3 of the laminectomy defect; Grade III means extensive scar tissue affecting >2/3 of the laminectomy defect (13).

Fibroblast and inflammatory cell counts were determined based on the average of a total of three areas in each sample, including one area at the center of the laminectomy and two areas at the margins. The grading system for fibroblast and inflammatory cell counts was as follows: Grade I, <100 fibroblasts/inflammatory cells per 400x area; Grade II, 400 × 100-150 fibroblasts/inflammatory cells per area; Grade III: 400 × >150 fibroblasts/inflammatory cells per area (46).

Immunohistochemical Examination

To detect *CD105* expression in tissues, the Avidin Biotin Peroxidase Complex technique was performed following the standard procedure prescribed in the commercial kit (SensiTek HRP, ScyTek Laboratories, Logan, UT). The anti-CD105 antibody [8A1] (ab230925) (60 min/45°) (dilution ratio 1/50) was used as a primary antibody. A 3% H₂O₂ methanol solution was used to block endogenous peroxidase activity. Proteinase K was used for antigen retrieval (Abcam, ab64220) and PBS was applied to the tissues as a negative control. 3,3'-diaminobenzidine tetrahydrochloride (DAB, ScyTek Laboratories, Logan, UT) was used as chromogen. For background staining, Harris hematoxylin was applied. Immunohistochemical grading was made following instructions in Erdogan et al. (10) and Yilmaz et al. (46).

Each slide was graded according to the number of vessels in each hotspot as follows: ≤3 corresponds to Grade 1; 3 to 6 corresponds to Grade 2; ≥7 corresponds to Grade 3. Vessels with a muscle layer were not considered as newly formed vessels and were not included in the count. The mean number of vessels in the three hotspots for each slide was defined as the microvessel density in each animal (10,46).

Statistical Analysis

One-way analysis of variance (ANOVA) used to test for significant differences in protein levels between treatment groups. The Tukey post-hoc test was used to perform pairwise comparisons of protein levels. Gene expression results were analyzed following the method reported by Livak and Schmittgen (18). Geometric means of housekeeping genes were calculated and the results were shown as fold change. $P < 0.05$ was considered significant.

RESULTS

In the postoperative period, no infection was observed in the skin, subcutaneous, and laminectomy areas in any rat.

Gene Expression Results

Purity (1.90 ± 0.02) and concentration (430.62 ± 37.19 ng/µl) values of isolated RNAs were suitable for cDNA conversion and gene expression analyzes. There were significant differences in the expression levels of the genes whose activity was investigated in this study (Table II). The *TNF-α* gene expression levels showed three-fold upregulation in all sham, batimastat, and Spongostan™ groups compared to the control group ($p < 0.05$). The *IL6* gene was approximately three-fold upregulated in the sham group, and the batimastat group was two-fold upregulated in the batimastat group compared to the control ($p < 0.05$). *IL6* gene expression levels in the Spongostan™ group were similar to those in the control group. There was significant increase in the *IL-1β* gene expression levels in all experimental groups. The highest upregulation for this gene was in the batimastat group with approximately five-fold upregulation ($p < 0.05$). The *IL10* gene expression levels were upregulated approximately two-fold in the sham and Spongostan™ groups, whereas they were similar in the batimastat and control groups. *TGF-β1* gene was expressed three-fold more in the sham group than in the control. *TGF-β1* gene expression levels in both batimastat and Spongostan™ groups were similar to those in the control group. *MMP9* gene expression levels were downregulated only in the batimastat group compared to the control ($p < 0.05$).

ELISA Results

Targeted protein levels were detected with ELISA. Whereas tissue *TNF-α* protein levels were similar in the sham and batimastat group and significantly higher than in the control group ($p < 0.01$), the Spongostan™ group was at similar levels to the control and other experimental groups. The highest *IL6* protein levels were recorded in the sham group. *IL6* levels closest to those of the control group were in the Spongostan™ group. The highest levels of *IL10* were recorded in the batimastat group but the levels in the sham and Spongostan™ groups were similar to those in both the control and batimastat group.

The *TNF-α*, *IL6*, and *IL10* levels recorded in the plasma and tissue in the groups were as follows (Table III, IV): whereas plasma *IL10* protein levels were similar between the groups, the sham group had the highest *TNF-α* and *IL6* levels ($p < 0.05$). However, *TNF-α* and *IL6* levels in the other groups were similar to those in the control group (Table IV).

Histopathological and Immunohistochemical Results

Scoring of histopathological and immunohistochemical results is presented in Table V. In the histopathological examination, the spinal cord and its surroundings were in normal histological structure in the control group. In the sham group, adhesions formed almost completely between the connective tissue of the laminectomy region and the dura mater in most of the rats, and the fibrosis score was at Grade 3 (Figure 2A, 2B). Fibroblast and inflammatory cell infiltration were at Grade 1 in

Table II: Gene expression results (Mean±SEM)

Genes	Control	Sham	Batimastat	Spongostan™
TNF-α	1.00 ± 0.43	2.38 ± 0.42*	2.79 ± 0.56*	2.80 ± 0.43*
IL6	1.00 ± 0.21	3.15 ± 0.80*	1.99 ± 0.31*	1.14 ± 0.16
IL-1β	1.00 ± 0.23	2.36 ± 0.26**	5.64 ± 1.68*	1.71 ± 0.08*
IL10	1.00 ± 0.17	1.80 ± 0.18*	1.88 ± 0.37	1.98 ± 0.34*
TGF-β1	1.00 ± 0.33	2.92 ± 0.70*	1.49 ± 0.38	1.66 ± 0.11
MMP9	1.00 ± 0.27	2.01 ± 1.06	0.44 ± 0.09*	1.87 ± 0.72

*: $p < 0.05$, **: $p < 0.01$, Results are given as fold change compared with the control group.

Table III: Tissue Levels of Target Proteins in Groups (ng/mg protein)

Protein	Control	Sham	Batimastat	Spongostan™	p
TNF-α	20.66 ± 1.88 ^b	31.79 ± 2.53 ^a	30.91 ± 1.97 ^a	28.98 ± 2.45 ^{a,b}	<0.01
IL6	1.63 ± 0.19 ^c	3.25 ± 0.30 ^a	2.59 ± 0.09 ^{a,b}	2.16 ± 0.17 ^{b,c}	<0.001
IL10	35.00 ± 2.35 ^b	39.81 ± 3.15 ^{a,b}	44.09 ± 1.56 ^a	38.07 ± 1.23 ^{a,b}	<0.05

^{a, b, c}: Different letters on the same lines indicate significant difference between groups.

Table IV: Plasma Levels of Target Proteins in Groups (ng/ml)

Protein	Control	Sham	Batimastat	Spongostan™	p
TNF-α	23.82 ± 1.57 ^b	33.61 ± 2.40 ^a	29.25 ± 3.16 ^{ab}	25.12 ± 2.29 ^{ab}	<0.05
IL6	3.27 ± 0.17 ^b	3.75 ± 0.14 ^a	3.23 ± 0.18 ^b	3.69 ± 0.14 ^{ab}	<0.05
IL10	57.64 ± 2.12	56.01 ± 1.91	54.95 ± 1.49	59.35 ± 2.32	-

^{a, b, c}: Different letters on the same lines indicate significant difference between groups.

Table V: Grading of Epidural Fibrosis Based on Fibrosis Score, Fibroblast and Inflammatory Cell Counts and CD105 by Immunohistochemistry

	Control	Sham	Batimastat	Spongostan™
Fibrosis score				
Grade 0	8	0	0	0
Grade 1	0	0	1	2
Grade 2	0	2	3	2
Grade 3	0	6	4	4
Fibroblast count				
Grade 1	8	4	8	8
Grade 2	0	3	0	0
Grade 3	0	1	0	0
Inflammatory Cell Count				
Grade 1	8	6	8	8
Grade 2	0	2	0	0
Grade 3	0	0	0	0
CD105				
Grade 1	8	0	2	0
Grade 2	0	0	4	4
Grade 3	0	8	2	4

most animals in this group, but Grade 2 and Grade 3 in some animals (Figure 2C). In the batimastat and Spongostan™ groups, fibrosis, fibroblast, and inflammatory cell infiltration density decreased (Figure 2D).

Using CD105 antibody immunohistochemically, angiogenesis developed in fibrosis was examined. Grade 3 positivity was noted in all animals in the sham group (Figure 3A, 3B). On the other hand, in the batimastat and Spongostan™ groups, it was at Grade 1 or Grade 2 in some of them, and Grade 3 in others.

DISCUSSION

Medical treatments and revision surgeries due to EF after spinal surgery cause serious socio-economic problems. Many experimental and clinical studies are in progress and many potential agents are being tested to clarify the pathogenesis of this clinical phenomenon and to treat it (30,36,38). In this study, batimastat, a broad-spectrum MMP inhibitor, was used to prevent EF after laminectomy.

Kumar et al. reported that some MMPs also play critical roles in some physiological processes and that long-term and

systemic inhibition of MMPs may lead to harmful side effects (14). They further reported that the agents should be used only by targeting the affected tissues in order to avoid side effects. Intravenous and oral administration of batimastat is not recommended as it may have serious side effects (31). Based on these findings, batimastat was applied locally in this study.

Wojtowicz-Praga et al. reported that batimastat remained at effective doses in plasma for a long time (4 weeks) in phase-1 cancer studies (44), whereas Parsons et al. reported that this period was up to 6 weeks in phase I/II cancer studies (28). Macaulay et al. reported batimastat in the plasma 1 hour after intrapleural administration, reaching a peak value between 4 hours and 1 week, and a longer persistence in the plasma (21). Rajpal et al. reported that EF begins within 2–3 weeks (30). In the light of this information, the effects of batimastat on the formation of EF after a 4-week period were examined in this study.

Batimastat limits fibrosis (6,14). Robert et al. reported that the use of MMP inhibitors can be a therapeutic strategy (33), especially in the prevention of remodeling and fibrosis, and the interest in this is becoming increasingly important. Based

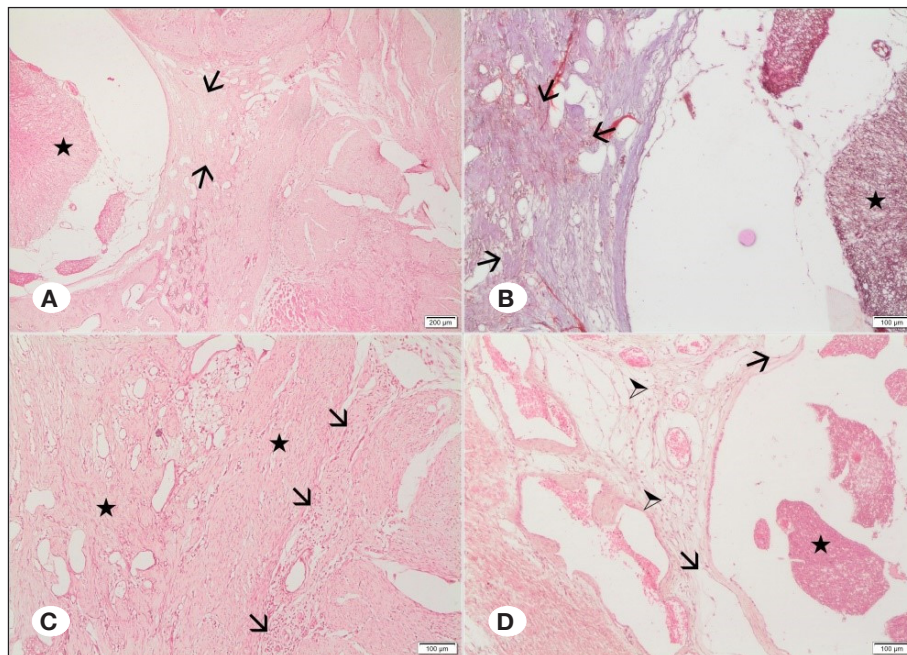


Figure 2: Histopathological examination of tissue sections. **A)** Grade III fibrosis (arrows); Adhesions more than two thirds of the laminectomy defect and spinal cord (star) in sham group, HE, x40. **B)** Grade III fibrosis (arrows) and spinal cord (star) in sham group, Masson's trichrome, x100. **C)** Grade II fibroblasts (stars) and inflammatory cells (arrows) in sham group, HE, x100. **D)** Grade II fibrosis (arrowheads); Adhesions less than two thirds of the laminectomy defect (arrows) and spinal cord (star) in group III (Lam+Bat), HE, x100.

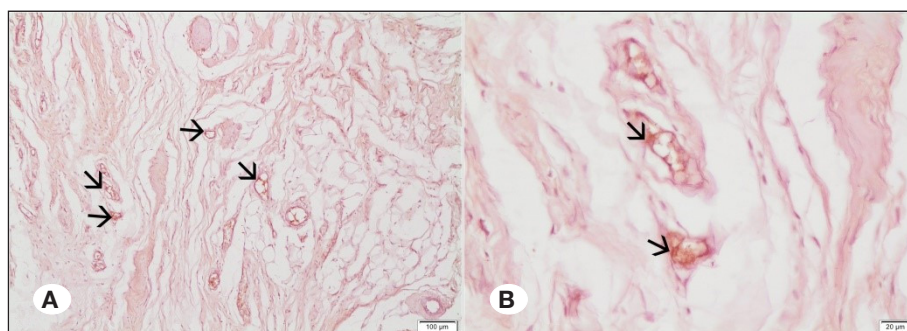


Figure 3: Immunohistochemical staining for CD105. **A)** Grade III; CD105 stained vessels (arrows) in Grade III fibrosis in sham group, x100. **B)** Higher magnification of CD105 stained vessels (arrows) in Grade III fibrosis in sham group, x400.

on these findings, this study investigated the effectiveness of batimastat, one of the MMP inhibitors, in the prevention of EF.

Parsons et al. stated that intraperitoneally administered batimastat in phase I/II cancer studies caused abdominal pain and that this might be the result of an inflammatory response to batimastat (28). Wojtowicz-Praga et al. reported one case of chemical peritonitis in their study (44). High levels of proinflammatory cytokines *TNF- α* , *IL-1 β* , and *IL6* in this study also support that batimastat may cause an inflammatory response. Moore et al. reported that batimastat reduces aortic wall inflammation and this may be independent of *TNF- α* (24). In this study, *TNF- α* was high both at the gene and protein levels.

MMP-9 is associated with angiogenesis, and batimastat is a potent MMP inhibitor (7,39). *MMP-9* is secreted by epithelial cells, fibroblasts, polymorphonuclear leukocytes, granulocytes, neutrophils, macrophages, T cells, osteoblasts, dendritic cells, and keratinocytes (7). Kumar et al. found that genetic ablation of *MMP-9* significantly reduced the inflammatory response and fibrosis (14). In another study, they reported that batimastat significantly downregulated the *MMP-9* gene (48). In this study, batimastat downregulated the *MMP-9* gene (Table II, $p < 0.05$). These findings suggest that batimastat gives more effective results than Spongostan™ in reducing inflammation and fibrosis.

In studies on EF, fibrosis density and lesions such as inflammatory cell infiltration were evaluated histopathologically (27,37). In our study, fibrosis score, fibroblast count and inflammatory cell infiltration density were graded histopathologically. Histopathological examination showed that batimastat decreased the number of inflammatory cells, which is its mode of anti-inflammatory activity. On the other hand, molecular analyzes showed that the batimastat group increased significantly the *IL10* gene, which plays an essential role in anti-inflammatory response (Table III, $p < 0.05$). These findings suggest that batimastat is a more effective anti-inflammatory agent than Spongostan™.

MMPs play an important role in the remodeling of connective tissue and in the regulation of the extracellular matrix cycle in fibrotic tissue in both physiological and pathological conditions (17,20). Various cytokines and growth factors released from inflammatory cells are effective in the initiation and progression of fibrosis (42,49). In a previous study, it was reported that batimastat reduced pulmonary fibrosis independent of *TGF- β 1* (6). Contrary to these views, Yaman et al. emphasized that *TGF- β 1* production is one of the important factors in the development of EF (45). Song et al. also reported an important role of *TGF- β 1* in the development of fibrosis and observed a decrease in EF with the decrease in *TGF- β 1* (36). In this study, *TGF- β 1* level was significantly higher in the sham group than in the control ($p < 0.05$). Batimastat downregulated the *TGF- β 1* gene. Considering that *TGF- β 1* increases fibrosis formation, it may be argued that batimastat contributes more to the reduction of EF than Spongostan™.

CD105 is a membrane glycoprotein that regulates the signaling of *TGF- β 1* and is commonly used to determine microvessel

density proportional to fibrosis in tumors. Previous studies have reported that the *CD105* marker plays a key role in renal and hepatic fibrosis and therefore can be used in the diagnosis of EF (10,38). In this study, *CD105* level was at Grade 3 in all rats in the sham group. *CD105* level was Grade 1 in two rats, Grade 2 in four rats, and Grade 3 in two rats in the batimastat group. Only Grade 2 and Grade 3 rats were detected in the Spongostan™ group. These findings indicate that batimastat reduces *CD105* levels and EF development more effectively than Spongostan™.

■ CONCLUSION

In this study, the development of EF in all rats in the sham group was evaluated by fibrosis score, fibroblast count, inflammatory cell count, and *CD105*. EF was lower in batimastat group than in the sham group. Among the markers used to assess the degree of EF, fibrosis score, fibroblast and inflammatory cell count, and *CD105* expression results were consistent.

Intraperitoneal use of batimastat causes some side effects such as pulmonary embolism, respiratory failure, weakness, vomiting, diarrhea, and edema formation in the legs (28). In this study, although batimastat was applied locally, the ELISA application results in tissue and plasma were similar, indicating that the applied agent reached effective levels in plasma as well (Table III, IV). In addition, in this study, no side effects were encountered after local application of batimastat in rats. These findings show that local applications are as effective as systemic applications, and side effects may be fewer and less severe.

In conclusion, batimastat is a potential effector without any side effects for reducing EF after laminectomy. To the best of our knowledge, this is the first study to investigate the efficacy of batimastat in EF. Because of the limited study in this area with batimastat, further research is needed with different exposure time and doses after laminectomy operations.

■ ACKNOWLEDGMENT

This study was financially supported by the Scientific Research Projects Coordination Unit of Hatay Mustafa Kemal University (Project No. 20.M.029).

■ AUTHORSHIP CONTRIBUTION

Study conception and design: ZY, KK, HÖ, TK, MZYD, BU, SU

Data collection: ZY, KK, HÖ, TK, MZYD, BU, SU

Analysis and interpretation of results: ZY, HÖ, TK, BU

Draft manuscript preparation: ZY, KK, HÖ

Critical revision of the article: ZY, KK, HÖ, TK

Other (study supervision, fundings, materials, etc...): ZY, MZYD, BU, SU

All authors (ZY, HO, TK, MZYD, BU, SU) reviewed the results and approved the final version of the manuscript.

REFERENCES

- Baidya SK, Amin SA, Jha T: Outline of gelatinase inhibitors as anti-cancer agents: A patent mini-review for 2010-present. *Eur J Med Chem* 213:113044, 2020
- Brown PD: Matrix metalloproteinase inhibitors: A novel class of anticancer agents. *Adv Enzyme Regul* 35:293-301, 1995
- Castro MC, Massa ML, Arbeláez LG, Schinella G, Gagliardino JJ, Francini F: Fructose-induced inflammation, insulin resistance and oxidative stress: A liver pathological triad effectively disrupted by lipoic acid. *Life Sci* 137:1-6, 2015
- Cemil B, Tun K, Kaptanoglu E, Kaymaz F, Cevirgen B, Comert A, Tekdemir I: Use of pimecrolimus to prevent epidural fibrosis in a postlaminectomy rat model. *J Neurosurg Spine* 11(6):758-763, 2009
- Clancy C, Quinn A, Wilson F: The aetiologies of failed back surgery syndrome: A systematic review. *J Back Musculoskelet Rehabil* 30(3):395-402, 2017
- Corbel M, Caulet-Maugendre S, Germain N, Molet S, Lagente V, Boichot E: Inhibition of bleomycin-induced pulmonary fibrosis in mice by the matrix metalloproteinase inhibitor batimastat. *J Pathol* 193(4):538-545, 2001
- Das S, Amin SA, Jha T: Inhibitors of gelatinases (MMP-2 and MMP-9) for the management of hematological malignancies. *Eur J Med Chem* 223:113623, 2021
- de Tribolet N, Porchet F, Lutz TW, Gratzl O, Brotchi J, van Alphen HA, van Acker RE, Benini A, Strommer KN, Bernays RL, Goffin J, Beuls EA, Ross JS: Clinical assessment of a novel antiadhesion barrier gel: Prospective, randomized, multicenter, clinical trial of ADCON-L to inhibit postoperative peridural fibrosis and related symptoms after lumbar discectomy. *Am J Orthop (Belle Mead NJ)* 27(2):111-120, 1998
- Dos Santos BP, da Costa Diesel LF, da Silva Meirelles L, Nardi NB, Camassola M: Identification of suitable reference genes for quantitative gene expression analysis in rat adipose stromal cells induced to trilineage differentiation. *Gene* 594:211-219, 2016
- Erdogan U, Tanik C, Tanriverdi O, Gunaldi O, Yilmaz I, Arslanhan A, Ofluoglu AE: Immunohistochemical grading of epidural fibrosis with CD105 antibody. *World Neurosurg* 125:e297-303, 2019
- Escalante T, Franceschi A, Rucavado A, Gutierrez JM: Effectiveness of batimastat, a synthetic inhibitor of matrix metalloproteinases, in neutralizing local tissue damage induced by BaP1, a hemorrhagic metalloproteinase from the venom of the snake *Bothrops asper*. *Biochem Pharmacol* 60(2):269-274, 2000
- Hazard RG: Failed back surgery syndrome: Surgical and nonsurgical approaches. *Clin Orthop Relat Res* 443:228-232, 2006
- He Y, Revel M, Loty B: A quantitative model of post-laminectomy scarformation effects of a nonsteroidal anti-inflammatory drug. *Spine* 20:557-563, 1995
- Kumar A, Bhatnagar S, Kumar A: Matrix metalloproteinase inhibitor batimastat alleviates pathology and improves skeletal muscle function in dystrophin-deficient mdx mice. *Am J Clin Pathol* 177(1): 248-260, 2010
- LaRocca H, Macnab I: The laminectomy membrane. Studies in its evolution, characteristics, effects and prophylaxis in dogs. *J Bone Joint Surg Br* 56B(3):545-550, 1974
- Laurent GJ, Chambers RC, Hill MR, McNulty RJ: Regulation of matrix turnover: Fibroblasts, forces, factors and fibrosis. *Biochem Soc Trans* 35:647-651, 2007
- Lin CL, Jou IM, Wu CY, Kuo YR, Yang SC, Lee JS, Tu YK, Chen SC, Huang YH: Topically applied cross-linked hyaluronan attenuates the formation of spinal epidural fibrosis in a swine model of laminectomy. *Sci Rep* 9(1):1-9, 2019
- Livak KJ, Schmittgen TD: Analysis of relative gene expression data using real-time quantitative PCR and the $2^{-\Delta\Delta CT}$ method. *Methods* 25:402-408, 2001
- Lowry OH, Rosebrough NJ, Farr AL, Randall RJ: Protein measurement with the Folin phenol reagent. *J Biol Chem* 193:265-275, 1951
- Lu P, Takai K, Weaver VM, Werb Z: Extracellular matrix degradation and remodeling in development and disease. *Cold Spring Harb Perspect Biol* 3(12): a005058, 2011
- Macaulay VM, O'Byrne KJ, Saunders MP, Braybrooke JP, Long L, Gleeson, F, Mason CS, Harris AL, Brown P, Talbot DC: Phase I study of intrapleural batimastat (BB-94), a matrix metalloproteinase inhibitor, in the treatment of malignant pleural effusions. *Clin Cancer Res* 5(3):513-520, 1999
- Margulis A, Nocka KH, Wood NL, Wolf SF, Goldman SJ, Kasaian MT: MMP dependence of fibroblast contraction and collagen production induced by human mast cell activation in a three-dimensional collagen lattice. *Am J Physiol Lung Cell Mol Physiol* 296(2):236-247, 2009
- Mitchell MA, Wilk JW: Inhibitors of Angiogenesis. In: JA Bristol (ed). *Annual Reports in Medicinal Chemistry*. Michigan: Academic Press, 1992:140
- Moore G, Liao S, Curci JA, Starcher BC, Martin RL, Hendricks RT, Chen JJ, Thompson RW: Suppression of experimental abdominal aortic aneurysms by systemic treatment with a hydroxamate-based matrix metalloproteinase inhibitor (RS 132908). *J Vasc Surg* 29(3):522-532, 1999
- Ozer AF, Oktenoglu T, Sasani M, Bozkus H, Canbulat N, Karaarslan E, Sungurlu SF, Sarioglu AC: Preserving the ligamentum flavum in lumbar discectomy: A new technique that prevents scar tissue formation in the first 6 months postsurgery. *Oper Neurosurg* 59:126-133, 2006
- Ozkan H, Kerman E: Comparative evaluation of RNAlater solution and snap frozen methods for gene expression studies in different tissues. *Rev Rom Med Lab* 28(3):287-297, 2020
- Ozturk Y, Bozkurt I, Yaman ME, Guvenc Y, Tolunay T, Bayram P, Hayirli N, Billur D, Erbay FK, Senturk S, Bozkurt G: Histopathologic analysis of tamoxifen on epidural fibrosis. *World Neurosurg* 111:941-948, 2018
- Parsons SL, Watson SA, Steele RJ: Phase I/II trial of batimastat, a matrix metalloproteinase inhibitor, in patients with malignant ascites. *EJSO* 23(6):526-531, 1997
- Pheasant H: Sources of failure in laminectomies. *Orthop Clin North Am* 6(1):319-329, 1975
- Rajpal K, Singh J, Bahadur R, Bansal K, Shyam R, Khatri K: Postoperative epidural fibrosis prevention: Which is better—autologous fat versus gelfoam. *Asian Spine J* 10:1-9, 2021

31. Rasmussen H, McCann PP: Matrix metalloproteinase inhibition as a novel anticancer strategy. A review with special focus on batimastat and marimastat. *Pharmacol Ther* 75:69-75, 1997
32. Rio DC, Ares M, Hannon GJ, Nilsen TW: Purification of RNA using TRIzol (TRI reagent). *Cold Spring Harb Protoc* 2010(6):pdb.prot5439, 2010
33. Robert S, Gicquel T, Victoni T, Valença S, Barreto E, Bailly-Maître B, Boichot E, Lagente V: Involvement of matrix metalloproteinases (MMPs) and inflammasome pathway in molecular mechanisms of fibrosis. *Biosci Rep* 36(4):e00360, 2016
34. Shivashankar S, Sangeetha MK: The natural ligand for metalloproteinase-multifaceted drug target. *Appl Biochem Biotechnol* 194(4):1716-1739, 2022
35. Siqueira EB, Kranzler LI, Dharkar DD: Fibrosis of the dura mater. A cause of "failed back" syndrome. *Surg Neurol* 19(2):168-170, 1983
36. Song Z, Wu T, Sun J, Wang H, Hua F, Nicolas YSM, Kc R, Chen K, Jin Z, Liu J, Zhang M: Metformin attenuates post-epidural fibrosis by inhibiting the TGF- β 1/Smad3 and HMGB1/TLR4 signaling pathways. *J Cell Mol Med* 25(7):3272-3283, 2021
37. Tanriverdi O, Erdogan U, Tanik C, Yilmaz I, Gunaldi O, Adilay HU, Arslanhan A, Eseoglu M: Impact of sorafenib on epidural fibrosis: An immunohistochemical study. *World J Clin Cases* 6(9):249-258, 2018
38. Tanriverdi O, Yilmaz I, Adilay HU, Gunaldi O, Erdogan U, Gungor A, Kilic M, Tanik C: Effect of cetuximab on the development of epidural fibrosis based on CD105 and osteopontin immunohistochemical staining. *Spine* 44(3):134-143, 2019
39. Taraboletti G, Garofalo A, Belotti D, Drudis T, Borsotti P, Scanziani E, Brown PD, Giavazzi R: Inhibition of angiogenesis and murine hemangioma growth by batimastat, a synthetic inhibitor of matrix metalloproteinases. *J Natl Cancer Inst* 87(4):293-298, 1995
40. Taylor RS, Taylor RJ: The economic impact of failed back surgery syndrome. *Br J Pain* 6(4):174-181, 2012
41. Townsend D: Batimastat. In: *xPharm: The Comprehensive Pharmacology Reference*. Elsevier, 2007
42. Turkoglu E, Dinc C, Tuncer C, Oktay M, Serbes G, Sekerci Z: Use of decorin to prevent epidural fibrosis in a post-laminectomy rat model. *Eur J Pharmacol* 724:86-91, 2014
43. Wang X, Fu X, Brown PD, Crimmin MJ, Hoffman RM: Matrix metalloproteinase inhibitor BB-94 (batimastat) inhibits human colon tumor growth and spread in a patient-like orthotopic model in nude mice. *Cancer Res* 54(17):4726-4728, 1994
44. Wojtowicz-Praga S, Low J, Marshall J, Ness E, Dickson R, Barter J, Sale M, McCann P, Moore J, Cole A, Hawkins MJ: Phase I trial of a novel matrix metalloproteinase inhibitor batimastat (BB-94) in patients with advanced cancer. *Invest New Drugs* 14(2):193-202, 1996
45. Yaman ME, Ergul G, Guvenc Y, Ozturk Y, Erbay FK, Tolunay T, Senturk S, Kircil C, Bozkurt G: Evaluation of topical Dexmedetomidine administration in postlaminectomy epidural fibrosis rat model. *Int J Surg* 53:80-85, 2018
46. Yilmaz I, Erdogan U, Tanriverdi O, Gunaldi O, Adilay HU, Omeroglu M, Tanik C, Tugcu B: Evaluation of bevacizumab for the treatment of epidural fibrosis by immunohistochemical staining for CD105 and osteopontin. *Turk Neurosurg* 28(6):954-962, 2018
47. Yin L, Li F, Li J, Yang X, Xie X, Xue L, Li Y, Zhang C: Chronic intermittent ethanol exposure induces upregulation of matrix metalloproteinase-9 in the rat medial prefrontal cortex and hippocampus. *Neurochem Res* 44(7):1593-1601, 2019
48. Zhou D, Huang Z, Zhu X, Hong T, Zhao Y: Combination of endothelial progenitor cells and BB-94 significantly alleviates brain damage in a mouse model of diabetic ischemic stroke. *Exp Ther Med* 22(1):789, 2021
49. Zhu J, Li Y, Shen W, Qiao C, Ambrosio F, Lavasani M, Nozaki M, Branca MF, Huard J: Relationships between transforming growth factor-beta1, myostatin, and decorin: Implications for skeletal muscle fibrosis. *J Biol Chem* 282(35):25852-25863, 2007