



Factors Associated with Treatment Success After Interlaminar Epidural Steroid Injection for Cervical Radicular Pain

Alp Eren CELENLIOGLU¹, Ilker SOLMAZ², Sami EKSEK², Fatih SIMSEK², Serkan ILKBAHAR³, Ender SIR¹

¹University of Health Sciences Gulhane Training and Research Hospital, Department of Pain Medicine, Ankara, Turkey

²University of Health Sciences Gulhane Training and Research Hospital, Department of Anesthesiology, Ankara, Turkey

³Halic University, Department of Vocational Health School, Istanbul, Turkey

Corresponding author: Alp Eren CELENLIOGLU ✉ a.celenlioglu@gmail.com

ABSTRACT

AIM: To investigate the demographic, clinical and radiological findings associated with treatment success after interlaminar epidural steroid injection (ILESİ) in radicular pain induced by cervical disc herniation.

MATERIAL and METHODS: In this retrospective study, the data of patients who received cervical ILESİ between January 2017 and June 2021 were screened. Of 223 patients, 92 with unilateral radicular neck pain due to cervical disc herniation were included. Demographic data, symptom duration, and numerical rating scale scores at baseline, at three weeks, three months, and six months after treatment were collected from the medical records of the patients. Disc herniation level, cervical axis, disc height, presence and degree of spinal canal and neural foraminal stenosis, vertebral endplate signal change, and definitive presence of uncovertebral and facet osteoarthritis were evaluated using cervical spine magnetic resonance imaging. Treatment success was determined as $\geq 50\%$ reduction in pain scores at six months compared to baseline.

RESULTS: Data of 92 patients (27 men, 65 women) were included. The mean age was 50.82 ± 10.22 years, and the median symptom duration was 12 (4.25 to 20) months. At six months after ILESİ, treatment was successful in 58 (58.7%) patients and unsuccessful in 34 (41.3%) patients. Multivariable logistic regression analysis was performed to identify the factors associated with treatment success at six months post-injection. In the final model, neural foraminal stenosis (non-severe vs. severe) and spinal canal stenosis (non-severe vs. severe) were significantly associated with the treatment success (OR=3.02, 95% CI=1.40–10.95, $p=0.009$; OR=5.31, 95% CI=1.77–15.85, $p=0.003$).

CONCLUSION: Treatment success of cervical ILESİ at six months is favorable. However, the presence of severe neural foraminal and spinal canal stenosis is associated with a reduced likelihood of treatment success.

KEYWORDS: Epidural injection, herniated disc, neck pain, radiating pain

ABBREVIATION: CRP: Cervical radicular pain, CDH: Cervical disc herniation, ILESİ: Interlaminar epidural steroid injection, MRI: Magnetic resonance imaging, NRS: Numerical Rating Scale

INTRODUCTION

Cervical radicular pain (CRP) is characterized by neck pain radiating from the shoulder to the arm and sometimes to the hand. It is a common health problem, with an

annual incidence of 83 per 100,000 individuals (19). One of the most common causes of CRP is cervical disc herniation (CDH). Pain develops due to direct mechanical compression of the herniated disc material on the spinal nerves or inflammation triggered by circulating enzymes and chemokines (14).

Alp Eren CELENLIOGLU : 0000-0001-8979-0392
Ilker SOLMAZ : 0000-0002-1959-8159
Sami EKSEK : 0000-0001-5566-286X

Fatih SIMSEK : 0000-0002-8774-2861
Serkan ILKBAHAR : 0000-0002-8325-1934
Ender SIR : 0000-0003-2628-135X

Epidural steroid injections, one of the interventional pain treatment methods, are frequently administered for the treatment of CRP resistant to conservative treatment. Administration of cervical interlaminar epidural steroid injection (ILESIs) is preferred over using the transforaminal approach owing to its ease of administration and low risk of complications (12,20). Many studies have proven its efficacy and safety in the short term (5,22,26). Although cervical ILESIs has a low complication risk, catastrophic complications, such as spinal cord injury, have been reported in the literature (2). Therefore, it is of utmost importance to identify the factors associated with treatment outcomes to avoid unnecessary costs and the risk of complications. However, limited studies in the literature have examined the factors associated with treatment success of cervical ILESIs (9,12,20). Sencan et al. reported that high level of CDH and the presence of severe neural foraminal stenosis in cervical spinal magnetic resonance imaging (MRI) had a negative effect on treatment success at three months after cervical ILESIs (20). Lee et al. observed less improvement in patients with paresthesia at the two-week follow-up after cervical ILESIs. However, both of these studies have a short follow-up period (12). As there are only few studies on this subject in the literature, the effect of various demographic, clinical, and radiological variables on the treatment success of cervical ILESIs still remains to be elucidated.

In the present study, we aimed to investigate the demographic, clinical, and radiological variables associated with mid-term treatment success after ILESIs in patients with CRP.

MATERIAL and METHODS

Study Design and Study Population

This study was designed as a single-center, retrospective study. The data of patients diagnosed with CDH-induced unilateral CRP after physical examination and cervical spinal MRI evaluation and those who underwent cervical ILESIs and presented to our pain medicine center between January 2017 and June 2021 were screened. Of 223 patients, 92 were included in the study (Figure 1).

Inclusion criteria were as follows: aged 18–65 years, CDH diagnosed on cervical spinal MRI in only one of the C3–4, C4–5, C5–6, C6–7 levels, presence of neck and unilateral arm and/or hand pain resistant to conservative treatment, symptom duration of >3 months, baseline Numerical Rating Scale (NRS) score of ≥ 4 . Exclusion criteria were as follows: myelomalacia (high intensity signal change on T2-weighted cervical spinal MRI), history of cervical spinal surgery, multiple epidural interventions within the last six months, lack of six-month follow-up data and cervical MRI images.

In accordance with the routine practices at our center, a written and verbal consent was obtained from each patient before the cervical ILESIs procedure. The study was approved by the institutional Ethics Committee (Date: 10.21.2021, No: 2019-131) and conducted in accordance with the principles of the Declaration of Helsinki.

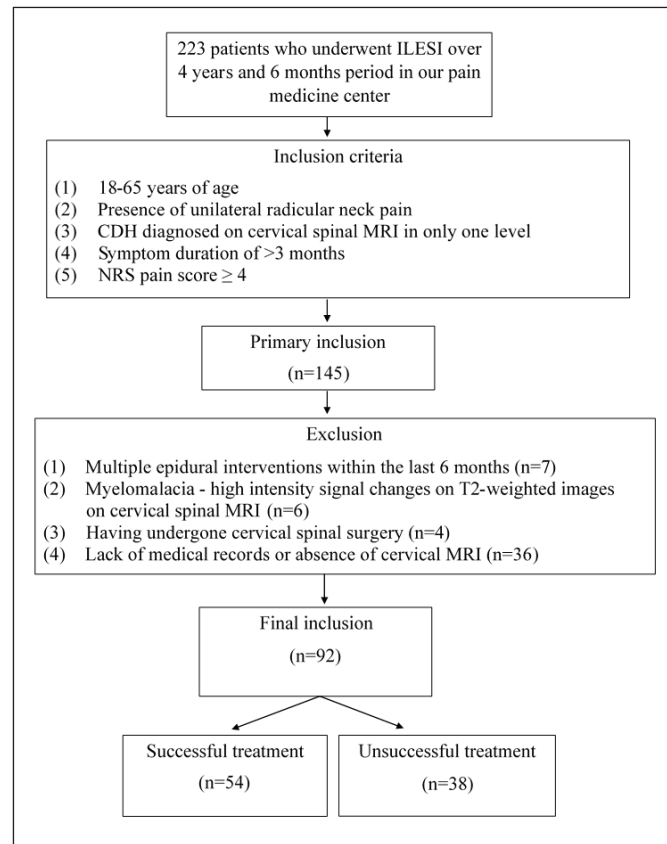


Figure 1: Flow diagram of the study.

Data Collection and Assessment

Sex, age, body mass index (BMI), neck and radiating pain to the arm and/or hand, symptom duration, and the side of the radicular pain were collected from the medical records of the patients.

According to routine practice at our pain medicine center, patients are evaluated before treatment and at three weeks, three months, and six months after treatment. The severity of pain is assessed using NRS (0 to 10, verbal). The baseline pain score before cervical ILESIs and the pain scores at three weeks, three months, and six months after the procedure were obtained through standard evaluation forms of the patients. Treatment success was defined as $\geq 50\%$ reduction in NRS scores at six months compared to baseline.

Radiological Assessment

All cervical spinal MRI evaluations were performed by a radiologist with 10 years of experience in spinal imaging. The radiologist was blinded to patients' clinical data during evaluation. All images were acquired with a 3.0 Tesla MRI device (Philips Achieva 3.0T) using dedicated cervical spinal coil with standard cervical MRI protocol and without contrast administration.

The level of CDH was determined on radiological evaluation. C3–4 and C4–5 level CDH were categorized as high and C5–6 and C6–7 level CDH as low level CDH. In addition,

cervical axis (normal lordosis and kyphosis), intervertebral disc height (normal and reduced), vertebral endplate signal changes (modic change present vs. no modic change), definitive uncovertebral osteoarthritis (present and absent), and definitive facet osteoarthritis (present and absent) were evaluated. Furthermore, severity of neural foraminal stenosis (non-severe and severe) and spinal canal stenosis (non-severe and severe) were recorded.

The presence of neural foraminal stenosis was evaluated on T2-weighted axial images based on the grading system developed by Kim et al. (8). In this grading system, neural foraminal stenosis is classified into three grades: Grade 0: normal, absence of neural foraminal stenosis; Grade 1: the narrowest width of the neural foramen is $>50\%$ of the width of the extraforaminal nerve root; Grade 2: the width of the neural foramen is $\leq 50\%$ of the width of the extraforaminal nerve root. In the present study, Grades 0 and 1 neural foraminal stenosis were classified as non-severe stenosis, while Grade 2 neural foraminal stenosis was classified as severe stenosis.

Evaluation of the presence of spinal central canal stenosis was performed on sagittal T2-weighted fast spin-echo images based on the grading system developed by Kang et al. (6). According to this grading system, spinal canal stenosis is classified into four grades. Grade 0: absence of central canal stenosis; Grade 1: obliteration of the subarachnoid space at a rate of $>50\%$ without spinal cord deformity; Grade 2: central canal stenosis with spinal cord deformity but no spinal cord signal change; Grade 3: presence of spinal cord signal changes close to the level of stenosis on T2-weighted images. According to the routine practice in our center, epidural intervention is not performed in patients with myelomalacia appearance in the spinal cord. Therefore, Grade 3 patients according to the grading system mentioned above were

excluded. In the present study, the presence of Grade 0 and Grade 1 stenosis was classified as non-severe stenosis, while the presence of Grade 2 stenosis was classified as severe stenosis.

Procedure

After the patients were taken to the intervention room, intravenous vascular access was established and the patients were monitored and placed in the prone position. All ILESI procedures were performed under fluoroscopy guidance and sterile conditions. The injection site was wiped with povidone-iodine, and a sterile drape was laid. After visualizing the C7–T1 interlaminar space in the anteroposterior view, the entry site was determined. Skin anesthesia was administered in the form of 3 mL of 2% prilocaine injection. The paramedian approach was used for all cervical ILESI procedures. The skin was penetrated with an 18-gauge Tuohy needle from the side of the radicular arm (Figure 2). The epidural space was entered under the contralateral oblique view using a loss of resistance injector. Thereafter, epidural spread was confirmed with no intravascular spread by administering 2 cc of contrast agent (Figure 3). After epidural spread was confirmed, a mixture of 8 mg of dexamethasone (2 cc), 1 cc of 2% lidocaine, and 3 cc of saline was injected. After the procedure, the patients were followed for 1 hour in the post-anesthesia care unit. Patients without any complications were discharged with recommendations.

Statistical Analysis

Statistical analysis was performed using the SPSS version 23.0 software (IBM Corp., Armonk, NY, USA). Descriptive data were presented in mean \pm standard deviation (SD), median (min-max) or number and frequency. The Shapiro–Wilk test was used to check whether quantitative variables conformed

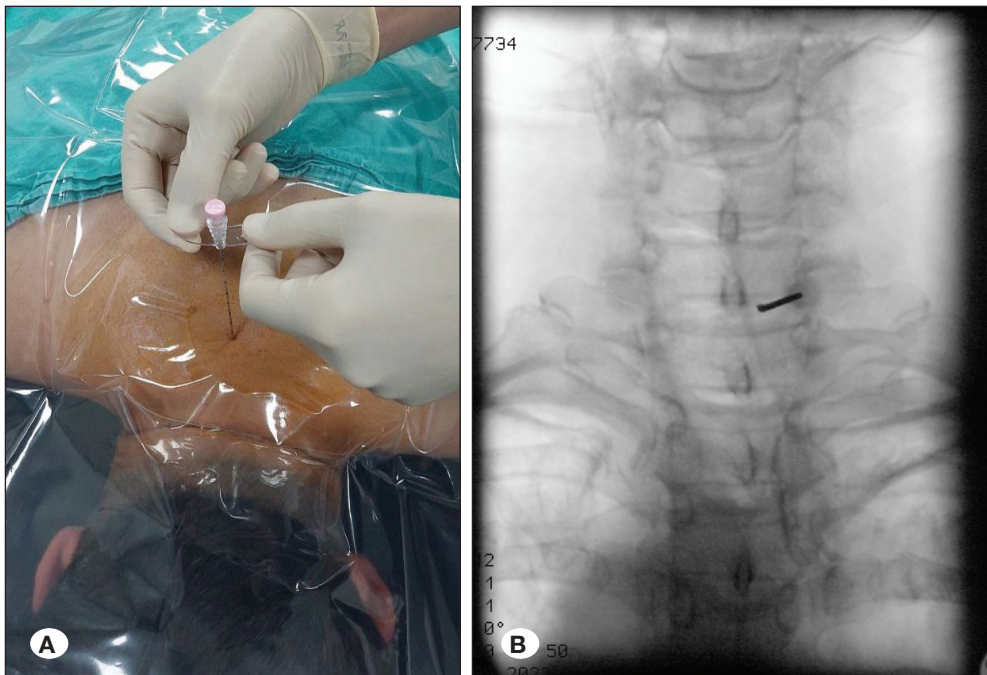


Figure 2: A) The paramedian approach. The entry of the needle and the angle it makes with the skin are shown in a patient with radicular pain on the right. **B)** Anteroposterior fluoroscopic image of the needle advanced into the epidural space.

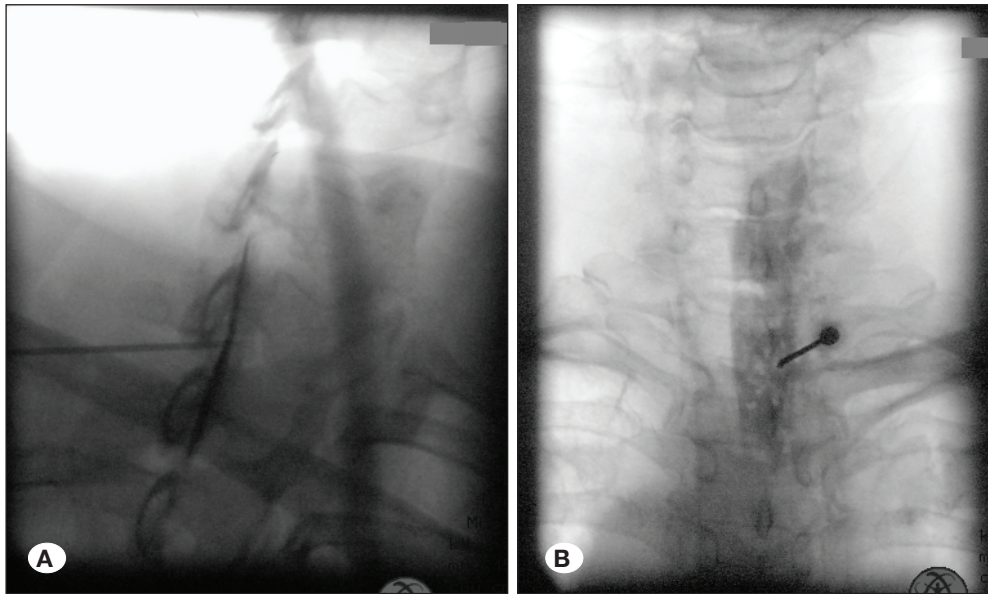


Figure 3: A) Epidural spread of the contrast agent in the contralateral oblique fluoroscopic image. B) Epidural spread of the contrast agent in the anteroposterior fluoroscopic image.

to normal distribution. As the data did not show normal distribution, the Mann–Whitney U test was used to compare the patients with and without treatment success in terms of these variables. Associations between the categorical variables and treatment success at six months after ILESI were analyzed using the Pearson chi-square analysis or Fisher–Freeman–Halton test. Variables with a p value of <0.05 in the univariate tests were included in the multivariate logistic regression model, and their adjusted effects on treatment success were calculated. A p value of <0.05 was considered statistically significant.

RESULTS

Of 223 patients who received cervical ILESI, 145 met the inclusion criteria. A total of 53 patients were excluded from the study. Of these, 36 patients were excluded due to the missing data, seven patients received multiple epidural interventions within the last six months, six patients had high intensity signal change on T2-weighted cervical spinal MRI, and four patients previously underwent cervical spinal surgery. Data of a total of 92 patients (27 men and 65 women) were included in the final analysis (Figure 1). The mean age of the entire study group was 50.82 ± 10.22 years, and the median symptom duration was 12 (4.25 to 20) months. Demographic and clinical characteristics of all patients are presented in Table I.

A significant decrease in NRS pain scores was observed at all time points after the procedure compared to baseline (Table II). At six months after cervical ILESI, the treatment was successful in 54 (58.7%) patients and unsuccessful in 34 patients (41.3%). No serious complications associated with the procedure were observed. Two patients developed a vasovagal reaction, but the complication did not prevent completion of the procedure.

According to treatment success, there was no significant difference between the groups in terms of demographic

Table I: Demographic and Clinical Characteristics of All Patients

Variables		Mean \pm SD (n=92)
Sex	Male	27 (29.3)
	Female	65 (70.7)
Age (years)		50.82 \pm 10.22
BMI (kg/m ²)		27.72 \pm 4.65
Symptom duration (month)		15.10 \pm 14.27
NRS (baseline)		8.13 \pm 1.23
Side (Radicular pain)	Right	42 (45.7)
	Left	50 (54.3)
Disc herniation level	High level	23 (25)
	Low level	69 (75)
Cervical curvature	Normal lordosis	32 (34.8)
	Kyphosis	60 (65.2)
Intervertebral disc height	Normal	71 (77.2)
	Reduced	21 (22.8)
Spinal canal stenosis	Non-severe	69 (75.0)
	Severe	23 (25.0)
Neural foraminal stenosis	Non-severe	65 (70.7)
	Severe	27 (29.3)
Modic change	Present	27 (29.3)
	Absent	65 (70.7)
Uncovertebral osteoarthritis	Present	15 (16.3)
	Absent	77 (83.7)
Facet osteoarthritis	Present	21 (22.8)
	Absent	71 (77.2)

BMI: Body mass index.

data, BMI, CDH level, cervical axis, intervertebral disc height, vertebral endplate signal change, uncovertebral osteoarthritis, and facet osteoarthritis ($p>0.05$). Subgroup analysis revealed that treatment success rate was significantly higher in patients with C5–6 level CDH compared to those with C4–5 level CDH ($p<0.05$). In addition, a significant difference was found between the groups in terms of neural foraminal and

central spinal stenosis ($p<0.05$) (Table III). In the final model, neural foraminal stenosis (non-severe vs. severe) and central spinal stenosis (non-severe vs. severe) had a significant effect on treatment success (OR=3.02, 95% CI=1.40–10.95, $p=0.009$; OR=5.31, 95% CI=1.77–15.85, $p=0.003$) (Table 4). The presence of severe neural foraminal stenosis and severe central spinal stenosis was found to be associated with a low likelihood of treatment success.

Table II: Temporal Variation of Pain Scores in All Patients

N=92	Mean \pm SD	p
NRS baseline	8.13 \pm 1.23	0.001
NRS week 3	2.63 \pm 2.50	
NRS month 3	3.64 \pm 2.30	
NRS month 6	4.47 \pm 2.03	

NRS: Numerical Rating Scale.

■ DISCUSSION

In the present study, we investigated the predictive roles of demographic data and degenerative findings on cervical spinal MRI on the treatment success of cervical ILESI for CDH-induced CRP. According to our results, a significant decrease in pain intensity was observed in the entire study group ($n=92$) at all time points during follow-up compared to baseline. Treatment success rate was 58.7% at six months

Table III: Comparison of Demographic and Clinical Characteristics Between Groups According to Treatment Success

		Treatment Success		p
		Successful	Unsuccessful	
		n=54	n=38	
Sex	Male	16 (59.3)	11 (40.7)	0,615
	Female	38 (58.5)	27 (41.5)	
Age (years)		51.52 \pm 8.78	49.82 \pm 12.05	0.586
BMI (kg/m ²)		27.80 \pm 4.45	27.61 \pm 4.97	0.874
Symptom duration (month)		12.0 (3.0-20.5)	10.5 (5.7-21.0)	0.504
NRS (Baseline)		8.09 \pm 1.29	8.18 \pm 1.15	0.728
Side (Radicular pain)	Right	26 (61.9)	16 (38.1)	0.567
	Left	28 (56.0)	22 (44.0)	
Cervical curvature	Normal lordosis	19 (59.4)	13 (40.6)	0.923
	Kyphosis	35 (58.3)	25 (41.7)	
Disc herniation level	High level	13 (56.5)	10 (43.5)	0.087
	Low level	25 (36.2)	44 (63.8)	
Intervertebral disc height	Normal	43 (60.6)	28 (39.4)	0.503
	Reduced	11 (52.4)	10 (47.6)	
Spinal canal stenosis	Non-severe	47 (68.1)	22 (31.9)	0.001
	Severe	7 (30.4)	16 (69.6)	
Neural foraminal stenosis	Non-severe	44 (67.7)	21 (32.3)	0.007
	Severe	10 (37.0)	17 (63.0)	
Modic change	Present	19 (70.4)	8 (29.6)	0.143
	Absent	35 (53.8)	30 (46.2)	
Uncovertebral osteoarthritis	Present	10 (66.7)	5 (33.3)	0.493
	Absent	44 (57.1)	33 (42.9)	
Facet osteoarthritis	Present	14 (66.7)	7 (33.3)	0.398
	Absent	40 (56.3)	31 (43.7)	

BMI: Body mass index, **NRS:** Numerical rating scale.

Table IV: Exploration of Predictive Factors Affecting Treatment Success in the Six Month After Procedure

	OR	95% CI for OR		p
		Lower	Upper	
Spinal canal stenosis (Non-severe vs. severe)	5.31	1.77	15.85	0.003
Neural foraminal stenosis (Non-severe vs. severe)	3.92	1.40	10.95	0.009
Age (years)	1.03	0.99	1.08	0.127
Sex	1.33	0.47	3.71	0.580

OR: Odds ratio, **CI:** Confidence interval.

after cervical ILESI. Moreover, severe neural foraminal and central spinal stenosis were predictive factors associated with a low likelihood of treatment success.

Many studies have shown that cervical ILESI is an effective and safe treatment for CRP in the short term (5,22,26). In the present study, a significant decrease at all time points was found within six months compared to baseline. The exact mechanism underlying the efficacy of epidural steroid injections in the treatment of pain have not been fully elucidated; however, several mechanisms of action have been proposed to date. Steroids injected into the epidural space exert a potent anti-inflammatory effect by inhibiting the arachidonic acid cascade initiated by phospholipase A2 (24). In addition, local anesthetics administered with steroids show anti-inflammatory properties (1). With the reduction of inflammation in the spinal nerve root after injection, edema in the nerve tissue decreases. This may be the mechanism through which the compression on the nerve tissue due to foraminal stenosis decreases (7). Steroids also provide membrane stabilization on neurons, they can inhibit neuropeptide synthesis, and they can provide pain relief by blocking ectopic signals (21). Moreover, the injected mixture can provide a “washout” effect by removing the inflammatory agents from around the inflamed spinal and dorsal root ganglion (23). Taken together, all these features may explain the effect of cervical ILESI in CRP treatment.

Limited studies in the literature have examined the effect of the severity of neural foraminal stenosis on cervical epidural steroid injections according to cervical spinal MRIs (7,20). Kim et al. evaluated the data of 53 patients and classified neural foraminal stenosis as non-severe and severe stenosis. They reported that the severity of neural foraminal stenosis had no significant effect on treatment outcomes at three months after cervical transforaminal epidural steroid injection (7). In the present study, the same classification was used to determine the degree of neural foraminal stenosis. Severe neural foraminal stenosis was identified as a risk factor for reduced success of cervical ILESI treatment. The difference between the results may be due to the different time points used in these two studies. The study of Kim et al. covered a short follow-up period of three months, whereas the present study covers a longer follow-up period of six months (7). Over a longer follow-up period, the success rate may decrease in patients with severe neural foraminal stenosis compared to those with non-severe

stenosis, and the difference in treatment success between the patients in the two groups may be increasing. Another reason for the differences between the results may be the different treatment methods applied in the two studies. Using the interlaminar approach, the injectant is given close to the site of pathology, whereas using the transforaminal approach is target-specific and the injectant can be given directly around the spinal nerve root and dorsal root ganglion at the level of the pathology (16). In this way, even if severe neural foraminal stenosis is present at the injection level, sufficient injectate may reach the area of pathology. However, ILESI may be considered as a better option as it is more important to reduce the probability of permanent neurological problems that may occur because of catastrophic neurological complications of the transforaminal approach, as reported in the literature (11, 15). In their study evaluating the data of 61 patients, Sencan et al. defined severe neural foraminal stenosis as a risk factor that reduces the success of cervical ILESI treatment at three months (20). Our results are consistent with this previous study in this respect. Ghahreman and Bogduk et al. reported that lumbar transforaminal epidural steroid injection was less effective in patients with high-grade lumbar spinal nerve root compression compared to those with low-grade compression (3). They argued that in the majority of the patients with high-grade spinal root compression, the main source of pain was not inflammation of the nerve root but mechanical compression, which did not improve even after TFESI; this explained the obtained results. Treatment success was also lower in patients with severe neural foraminal stenosis in the present study, which may be due to the same mechanism.

Since there is no globally used cervical canal stenosis grading system, Kang et al. developed a four-stage grading system that can be easily evaluated on sagittal T2-weighted fast spin-echo images (6). It was later reported that this grading system correlated quite well with neurological symptoms (18, 25). To the best of our knowledge, the present study is the first to evaluate the effect of cervical canal stenosis grade on epidural steroid injection therapy. Manzur et al. (17) evaluated the data of 244 patients with cervical myelopathy (Grade 3 according to the classification of Kang et al. (6)) and reported that epidural steroid injections did not delay surgical treatment. In our clinical practice, we refer patients with myelopathy in cervical spinal MRI and severe symptoms to surgical treatment, as their condition may be progressive. Therefore, patients with Grade 3 cervical canal stenosis were not included in

the present study. As a result, patients with Grades 0 and 1 cervical canal stenosis without cord deformity were classified as non-severe, and Grade 2 patients were classified as severe cervical canal stenosis. In the present study, the presence of severe cervical canal stenosis was found to be associated with a low likelihood of cervical ILESi treatment success. This may be associated with the more severe clinical symptoms in this patient group, as well as the fact that the main cause of pain in patients with severe cervical canal stenosis is advanced mechanical compression rather than inflammation in the neural structures.

Sencan et al. found a significantly higher treatment success rate in patients with C5–6 level and C6–7 level CDH compared to those with C3–4 level and C4–5 level CDH, respectively (20). In the present study, C6–7 and C5–6 were classified as low spinal levels and C3–4 and C4–5 as high spinal levels for CDH, and no significant difference was found between the groups in terms of the treatment success. However, subgroup analysis revealed that treatment success was significantly higher in patients with C5–6 level CDH compared to those with C4–5 level CDH. In this context, the results are consistent with previous findings. However, further studies with larger patient groups are warranted to evaluate the relationship between cervical ILESi treatment results and CDH level more clearly.

In the current study, age, sex, and duration of symptoms did not affect treatment success, consistent with the literature (9,12,20). In addition, cervical spinal MRI parameters, including cervical axis, intervertebral disc height, vertebral endplate signal change, presence of definitive uncovertebral, and definitive facet osteoarthritis, other than neural foraminal and cervical canal stenosis stages had no effect on treatment success. This may be explained by the fact that the main cause of pain in patients with CDH-related neck and radicular pain is neural inflammation and spinal nerve and cord compression.

Three basic methods have been described for cervical ILESi, midline, paramedian, and parasagittal (13). Compared to the midline approach, the paramedian and parasagittal approaches are more effective in delivering the injectant to the symptomatic side and in terms of treatment outcomes (4,10). In addition, the epidural space in the cervical region widens as you go down from the upper levels to the C7–T1 spinal levels (20). In our clinical practice and study, cervical ILESi was performed using a paramedian approach from the C7–T1 spinal level owing to the advantages mentioned above.

Nonetheless, there are certain limitations to this study. The main limitation is its single-center, retrospective design. Second, patient disability and functional evaluation was unable to be performed. Finally, the contrast diffusion pattern was unable to be evaluated. On the other hand, the homogeneous patient group with neck and radicular pain due to CDH and the six-month follow-up period are the main strengths of the study. To the best of our knowledge, this is the first study to investigate the effect of multiple degenerative findings as evidenced by cervical spinal MRI on the success of cervical ILESi treatment, and the results obtained are valuable.

■ CONCLUSION

In conclusion, cervical ILESi is an effective and safe treatment method for CDH-induced CRP. The presence of severe neural foraminal and cervical canal stenosis is a predictive factor associated with a low likelihood of treatment success at six months after the procedure. These results may contribute to the decision-making process on cervical ILESi treatment for CDH-induced CRP. Careful pre-procedural evaluation of these factors associated with treatment success can reduce the number of unnecessary interventions and prevent possible complications. However, further large-scale, long-term, prospective studies are required to better understand the factors associated with treatment success.

AUTHORSHIP CONTRIBUTION

Study conception and design: AEC, IS, SE, FS, SI, ES

Data collection: AEC, IS, SE, FS, SI, ES

Analysis and interpretation of results: AEC, IS, SE, FS, SI, ES

Draft manuscript preparation: AEC, ES

Critical revision of the article:

Other (study supervision, fundings, materials, etc...): ES

All authors (AEC, IS, SE, FS, SI, ES) reviewed the results and approved the final version of the manuscript.

■ REFERENCES

1. Cassuto J, Sinclair R, Bonderovic M: Anti-inflammatory properties of local anesthetics and their present and potential clinical implications. *Acta Anaesthesiol Scand* 50:265-282, 2006
2. Chang A, Wang D: Complications of fluoroscopically guided cervical interlaminar epidural steroid injections. *Curr Pain Headache Rep* 24:63, 2020
3. Ghahreman A, Bogduk N: Predictors of a favorable response to transforaminal injection of steroids in patients with lumbar radicular pain due to disc herniation. *Pain Med* 12:871-879, 2011
4. Hashemi M, Dadkhah P, Taheri M, Dehghan K, Valizadeh R: Cervical epidural steroid injection: Parasagittal versus midline approach in patients with unilateral cervical radicular pain; a randomized clinical trial. *Bull Emerg Trauma* 7:137-143, 2019
5. House LM, Barrette K, Mattie R, McCormick ZL: Cervical epidural steroid injection: Techniques and evidence. *Phys Med Rehabil Clin N Am* 29:1-17, 2018
6. Kang Y, Lee JW, Koh YH, Hur S, Kim SJ, Chai JW, Kang HS: New MRI grading system for the cervical canal stenosis. *AJR Am J Roentgenol* 197:134-140, 2011
7. Kim MS, Lee DG, Chang MC: Outcome of transforaminal epidural steroid injection according to severity of cervical foraminal stenosis. *World Neurosurg* 110:e398-e403, 2018
8. Kim S, Lee JW, Chai JW, Yoo HJ, Kang Y, Seo J, Ahn JM, Kang HS: A new MRI grading system for cervical foraminal stenosis based on axial t2-weighted images. *Korean J Radiol* 16:1294-1302, 2015

9. Kwon JW, Lee JW, Kim SH, Choi JY, Yeom JS, Kim HJ, Kwack KS, Moon SG, Jun WS, Kang HS: Cervical interlaminar epidural steroid injection for neck pain and cervical radiculopathy: Effect and prognostic factors. *Skeletal Radiol* 36:431-436, 2007
10. Lee B, Lee SE, Kim YH, Park JH, Lee KH, Kang E, Kim S, Kim J, Oh D: Evaluation of contrast flow patterns with cervical interlaminar epidural injection: Comparison of midline and paramedian approaches. *Medicina* 57(1):8, 2020
11. Lee E, Lee JW, Kang HS: Interlaminar versus transforaminal epidural steroid injections: A review of efficacy and safety. *Skeletal Radiol* 43:933-938, 2014
12. Lee JW, Hwang SY, Lee GY, Lee E, Kang HS: Fluoroscopic cervical paramidline interlaminar epidural steroid injections for cervical radiculopathy: Effectiveness and outcome predictors. *Skeletal Radiol* 43:933-938, 2014
13. Manchikanti L, Abdi S, Atluri S, Benyamin RM, Boswell MV, Buenaventura RM, Bryce DA, Burks PA, Caraway DL, Calodney AK, Cash KA, Christo PJ, Cohen SP, Colson J, Conn A, Cordner H, Coubarous S, Datta S, Deer TR, Diwan S, Falco FJ, Fellows B, Geffert S, Grider JS, Gupta S, Hameed H, Hameed M, Hansen H, Helm S, 2nd, Janata JW, Justiz R, Kaye AD, Lee M, Manchikanti KN, McManus CD, Onyewu O, Parr AT, Patel VB, Racz GB, Sehgal N, Sharma ML, Simopoulos TT, Singh V, Smith HS, Snook LT, Swicegood JR, Vallejo R, Ward SP, Wargo BW, Zhu J, Hirsch JA: An update of comprehensive evidence-based guidelines for interventional techniques in chronic spinal pain. Part II: Guidance and recommendations. *Pain Physician* 16:S49-283, 2013
14. Manchikanti L, Falco FJ, Diwan S, Hirsch JA, Smith HS: Cervical radicular pain: The role of interlaminar and transforaminal epidural injections. *Curr Pain Headache Rep* 18:389, 2014
15. Manchikanti L, Hirsch JA: Neurological complications associated with epidural steroid injections. *Curr Pain Headache Rep* 19:482, 2015
16. Manchikanti L, Nampiaparampil DE, Candido KD, Bakshi S, Grider JS, Falco FJ, Sehgal N, Hirsch JA: Do cervical epidural injections provide long-term relief in neck and upper extremity pain? A systematic review. *Pain Physician* 18:39-60, 2015
17. Manzur MK, Samuel AM, Vaishnav A, Gang CH, Sheha ED, Qureshi SA: Cervical steroid injections are not effective for prevention of surgical treatment of degenerative cervical myelopathy. *Global Spine J*, 2021(Online ahead of print)
18. Park HJ, Kim SS, Chung EC, Lee SY, Park NH, Rho MH, Choi SH: Clinical correlation of a new practical MRI method for assessing cervical spinal canal compression. *AJR Am J Roentgenol* 199:197-201, 2012
19. Radhakrishnan K, Litchy WJ, O'Fallon WM, Kurland LT: Epidemiology of cervical radiculopathy. A population-based study from Rochester, Minnesota, 1976 through 1990. *Brain* 117:325-335, 1994
20. Sencan S, Edipoglu IS, Yazici G, Yucel FN, Gunduz OH: Are foraminal stenosis severity and herniation level associated with the treatment success of cervical interlaminar epidural steroid injection? *Pain Physician* 23:325-332, 2020
21. Shanthanna H, Busse J, Wang L, Kaushal A, Harsha P, Suzumura EA, Bhardwaj V, Zhou E, Couban R, Paul J, Bhandari M, Thabane L: Addition of corticosteroids to local anaesthetics for chronic non-cancer pain injections: A systematic review and meta-analysis of randomised controlled trials. *Br J Anaesth* 125:779-801, 2020
22. Sim JH, Park H, Kim Y, Shin JW, Leem JG, Cho HS, Choi SS: Comparative effectiveness of parasagittal interlaminar and transforaminal cervical epidural steroid injection in patients with cervical radicular pain: A randomized clinical trial. *Pain Physician* 24:117-125, 2021
23. Tak HJ, Jones R, Cho YW, Kim EH, Ahn SH: Clinical evaluation of transforaminal epidural steroid injection in patients with gadolinium enhancing spinal nerves associated with disc herniation. *Pain Physician* 18:177-185, 2015
24. Van Zundert J, Huntoon M, Patijn J, Lataster A, Mekhail N, Van Kleef M: 4. Cervical radicular pain. *Pain Pract* 10:1-17, 2010
25. Waheed H, Khan MS, Muneeb A, Jahanzeb S, Ahmad MN: Radiologic assessment of cervical canal stenosis using kang MRI grading system: Do clinical symptoms correlate with imaging findings? *Cureus* 11:e5073, 2019
26. Yoon JY, Kwon JW, Yoon YC, Lee J: Cervical interlaminar epidural steroid injection for unilateral cervical radiculopathy: Comparison of midline and paramedian approaches for efficacy. *Korean J Radiol* 16:604-612, 2015