

# Endoscopic Lavage for the Treatment of Multiple Shunt Failures in Children

Inan GEZGIN<sup>1</sup>, Adem DOGAN<sup>2</sup>

<sup>1</sup>Republic of Turkey Ministry of Health, Dr. Ersin Arslan Training and Research Hospital, Clinic of Neurosurgery, Gaziantep, Turkey

<sup>2</sup>Republic of Turkey Ministry of Health, Sehitkamil State Hospital, Clinic of Neurosurgery, Gaziantep, Turkey

**Corresponding author:** Adem DOGAN ✉ drademdogan@yahoo.com

## ABSTRACT

**AIM:** To compare the efficacy of neuroendoscopic lavage (NEL) and shunt revision (SR) in the treatment of multiple shunt failures in children with hydrocephalus.

**MATERIAL and METHODS:** The data of 56 pediatric patients who underwent surgeries for the treatment of shunt failure were retrospectively reviewed. Patients were divided into two groups, i.e., the simple SR (Group A) and the NEL+SR (Group B) cohorts. Demographic characteristics, co-morbidities, surgical interventions, cerebrospinal fluid analyzes, and complications were recorded and statistically compared between the groups.

**RESULTS:** Among the 56 enrolled patients, 51 presented with shunt dysfunction caused by infectious debris or clots at different times. Moreover, 28 of these 51 patients (54.9%) were female and 23 (45%) were male. The mean age was 7.3 months. Simple SR was performed in 30 cases (Group A), and NEL and simultaneous SR were performed in 21 patients (Group B). The risk of shunt dysfunction was significantly lower in Group B ( $p < 0.05$ ). The risk of infection was elevated in Group A; however, this difference was not statistically significant ( $p > 0.05$ ).

**CONCLUSION:** Simultaneous endoscopic lavage and SR was an effective method for the treatment of shunt dysfunction in children. It was also superior to simple SR regarding the risk of shunt dysfunction. Additional clinical studies are needed to verify this outcome.

**KEYWORDS:** Hydrocephalus, Child, Infection, Endoscopic lavage, Shunt failure

## INTRODUCTION

Hydrocephalus consists in the accumulation of excess cerebrospinal fluid (CSF) in the ventricular and subarachnoid spaces of the brain, resulting in increased intracranial pressure (2). It is a pathophysiological process that has been known since the time of Galen and Hippocrates, and its treatment remains up-to-date (30). CSF diversion is essential when the CSF resorption fails. Intraventricular bleeding, infections, and myelomeningocele are among the most common causes of hydrocephalus in the pediatric age group (2,36). Treatment for this condition consists in the surgical diversion of the CSF via either temporary or permanent methods, such as external ventricular drainage

(EVD), ventriculoperitoneal (V/P) shunts, and endoscopic third ventriculostomy (ETV) (2,8,13,18,36,46). Currently, ETV, as the only alternative to shunt procedure, is becoming increasingly important (13,21).

The insertion of shunt systems remains the most common surgical procedure in hydrocephalus, with more than 18,000 new devices implanted each year (3). Nevertheless, shunt systems can lead to various complications, such as shunt infection, fracture, or disconnection; colon perforation; knot formation; and malfunctioning caused by obstructive debris (4,7,13). Despite these different treatment methods, shunt failure remains high in neurosurgical practice (3,5,19,20,27,33).

Among the causes of shunt failure, infection is an important factor, as is catheter occlusion, breakage, or cutting (5,9,26). Neuroendoscopic lavage (NEL) has been performed in recent years to remove intraventricular bleeding products and vegetations, especially in posthemorrhagic hydrocephalus or hydrocephalus caused by infection (6,11,22,23,46). It is a safe and potentially effective procedure for the management of posthemorrhagic hydrocephalus (12,36,40).

In this study, the data of 56 patients who had previously undergone V/P shunt insertion and had shunt failure were retrospectively reviewed. Fifty-one patients with multiple frequent shunt failures were included in this study and divided into two groups, to evaluate the efficacy of NEL in the treatment of multiple and frequent shunt failures.

## ■ MATERIAL and METHODS

Local ethics committee approval was received for the study (14.07.2020/332). Demographic characteristics, co-morbidities, surgical interventions, CSF analyses, and intraoperative and postoperative complications of patients who applied to our clinic for the treatment of shunt failure between January 01, 2017 and December 31, 2021 were retrospectively analyzed.

### Inclusion Criteria

This study had three inclusion criteria:

- Children with a diagnosis of hydrocephalus
- Children who had undergone V/P shunt insertion and encountered multiple and frequent shunt failures because of infectious particles or posthemorrhagic debris or clots
- Children who had received all of their hydrocephalus management at our department

A total of 56 pediatric patients had undergone shunt revision (SR) over a 5-year period, 51 of whom had multiple and frequent shunt failures caused by infection or hemorrhage. Patients with shunt failure secondary to disconnection, fracture, or migration were excluded from the study. All surgical procedures were performed by the same surgeon. All patients underwent clinical, radiological, and hemodynamic evaluations before surgery. The clinical data of the 51 patients, including age, gender, co-morbidities, surgical procedures, postoperative complications, and SR rates, were collected. According to the surgical technique, the cases were divided into groups A and B: patients who underwent simple SR were placed in Group A, and patients who underwent simultaneous NEL and SR were placed in Group B. NEL was not performed in patients who were deemed unstable for this procedure by pediatricians or anesthesiologists; thus, these patients underwent simple SR.

In all cases, head circumference measurement, eye fundus examination, and brain tomography were performed in the preoperative period.

### Surgical Procedure

*NEL+SR:* First, the previous shunt system (old ventricular

and peritoneal catheters and valve) was removed. Then, a 2-dimensional endoscope (Karl Storz®, Tuttlingen, Germany) was used for neuroendoscopic ventricular lavage. After entering the intraventricular area, continuous irrigation was started from the irrigation channel of the endoscope using Ringer's Lactate solution heated at body temperature (37°C). Concomitantly, fluid escape from the ventricle was ensured. In particular, the endoscope was mobilized and irrigation was performed to clean the vegetations and clots that were attached to the lateral ventricle walls. Irrigation was performed through the endoscope irrigation cannula and continued until the intraventricular area became clear and ventricular landmarks were visible (Figure 1). The third ventricle was also entered to remove free-floating clots or debris by aspiration. The patency of the aqueduct was also checked. Approximately 2000–2500 ml of Ringer's Lactate solution was used for irrigation in each operation. Some particles or clots were removed using grasping forceps (Figure 2). Irrigation was continued until the blood residues and particles were washed out of the ventricular system. No third ventriculostomy or septostomy was performed. The cortectomy tract was sealed with oxidized cellulose. At the end of irrigation, new shunt catheters were inserted and the tip of the ventricular catheter was confirmed using an endoscope (Figure 3). The ventricular and peritoneal catheters were connected via a new valve system and the procedure was terminated. The mean duration of each procedure was 65 min.

*Simple SR:* The failed shunt system (catheters and valve) was removed and the new ventricular catheter was inserted into the lateral ventricle via classical technique. No endoscopic or microscopic method was used for irrigation of the ventricles. The new peritoneal catheter was also inserted, the two catheters were connected via a new shunt valve system, and the procedure was terminated. The mean duration of each procedure was 45 min.

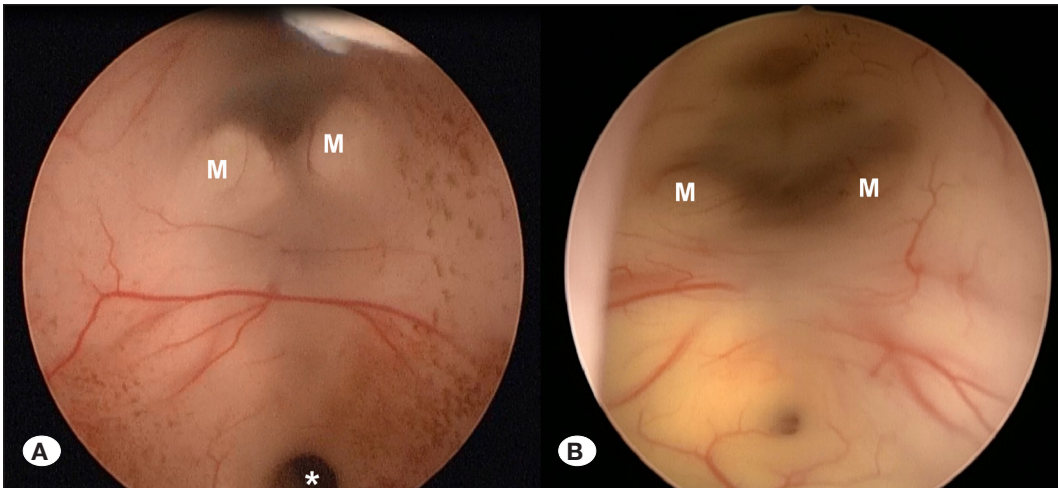
All cases were followed-up in the intensive care unit during the early postoperative period. Brain tomography was performed in the early period to confirm the catheter site and to exclude any intracranial hemorrhage. All patients received prophylactic antibiotic therapy for 3 days, intra- and postoperatively.

### Statistical Analysis

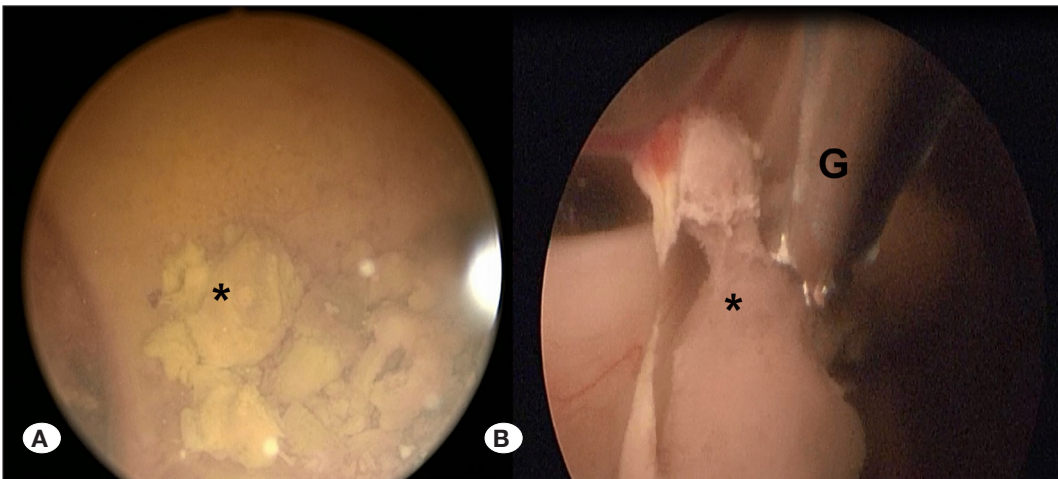
The IBM SPSS Version 25.0 (Armonk, NY: IBM Corp) statistical package program was used for data analysis. Numerical variables among the patient data are expressed as the mean  $\pm$  standard error of the mean (SH) and minimum (lowest)–maximum (highest) values. Categorical variables are reported as the number of patients (n) and percentages (%) with descriptive statistics. The relationship between categorical data in independent groups was first examined using the chi-squared ( $\chi^2$ ) test, and Fisher's exact test was used in the analysis in which the chi-squared assumptions were not met. Differences at the  $p < 0.05$  level were considered statistically significant.

## ■ RESULTS

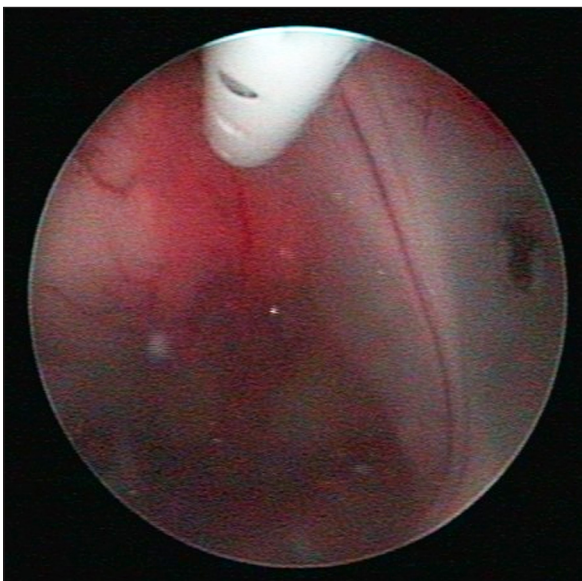
Shunt failure was detected in 56 patients who initially



**Figure 1:** **A)** Endoscopic view of the third ventricle showing the brown infective particles on both sides. **B)** After the endoscopic lavage, the particles were removed. **M:** mamillary bodies, **∗:** Aquaductus Sylvii.



**Figure 2:** **A)** Endoscopic view of the lateral walls in a patient with previous shunt failure. The particles (\*) were attached to the walls. **B)** The particles that could not be cleaned with lavage were removed using endoscopic grasping forceps.



**Figure 3:** Endoscopic view of the tip of the ventricular catheter in the lateral ventricle after the endoscopic lavage.

presented with hydrocephalus and underwent V/P shunt insertion, 51 of whom presented with shunt dysfunctions at different times. Among these 51 patients, 28 (54.9%) were female and 23 (45%) were male. The mean age of the patients was 7.3 months (range, 17 days to 11 years) (Table I).

Associated malformations or accompanying lesions were detected in 31 patients, including myelomeningocele (n=11), encephalocele (n=2), Dandy–Walker malformation (n=6), intracranial mass lesion (n = 2), retinoic acid embryopathy (n=1), myelomeningocele with diastematomyelia (n=5), and intracranial hemorrhage (n=4). The distribution of the associated lesions or malformations based on the type of procedure is shown in Table II.

The most common presenting symptom was a bulging fontanel (n=40, 78.4%). In addition, nuchal rigidity, irritability, fever, and abdominal tenderness symptoms were also recorded (Table I). The most common microorganism present in the CSF cultures obtained during the removal of the previous shunt was *Staphylococcus epidermidis* (n=5, 55.5%). In addition, *S. hemolyticus* was observed in one patient, *S. aureus* in two patients, and *E. coli* in one patient.

**Table I:** Demographic Features, Associated Lesions, Symptoms of Patients with Multiple Frequent Shunt Failures

Variables	n, (%)
<b>Number of Patients</b>	51
<b>Gender</b>	
Female	28 (54.9)
Male	23 (45)
<b>Associated Lesion or Malformation</b>	
Myelomeningocele	11 (35.4)
Encephalocele	2 (6.4)
Dandy-Walker Malformation	6 (19.3)
Intracranial tumor	2 (6.4)
Retinoic acid Embryopathy	1 (3.2)
Myelomeningocele+Diastometamyelia	5 (16.1)
Intracranial hemorrhage	4 (12.9)
<b>Symptoms</b>	
Bulging fontanel	40 (78.4)
Nuchal rigidity	10 (19.6)
Irritability	18 (35.2)
Fever	10 (19.6)
Abdominal tenderness	5 (9.8)
<b>Microorganisms</b>	
<i>Staf. Epidermidis</i>	5 (55.55)
<i>Staf. Hemoliticus</i>	1 (11.11)
<i>Staf. Aureus</i>	2 (22.22)
<i>E.coli</i>	1 (11.12)

A simple SR procedure was performed in 30 of the cases (Group A), whereas NEL and simultaneous SR were performed in the remaining 21 patients (Group B). In the late postoperative period, shunt dysfunction developed in 21 of the 30 patients in Group A; in addition, postoperative shunt infection occurred in seven patients. In Group B, shunt dysfunction developed in eight patients and shunt infection occurred in two patients.

In Group A, V/P shunting was performed in 13 patients, ventriculoatrial shunting in 1 patient, and EVD in 7 patients, followed by V/P shunt revision. In Group B, V/P shunting was performed in 6 patients, EVD was performed in 2 patients, and then V/P SR was performed.

Based on the surgical technique, the risk of shunt dysfunction was found to be statistically low in cases with NEL+SR (Group B) ( $p=0.024$ ). There was no statistically significant correlation between the surgical method and the development

**Table II:** The Distribution of Patients Based on the Associated Lesion or Malformation and Groups

Associated Lesion or Malformation	Group A	Group B	Total
Myelomeningocele	5	6	11
Encephalocele	2	0	2
Dandy-Walker Malformation	2	4	6
Intracranial tumor	0	2	2
Retinoic acid Embryopathy	1	0	1
Myelomeningocele+Diastometamyelia	3	2	5
Intracranial hemorrhage	2	2	4
<b>Total</b>	<b>15</b>	<b>16</b>	<b>31</b>

of shunt infection ( $p=0.227$ ). However, despite this, the risk of developing infection was elevated in the simple SR group (Group A).

Postoperative standard prophylactic antibiotic therapy was administered in all cases. The patients were called for follow-up at 1 week, 1 month, 3 months, 6 months, and 1 year after surgery.

## ■ DISCUSSION

NEL is a recent and promising surgical technique for the treatment of posthemorrhagic hydrocephalus. It is unfrequently used after shunt failures in pediatric patients with hydrocephalus. The potential benefits of NEL in hydrocephalus are that it can positively affect CSF circulation by first clearing intraventricular blood or vegetations from the ventricular system (36,37,41,42). Second, it can reduce the blood products in the CSF and prevent other complications, such as catheter obstruction or multi-compartment hydrocephalus (17). Finally, cleaning of the blood products from the CSF may promote cerebral development and prevent secondary injury by decreasing inflammation (10,12,14,35–37).

Some studies have used the Drain, Irrigation, and Fibrinolytic Therapy procedure during NEL. Although this procedure did not reduce the need for a V/P shunt, there was a significant increase in the proportion of patients who survived without severe cognitive impairment at 2 years and 10 years of follow-up compared with those who received the standard treatment (25,43,44). Kulkarni et al. and Riva-Cambrin et al. reported that this technique is less effective in controlling hydrocephalus in patients with posthemorrhagic hydrocephalus who were younger than 1 year (21,32). Another study reported its usefulness for the treatment of hydrocephalus in pediatric patients (16). In our study, patients who underwent NEL together with standard SR had less shunt dysfunction than did the patients who underwent simple SR.

In the largest series on neuroendoscopic intervention in children, NEL was performed in 138 cases. NEL was repeated in 12 cases, simultaneous V/P shunt was inserted in 27 cases, simultaneous cyst fenestration and V/P shunt were placed in two cases, simultaneous ETV was placed in four cases, and EVD was placed in one case (34). Children who were managed by NEL after the posthemorrhagic hydrocephalus a high shunt survival rate (67.7%) compared with the remaining children in the cohort managed for other diseases (56.4%). In this group, infection was observed in three patients after NEL or re-NEL. However, shunt infection was observed in eight patients and shunt re-infection was noted in one patient. In that study, it was emphasized that the main targets of the neuroendoscopic procedure in the premature and neonatal age groups are intraventricular hemorrhage and subsequent hydrocephalus (34).

During the procedure, saline, Ringer's lactate, and artificial CSF solutions are used for irrigation (1,15,36,38,39). Miyajima et al. analyzed various medical solutions for NEL and pointed out that artificial CSF solutions may cause less change in astrocytes compared with Ringer's lactate and saline solutions (28). Similar to that reported in the literature, Ringer's lactate was used for irrigation in our study. Fibrinolytic agents have also been used in some studies during drainage. However, their use is limited because of the risk of re-hemorrhage (44,45). We did not use fibrinolytic agents in our study.

There is controversy regarding the use of intraventricular antimicrobial agents just after NEL. Some researchers have suggested the prophylactic use of gentamicin and vancomycin in the ventricular region for the prevention of shunt infections (29,31). However, there is no large-scale study on this subject. In a few studies, the rate of infection associated with the procedure was reported as 3.6% (41,42). We used prophylactic vancomycin and ceftriaxone in our study, and no procedure-related infection occurred in the early postoperative period of our cases.

Some studies revealed the positive effect of neuroendoscopic lavage in reducing the rate of re-infection, as well as the rate of V/P shunting (24,39). Although it has been reported that NEL reduces shunt-dysfunction-free survival, the evaluation parameter of neurological involvement has not been revealed. The limitations of the technique include possible parenchymal damage by the endoscope in the intraventricular area, exposure of the patient to anesthesia, and impact on future neurodevelopment (36).

Similar to any advanced surgical technique, a learning curve is required to master NEL. For example, the morbidity and mortality that would occur during the procedure in a small center indicate the potential operative risk associated with NEL. Therefore, it is important to perform the procedure in centers where endoscopic intracranial surgery is routinely performed.

The limitations of our study included its retrospective nature and low number of cases, including both groups. In addition, this was a single-center study.

## CONCLUSION

Neuroendoscopic lavage is a method that can be performed simultaneously with SR for the treatment of multiple and frequent shunt failures caused by infectious debris or clots. It significantly reduces the incidence of further shunt dysfunctions. It facilitates CSF absorption by removing intraventricular vegetations and clots, especially in posthemorrhagic or post-infectious hydrocephalus. Further clinical studies with larger populations are needed to evaluate the efficacy and incidence of procedure-related complications.

### AUTHORSHIP CONTRIBUTION

Study conception and design: IG

Data collection: AD, IG

Analysis and interpretation of results: IG

Draft manuscript preparation: IG

Critical revision of the article: AD

All authors (IG, AD) reviewed the results and approved the final version of the manuscript.

## REFERENCES

- Basaldella L, Marton E, Fiorindi A, Scarpa B, Badreddine H, Longatti P: External ventricular drainage alone versus endoscopic surgery for severe intraventricular hemorrhage: A comparative retrospective analysis on outcome and shunt dependency. *Neurosurg Focus* 32(4):E4, 2012
- Bassan H, Eshel R, Golan I, Kohelet D, Ben Sira L, Mandel D, Levi L, Constantini S, Beni-Adani L, External Ventricular Drainage Study Investigators: Timing of external ventricular drainage and neurodevelopmental outcome in preterm infants with posthemorrhagic hydrocephalus. *Eur J Paediatr Neurol* 16(6):662-670, 2012
- Bondurant CP, Jimenez DF: Epidemiology of cerebrospinal fluid shunting. *Pediatr Neurosurg* 23(5):254-259, 1995
- Borcek AO, Civi S, Golen M, Emmez H, Baykaner MK: An unusual ventriculoperitoneal shunt complication: Spontaneous knot formation. *Turk Neurosurg* 22(2):261-264, 2012
- Borgbjerg BM, Gjerris F, Albeck MJ, Hauerberg J, Børgesen SE: Frequency and causes of shunt revisions in different cerebrospinal fluid shunt types. *Acta Neurochir* 136(3-4):189-194, 1995
- Bowes AL, King-Robson J, Dawes WJ, James G, Aquilina K: Neuroendoscopic surgery in children: Does age at intervention influence safety and efficacy? A single-center experience. *J Neurosurg Pediatr* 20(4):324-328, 2017
- Ceran C, Karadag O, Guranluoglu K, Onal C: Colon perforation and transanal protrusion of ventriculo-peritoneal shunt: Two cases. *İnönü Üniversitesi Tıp Fakültesi Dergisi* 13(4):271-273, 2006
- Christian EA, Melamed EF, Peck E, Krieger MD, Mc Comb JG: Surgical management of hydrocephalus secondary to intraventricular hemorrhage in the preterm infant. *J Neurosurg Pediatr* 17(3):278-284, 2016
- Cinalli G: Alternatives to shunting. *Childs Nerv Syst* 15(11-12): 718-731, 1999

10. Cockle JV, Gopichandran N, Walker JJ, Levene MI, Orsi NM: Matrix metalloproteinases and their tissue inhibitors in preterm perinatal complications. *Reprod Sci* 14(7):629-645, 2007
11. Constantini S, Sgouros S, Kulkarni A: Neuroendoscopy in the youngest age group. *World Neurosurg* 79(2 Suppl):S23.e1-e11, 2013
12. d'Arcangues C, Schulz M, Bühler C, Thome U, Krause M, Thomale UW: Extended experience with neuroendoscopic lavage for posthemorrhagic hydrocephalus in neonates. *World Neurosurg* 116:e217-e224, 2018
13. Demirci H, Borcek AO, Baykaner MK: Third ventriculostomy. *Turkiye Klinikleri J Neurosurg-Special Topics* 5(1):78-82, 2015
14. Deopujari CE, Padayachy L, Azmi A, Figaji A, Samantray SK: Neuroendoscopy for post-infective hydrocephalus in children. *Childs Nerv Syst* 34(10):1905-1914, 2018
15. Etus V, Kahilogullari G, Karabagli H, Unlu A: Early endoscopic ventricular irrigation for the treatment of neonatal posthemorrhagic hydrocephalus: A feasible treatment option or not? A multicenter study. *Turk Neurosurg* 28(1):137-141, 2018
16. Fallah A, Weil AG, Juraschka K, Ibrahim GM, Wang AC, Crevier L, Tseng CH, Kulkarni AV, Ragheb J, Bhatia S: The importance of extent of choroid plexus cauterization in addition to endoscopic third ventriculostomy for infantile hydrocephalus: A retrospective North American observational study using propensity score-adjusted analysis. *J Neurosurg Pediatr* 20(6):503-510, 2017
17. Fulkerson DH, Vachhrajani S, Bohnstedt BN, Patel NB, Patel AJ, Fox BD, Jea A, Boaz JC: Analysis of the risk of shunt failure or infection related to cerebrospinal fluid cell count, protein level, and glucose levels in low-birth-weight premature infants with posthemorrhagic hydrocephalus. *J Neurosurg Pediatr* 7(2):147-151, 2011
18. García-Méndez A, Álvarez-Vázquez L, Agustín-Aguilar F, Collado-Arce G, Sánchez Olivera C: Ventriculosubgaleal shunt in hydrocephalus secondary to intraventricular hemorrhage in prematures. *Gac Med Mex* 150 Suppl 3:279-281, 2014
19. Giuffrè R, Palma L, Fontana M: Extracranial CSF shunting for infantile nontumoral hydrocephalus-a retrospective analysis of 360 cases. *Clin Neurol Neurosurg* 81(3):199-210, 1979
20. Ignelzi RJ, Kirsch WM: Follow-up analysis of ventriculoperitoneal and ventriculoatrial shunts for hydrocephalus. *J Neurosurg* 42(6):679-682, 1975
21. Kulkarni AV, Drake JM, Mallucci CL, Sgouros S, Roth J, Constantini S; Canadian Pediatric Neurosurgery Study Group: Endoscopic third ventriculostomy in the treatment of childhood hydrocephalus. *J Pediatr* 155(2):254-259.e1, 2009
22. Kulkarni AV, Riva-Cambrin J, Holubkov R, Browd SR, Cochrane DD, Drake JM, Limbrick DD, Rozzelle CJ, Simon TD, Tamber MS, Wellons JC 3rd, Whitehead WE, Kestle JR; Hydrocephalus Clinical Research Network: Endoscopic third ventriculostomy in children: Prospective, multicenter results from the Hydrocephalus Clinical Research Network. *J Neurosurg Pediatr* 18(4):423-429, 2016
23. Kulkarni AV, Sgouros S, Constantini S: International infant hydrocephalus study: Initial results of a prospective, multicenter comparison of endoscopic third ventriculostomy (ETV) and shunt for infant hydrocephalus. *Childs Nerv Syst* 32(6):1039-1048, 2016
24. Kumar A, Agrawal D, Sharma BS: The role of endoscopic lavage in recalcitrant multidrug-resistant gram-negative ventriculitis among neurosurgical patients. *World Neurosurg* 93:315-323, 2016
25. Luyt K, Jary SL, Lea CL, Young GJ, Odd DE, Miller HE, Kmita G, Williams C, Blair PS, Hollingworth W, Morgan M, Smith-Collins AP, Walker-Cox S, Aquilina K, Pople I, Whitelaw AG: Drainage, irrigation and fibrinolytic therapy (DRIFT) for posthaemorrhagic ventricular dilatation: 10-year follow-up of a randomised controlled trial. *Arch Dis Child Fetal Neonatal Ed.* 105(5): 466-473, 2020
26. Malm J, Lundkvist B, Eklund A, Koskinen LO, Kristensen B: CSF outflow resistance as predictor of shunt function. A long-term study. *Acta Neurol Scand* 110(3):154-160, 2004
27. Metzemaekers JD, Beks JW, van Popta JS: Cerebrospinal fluid shunting for hydrocephalus: A retrospective analysis. *Acta Neurochir* 88(3-4):75-78, 1987
28. Miyajima M, Shimoji K, Watanabe M, Nakajima M, Ogino I, Arai H: Role of artificial cerebrospinal fluid as perfusate in neuroendoscopic surgery: A basic investigation. *Acta Neurochir (Suppl)* 113:103-107, 2012
29. Moussa WM, Mohamed MA: Efficacy of postoperative antibiotic injection in and around ventriculoperitoneal shunt in reduction of shunt infection: A randomized controlled trial. *Clin Neurol Neurosurg* 143:144-149, 2016
30. Onal SC: History of hydrocephalus. *Turkiye Klinikleri J Neurosurg-Special Topics* 5(1):1-3, 2015
31. Ragel BT, Browd SR, Schmidt RH: Surgical shunt infection: Significant reduction when using intraventricular and systemic antibiotic agents. *J Neurosurg* 105(2):242-247, 2006
32. Riva-Cambrin J, Kestle JRW, Rozzelle CJ, Naftel RP, Alvey JS, Reeder RW, Holubkov R, Browd SR, Cochrane DD, Limbrick DD, Shannon CN, Simon TD, Tamber MS, Wellons JC, Whitehead WE, Kulkarni AV, Hydrocephalus Clinical Research Network: Predictors of success for combined endoscopic third ventriculostomy and choroid plexus cauterization in a North American setting: A Hydrocephalus Clinical Research Network study. *J Neurosurg Pediatr* 24(2):128-138, 2019
33. Sainte-Rose C, Hoffman HJ, Hirsch JF: Shunt failure. *Concepts Pediatr Neurosurg* 9:7-20, 1989
34. Schaumann A, Bühler C, Schulz M, Thomale U: Neuroendoscopic surgery in neonates - indication and results over a 10-year practice. *Childs Nerv Syst* 37(11):3541-3548, 2021
35. Schulz M, Bohner G, Knaus H, Haberl H, Thomale UW: Navigated endoscopic surgery for multiloculated hydrocephalus in children. *J Neurosurg Pediatr* 5(5):434-442, 2010
36. Schulz M, Bühler C, Pohl-Schickinger A, Haberl H, Thomale UW: Neuroendoscopic lavage for the treatment of intraventricular hemorrhage and hydrocephalus in neonates. *J Neurosurg Pediatr* 13(6):626-635, 2014
37. Schulz M, Bühler C, Spors B, Haberl H, Thomale UW: Endoscopic neurosurgery in preterm and term newborn infants-a feasibility report. *Childs Nerv Syst* 29(5):771-779, 2013

38. Tabuchi S, Kadowaki M: Neuroendoscopic surgery for ventriculitis and hydrocephalus after shunt infection and malfunction: Preliminary report of a new strategy. *Asian J Endosc Surg* 8(2):180-184, 2015
39. Terada Y, Mineharu Y, Arakawa Y, Funaki T, Tanji M, Miyamoto S: Effectiveness of neuroendoscopic ventricular irrigation for ventriculitis. *Clin Neurol Neurosurg* 146:147-151, 2016
40. Tirado-Caballero J, Rivero-Garvia M, Arteaga-Romero F, Herreria-Franco J, Lozano-Gonzalez A, Marquez-Rivas J: Neuroendoscopic lavage for the management of posthemorrhagic hydrocephalus in preterm infants: Safety, effectivity, and lessons learned. *J Neurosurg Pediatr* 26(3): 237-246, 2020
41. Wellons JC, Shannon CN, Holubkov R, Riva-Cambrin J, Kulkarni AV, Limbrick DD Jr, Whitehead W, Browd S, Rozzelle C, Simon TD, Tamber MS, Oakes WJ, Drake J, Luerssen TG, Kestle J; Hydrocephalus Clinical Research Network: Shunting outcomes in posthemorrhagic hydrocephalus: Results of a Hydrocephalus Clinical Research Network prospective cohort study. *J Neurosurg Pediatr* 20(1):19-29, 2017
42. Wellons JC, Shannon CN, Kulkarni AV, Simon TD, Riva-Cambrin J, Whitehead WE, Oakes WJ, Drake JM, Luerssen TG, Walker ML, Kestle JRW, Hydrocephalus Clinical Research Network: A multicenter retrospective comparison of conversion from temporary to permanent cerebrospinal fluid diversion in very low birth weight infants with posthemorrhagic hydrocephalus. *J Neurosurg Pediatr* 4(1):50-55, 2009
43. Whitelaw A, Evans D, Carter M, Thoresen M, Wroblewska J, Mandera M, Swietlinski J, Simpson J, Hajivassiliou C, Hunt LP, Pople I: Randomized clinical trial of prevention of hydrocephalus after intraventricular hemorrhage in preterm infants: Brain-washing versus tapping fluid. *Pediatrics* 119(5): e1071-e1078, 2007
44. Whitelaw A, Jary S, Kmita G, Wroblewska J, Musialik-Swietlinska E, Mandera M, Hunt L, Carter M, Pople I: Randomized trial of drainage, irrigation and fibrinolytic therapy for premature infants with posthemorrhagic ventricular dilatation: Developmental outcome at 2 years. *Pediatrics* 125(4):e852-e858, 2010
45. Whitelaw A, Pople I, Cherian S, Evans D, Thoresen M: Phase 1 trial of prevention of hydrocephalus after intraventricular hemorrhage in newborn infants by drainage, irrigation, and fibrinolytic therapy. *Pediatrics* 111(4 Pt 1):759-765, 2003
46. Zhu J, Yang J, Tang C, Cong Z, Cai X, Ma C: Design and validation of a 3D-printed simulator for endoscopic third ventriculostomy. *Childs Nerv Syst* 36(4):743-748, 2020