



The Therapeutic Value of Proanthocyanidin in Experimental Cerebral Vasospasm Following Subarachnoid Hemorrhage

Subaraknoid Kanamayı İzleyen Deneysel Serebral Vazospazmında Proantosiyanidin Terapötik Değeri

Ayhan TEKİNER¹, Muhammet Bahadır YILMAZ¹, Elif POLAT¹, Tuncer GOKER¹, Mustafa Fevzi SARGON², Anıl ARAT³

¹Ministry of Health, Training and Research Hospital, Department of Neurosurgery, Ankara, Turkey.

²Hacettepe University, School of Medicine, Department of Anatomy, Ankara, Turkey

³Hacettepe University, School of Medicine, Department of Radiology, Ankara, Turkey

The Electron Microscopic and Enzymatic Assessments of this study have been presented as a poster at the Joint EANS Annual Meeting- 4th World ICH Conference 2011 and then published in the congress book as an article titled 'Evaluation of the Effect of Proanthocyanidin in Experimental Cerebral Vasospasm: Electron Microscopically and by Biochemical Stress Parameters'.

Corresponding Author: Ayhan TEKİNER / E-mail: tekinerayhan@yahoo.com, tekinerayhan@gmail.com

ABSTRACT

AIM: We aimed to examine the basilar artery in an experimental subarachnoid hemorrhage (SAH) model both from the ultrastructural and radiological aspects and tried to evaluate the benefit of proanthocyanidin (PC), an antioxidant matter, in reducing vasospasm.

MATERIAL and METHODS: A total of 21 male New Zealand rabbits were divided into three groups after performing angiography. Group I: Control group, Group II: Subarachnoid hemorrhage group, Group III: Subarachnoid hemorrhage and Proanthocyanidin group (100 mg/kg/day). Rabbits were sacrificed on the 5th day after angiography. A segment of the basilar artery, 4 mm in length, was prepared for ultrastructural examination.

RESULTS: There was no ultrastructural or radiological abnormality in the basilar artery in Group 1. In the basilar artery digital subtraction angiography (DSA) of Group 2, a statistically significant decrease in basilar artery calibration was found ($p<0.05$). There was no damage in the endothelium, subendothelium, tunica media and adventitia of the basilar artery ultrastructurally but a statistically significant narrowing in lumen diameter was seen. There was also no difference in basilar artery calibration in the DSA of Group 3 ($p>0.05$). No damage was seen in the basilar artery ultrastructurally.

CONCLUSION: Proanthocyanidin with its strong antioxidant effect and possible vasomotor action can significantly attenuate SAH-induced vasospasm.

KEYWORDS: Subarachnoid hemorrhage, Cerebral vasospasm, Proanthocyanidin, Rabbit

ÖZ

AMAÇ: Deneysel subaraknoidal hemoraji modeli oluşturarak, bir antioksidan olan proantosiyanidin baziller arterdeki vazospazmı azaltmadaki etkisini hem radyolojik hem de ultrastrüktürel olarak incelemek.

YÖNTEM ve GEREÇLER: Toplam 21 erkek Yeni Zelanda tavşanı serebral anjiyografi sonrası 3 gruba ayrıldı. Grup I: Kontrol, Grup II: Subaraknoid kanama, Grup III: Subaraknoid kanama ve Proantosiyanidin uygulaması (100 mg/kg/gün). Tavşanlar anjiyografi sonrası 5. günde sakrifiye edildi. 4 mm uzunluğundaki baziller arter segmentleri ultrastrüktürel inceleme için hazırlandı.

BULGULAR: Grup I'de baziller arterde ultrastrüktürel ve radyolojik anormallik yoktu. Grup II'nin baziller arter kalibrasyonunda istatistiksel anlamlı azalma saptandı ($p<0,05$). Baziller arterin endotelium, subendotelium, tunika media ve tunika adventisiasında ultrastrüktürel olarak zedelenme yoktu, fakat lümen çapında istatistiksel anlamlı daralma görüldü. Aynı zamanda grup 3'ün anjiyografisinde baziller arter kalibrasyonunda istatistiksel anlamlı daralma yoktu ($p>0,05$). Baziller arterde ultrastrüktürel zedelenme görülmedi.

SONUÇ: Güçlü antioksidan ve muhtemel vazomotor etkili proantosiyanidin, subaraknoid kanamaya bağlı vazospazmı anlamlı düzeyde azaltabilir.

ANAHTAR SÖZCÜKLER: Subaraknoid kanama, Serebral vazospazm, Proanthocyanidin, Tavşan

INTRODUCTION

Cerebral vasospasm is an important cause of morbidity and mortality following subarachnoid hemorrhage (SAH). While the pathogenesis of cerebral vasospasm has not been exactly understood, it is likely to be multifactorial. Thus the treatment of vasospasm seems to be complicated and the necessity of new drug and treatment modalities are still present.

An important process in arterial narrowing is the imbalance between the endothelium-derived constrictor factor (EDCF, endothelin) and endothelium-derived releasing factor (EDRF, nitric oxide). Evidence has indicated that ENOS and in consequence vasodilatory nitric oxide (NO) levels decrease, whereas levels of vasoconstricting endothelin peptides increase after subarachnoid hemorrhage. A few studies have suggested that an increase in NO production may restore this balance and decrease vasospasm.

Clinical and experimental studies imply that oxygen free radical generation increase after subarachnoid hemorrhage (SAH) and that these radicals and consequently lipid peroxidation may be causally related to the expression of cerebral vasospasm (2, 11, 16). It has been shown that lipid peroxidation inhibition and oxygen free radical scavengers relieve vasospasm in experimental vasospasm models (6, 7).

In this study, a SAH model was formed via autologous blood injection into the rabbit cisterna magna. The ultrastructural changes in the basilar artery that occur with the effect of free radical damage and vasospasm in SAH were examined, proanthocyanidin (PC) was administered as an antioxidant to a group and its effect on these changes was investigated.

MATERIAL and METHODS

Material

The study was conducted at the Ankara University Animal Research Laboratory. A total of 21 male New Zealand rabbits, with body weights of 2.8-3.5 kg, were divided into three groups by the 'simple random sampling method' and given food and water ad libitum. The Ankara University Animal Care and Use Committee approved the experimental protocol. The rabbits were randomly separated into three groups each containing seven rabbits. All rabbits were sacrificed by lethal dose of xylazine and ketamine 5 days later. Right ventricular catheterization was performed for blood examination after median sternotomy. The tissues were removed immediately and evaluated microscopically.

Ultrastructural examination was performed at the laboratory of Ministry of Health, Ankara Training and Research Hospital, Department of Pathology. Digital Subtraction Angiography (DSA) was performed at the laboratory of Ministry of Health, Etlik Training and Research Hospital, Department of Radiology. A microscope (Zeiss®OpMi 99) and microsurgical devices were used during the surgical procedures and decapitation.

All reagents were of analytical grade, prepared fresh each day (except the phosphate buffer) and stored in a refrigerator at

+4°C. The reagents were equilibrated at room temperature for 0.5 h before use when the analysis was initiated or reagent containers were refilled. Phosphate buffers were stable at +4°C for 1 month. The animals were provided standard animal food and water. They stayed in daylight and dark for twelve-hour periods. We obeyed the rules of the Helsinki Final Act and United States of America National Health Institute for the care of the subjects.

Groups

Group 1 (Control group): This group was formed in order to compare the results of the SAH model. 2.5 cc 0.9% NaCl was administered into the cisterna magnas of the 7 subjects by puncture. Five days after angiography, they were perfused and their basilar arteries were resected microsurgically.

Group 2 (SAH group): SAH model in the posterior circulation of the subjects was created as explained below. At the end of the planned period, the subjects were perfused by the same way, sacrificed and the basilar arteries were removed (Fifth day after angiography).

Group 3 (SAH+PC group): After performing SAH, PC was administered for five days. These subjects were fed a diet containing 100 mg/kg/day PC, administered orally via an orogastric injection. The subjects were sacrificed after five days and the basilar arteries were removed.

Performing SAH and Perfusion-Decapitation-Tissue Sampling Procedures:

Anesthesia: Intramuscular ketamine hydrochloride (Ketalar 5% solution, Eczacibasi Medicine with the licence of Parke-Davis, Istanbul) 50mg/kg and xylazine (Rompun 2% solution, Bayer, Istanbul) 8mg/kg were administered to the subjects and anesthesia was obtained. Additional doses were administered when necessary. Oxygen saturation, heart beat rate, systolic, diastolic and mean blood pressure were monitored during the procedures and they were recorded at the 1, 5, 10, 20, 30, 60, 90, 120 minutes. The body temperature was determined by rectal probe. Four subjects died during the study and another four subjects were then included in the study.

Digital Subtraction Angiography (DSA) procedure: An axillary incision was made under anesthesia and axillary arterial catheterization was performed microscopically. Radioopaque matter was administered via this route and radiological images of the posterior circulation and basilar artery was obtained.

Angiography Procedure: All subjects were initially anesthetized with ketamine 10 mg/kg intramuscularly. The subjects were then stabilized in the supine position with the arms abducted 90 degrees. A 2-3 cm incision was made between the biceps and triceps muscles to the chest wall. Passing through the subcutaneous tissue and superficial fascia, the upper brachial artery was explored. The junction of the brachial and axillary arteries was found

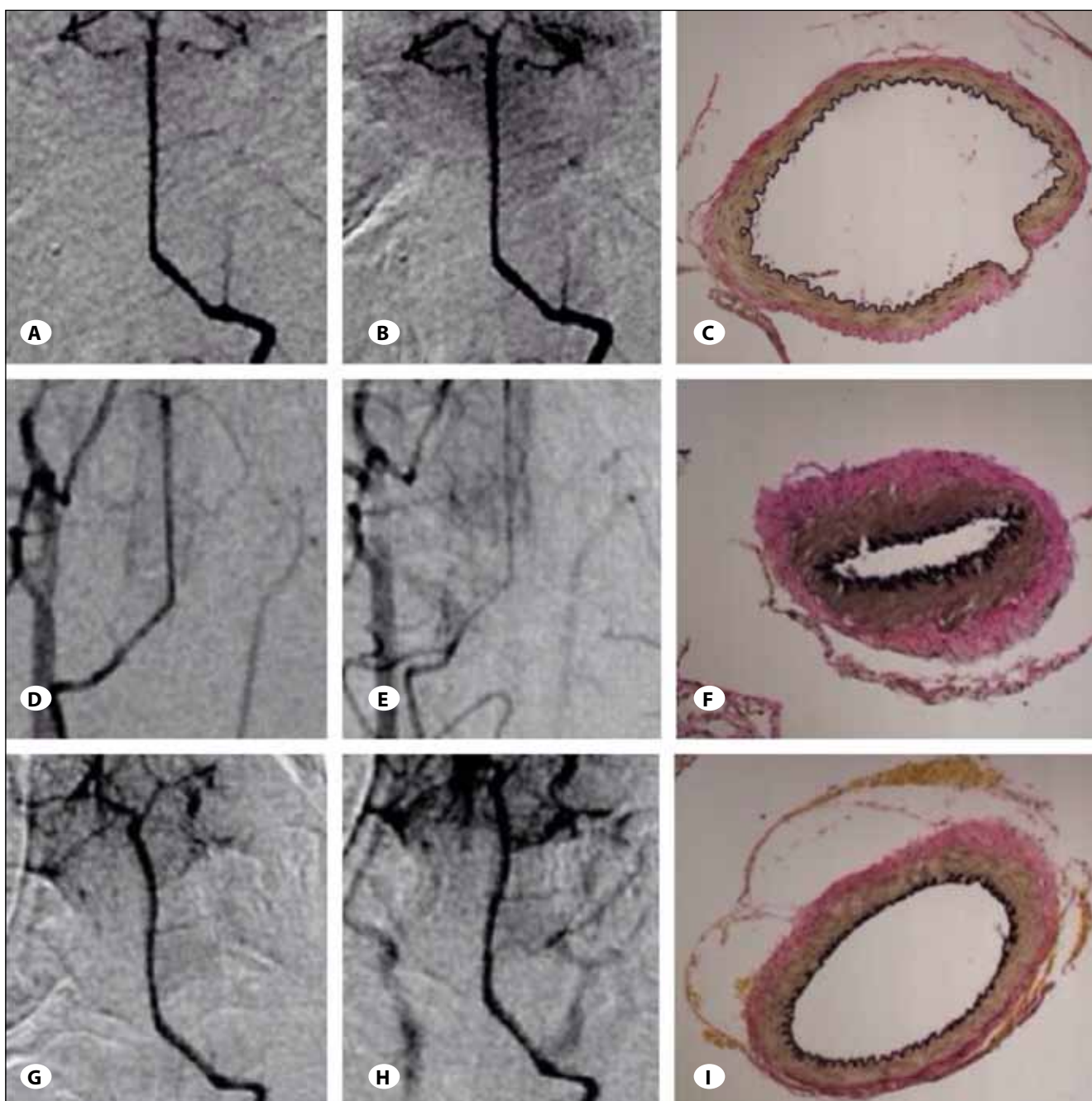


Figure 1: **A)** The first vertebral angiography in the control group (group 1) is seen. **B)** No statistically meaningful vasospasm was seen in vertebral angiography performed on the 5th day. **C)** No ultrastructural change was seen in the basilar artery wall in the control group (x200). **D)** Vertebral angiography of group 2 before performing subarachnoid hemorrhage is seen. **E)** In the 5th day angiography of subarachnoid hemorrhage performed rabbit, statistically meaningful narrowing in artery caliber is seen ($p < 0.005$). **F)** No ultrastructural change in the basilar artery wall is seen in Group 3 but significant narrowing in the lumen is present (x200). **G)** The first vertebral angiography of group 3 is seen. **H)** In the 5th day vertebral artery angiography of the rabbit on which subarachnoid hemorrhage was performed and then Proanthocyanidin was administered for five days, no statistically meaningful narrowing in artery caliber is seen ($p > 0.005$). **I)** No statistically meaningful narrowing and ultrastructural change in basilar artery wall were seen in group3 (x200).

at the lateral aspect of the pectoralis muscle. Axillary artery dilatation was obtained by topical papaverine to simplify the catheterization. Axillary catheterization was performed with a 26-gauge needle using a surgical loop under fluoroscopy guidance; 2.4 ml of 75% contrast medium (Omnipaque 300, GE Healthcare, Princeton, NT) was administered at a rate of the vertebrobasilar system at the anteroposterior plane was obtained with an Axiom Artis uniplane fluoroscopy system (Siemens, Erlangen, Germany) as the subjects were placed in the isocenter of the imaging system. The diameters of the basilar artery at the upper, medial and lower portion were measured using the automated measurement system of this angiographic system.

Performing SAH: The experimental SAH model that was performed first by Johshita et al. in 1992 was used in this study (10). The model was created by the injection of arterial autologous blood into the cisterna magna of rabbits. Cisterna magna puncture was performed percutaneously with a 23G butterfly set. Clear cerebrospinal fluid flow was seen. Non-heparinized, 2.5cc arterial autologous blood that was drawn from the auricular vein was injected into the posterior circulation and the SAH model was created. The rabbits were hold in the head-down position for 10 minutes in order to constitute a clot around the basilar artery. During the injection of blood into cisterna magna, respiratory arrest for 15-30 seconds was seen and recovered spontaneously.

Perfusion and Removing the Basilar Arteries: At the end of the considered time period, the subjects were taken under anesthesia by the same way. The animals were perfused by injecting 1000 cc phosphate buffer with 100 mmHg pressure via a catheter from the left ventricle to the aorta. The scalp was incised and the calvarium, and then the brain and brainstem were exposed. The basilar artery was resected microsurgically for histological studies.

Applying Proanthocyanidin: A commercially available grape seed PC extract was purchased from General Nutrition Corporation Pittsburgh, PA 15222 USA (Proanthocyanidin: 100 mg, 30 capsules). Nutra Manufacturing, Inc 1050 Woodruff Road Greenville SC 9607 ABD.

Histopathological Examination: The basilar arteries samples that were fixed in formaldehyde were then immersed in paraffin. The distal one third of each basilar artery was prepared for light microscopic study. The luminal diameter and thickness of the artery wall were measured just distal to the basilar bifurcation. Sections of the vessels were prepared with Verhoeff's elastic stain, and were examined under 40x and 200x magnification. Morphometric measurements of the luminal diameter, wall thickness, and average arterial diameter were obtained using a Zeiss IBAS computerized image analysis system (Karl Zeiss Company, Oberkochen, West Germany). The presence of folding and corrugation, histopathological criteria of vasospasm that are seen in the acute period, were investigated in the experiment group by using the hematoxylin eosin stain.

These data were statistically analyzed using the Mann-Whitney U test, and a P value less than 0.05 was considered to indicate statistical significance.

Statistical Analysis: Descriptive statistics were expressed as mean, median and min-max. Differences among the groups were analyzed using the Kruskal-Wallis test followed by the multiple comparison procedure of Conover. Statistical analyses were performed via the SPSS 15.0 statistical software. P values less than 0.05 were evaluated as statistically significant.

RESULTS

Group 1 (Control group)

The endothelium, subendothelium, tunica media and tunica adventitia did not show any ultrastructural pathological change. There was no vasospasm. Basilar artery caliber was evaluated before and after the procedure by vertebral angiograms and did not reach statistical significance ($p > 0.05$) (Figure 1A-C).

Group 2 (SAH Group)

The endothelium did not show any ultrastructural damage. The subendothelium, tunica media and tunica adventitia were ultrastructurally normal in this group. There was a statistically significant narrowing of the vascular lumen diameter that was showing vasospasm ($p < 0.005$). A reduction in basilar artery caliber was seen after the procedure ($p < 0.005$) (Figure 1D-F).

Group 3 (SAH+PC Group)

The endothelium did not show any ultrastructural damage. The subendothelium, tunica media and tunica adventitia were ultrastructurally normal in this group. The narrowing of the vascular lumen diameter was not significant ($p > 0.005$). There was also no statistically significant change in basilar artery caliber before and after the procedure ($p > 0.05$) (Figure 1G-I).

DISCUSSION

Cerebral vasospasm occurring after SAH defines clinical and angiopathic changes following aneurysmal bleeding. Since it is one of the major causes of mortality and morbidity, the goal of treatment of SAH is the prevention of vasospasm and delayed ischemic neurological deficits (4, 5, 16, 27-29). Although there are many invasive and non-invasive methods for the treatment and prevention, there is no specific globally accepted algorithm. There are several theories exploring the pathogenesis of cerebral vasospasm, and some have concluded that cerebral vasospasm results from multiple factors (5, 26, 32). However, most studies also emphasize that hemoglobin is the most important spasmogen after SAH. Hemoglobin has a high affinity to bind NO, causing impairment of the balance between EDRF/EDCF, which is essential to maintain normal vascular tonus (4, 14, 22). NO produced by endothelial cells diffuses to the local smooth muscle cells of blood vessels and activates guanylate cyclase (GC). Activated GC produces cGMP, resulting in vasodilation.

Inhibition of phosphodiesterase supplying cGMP hydrolysis theoretically induces vasodilation (8, 12, 19, 21).

Cerebral vasospasm is generally attributed to the presence of blood products and especially OxyHb in the subarachnoid space. Although the trigger role of OxyHb in developing vasospasm is well known, the exact mechanism(s) of vasospasm is not yet clear. The possible mechanisms are as follows: increased endothelin activity, ADP-induced vasomotor changes, inhibition of NO pathway, increased free radical products and lipid peroxidation stimulating the PKC pathway in vascular smooth muscle, and adhesion molecule pathways (16, 23). OxyHb-induced free radical products and lipid peroxidation are mostly accepted as the first step to start vasospasm (9, 11). Many authors have also shown the role of free radicals and lipid peroxidation in the pathogenesis of vasospasm in experimental and clinical studies (1, 11, 18, 25). The important role of free radical products was studied in our previous experimental study; free radical production and lipid peroxidation was started at the cisterna magna in cats by hemoglobin-free erythrocyte membrane mixed with NADPH and ADP and ferrous sulphate (2). Angiographical and histopathological results were the same with vasospasm induced by SAH.

These results demonstrated that even without OxyHb, vasospasm could be initiated by other agents that produce free radicals and start lipid peroxidation. Since the alteration of endothelial cells is a major part of the morphological presentation of vasospasm, the role of apoptosis in the pathogenesis of vasospasm has recently been discussed in the literature but the results are still not clear (15, 20, 30, 31).

Several reports on the role of PC as a free radical scavenger and inhibitor of lipid peroxidation have been published. In a study by Stücker et al. in 1996, the effects of Ginkgo biloba extract on arteriolar vasospasm was examined in the rat cremaster muscle and Ginkgo biloba was seen to inhibit the spasm at a rate of 80% (24).

Our previous experimental studies on trauma-induced spinal cord injury showed that PC dramatically reduced lipid peroxidation and facilitated clinical recovery. In this experiment, cisternal injection of whole blood induced histopathologically severe vasospasm in the SAH group. Histopathological examination also revealed significant endothelial cell damage, which involves apoptosis corrugated internal elastic lamina and thickening and damaged smooth muscle layer. Statistically significant relaxant effects of melatonin were demonstrated in this experiment when the drug was administered following SAH. Another important histopathological result was good protection of endothelial cells from apoptosis in Group 3. These results revealed that treatment with PC with 100 mg/kg.

In the postmortem histopathological examination, damage to the basilar arteries during dissection and decapitation may have increased the possibility of mistakes in the study (31). On the other hand, angiographic examination, which can

be carried out on live subjects and repeated easily, seems to have been a more useful test in recent years. Magnetic resonance angiography (MRA), a corrosion cast technique, can also be used for the assessment of intracranial circulation in small animals as in conventional angiography (13). We used conventional angiography because of the difficulties and insufficiencies of the corrosion cast technique. The angiograms were carried out using biplane digital subtraction angiography (DSA) equipment for the assessment of basilar arteries. Only a few reports in the literature have dealt with angiographic investigation of vasospasm in the rat. Delgado et al. exposed the angiographic properties of cerebral vasospasm in rats. They pointed out that vasospasm had biphasic characteristics, showing an increase especially in the 10th minute and the 2nd day, ending at the 5th day (3). We performed angiography to evaluate acute and chronic cerebral vasospasm and observed cerebral vasospasm at the 2nd and the 4th days. We found diameters of 0.047 mm and 0.035 mm, respectively. Longo et al. measured the middle third of the basilar artery to evaluate vasospasm (13). Due to the non-uniform characteristics of the vasospasm, we assessed three measurements from three different points of the basilar artery. As an interesting result, tadalafil showed the greatest vasodilatory effect on the most vasoconstricted region of the artery, the middle and lower regions on the 2nd day and upper region on the 4th day. The measurement results from these three points showed statistically significant differences in the degree of vasospasm, so we had to include the whole length of the artery to evaluate the vasospasm correctly. This can be explained by the different amounts of blood around the vessel walls. Evaluation of the whole vessel length is therefore essential to assess the vasospasm correctly.

CONCLUSION

Proanthocyanidin with its strong antioxidant effect and possible vasomotor action can significantly attenuate SAH-induced vasospasm.

REFERENCES

1. Arthur AS, Fergus AH, Lanzino G, Mathys J, Kassell NF, Lee KS: Systemic administration of the iron chelator deferiprone attenuates subarachnoid hemorrhage-induced cerebral vasospasm in the rabbit. *Neurosurgery* 41: 1385–1391, 1997
2. Caner H, Oruckaptan H, Bolay H, Kilinç K, Senaati S, Benli K, Ayhan A: The role of lipid peroxidation in the genesis of vasospasm secondary to subarachnoid hemorrhage. *Kobe J Med Sci* 37: 13–20, 1991
3. Delgado T, Brismar J, Svendgaard NA: Subarachnoid hemorrhage in the rat: Angiography and fluorescence microscopy of the major cerebral arteries. *Stroke* 16:595–602, 1985
4. Dietrich HH, Dacey RG: Molecular keys to the problems of cerebral vasospasm. *Neurosurgery* 46:517–530, 2000
5. Dorsch NWC, King MT: A review of cerebral vasospasm in aneurysmal subarachnoid hemorrhage: I. Incidence and effect. *J Clin Neuroscience* 1:19–26, 1994

6. Grieb P, Ryba MS, Sawicki J, Chrapusta SJ: Oral coenzyme Q10 administration prevents the development of ischemic brain lesions in a rabbit model of symptomatic vasospasm. *Acta Neuropathol (Berl)* 94: 363–368, 1997
7. Handa Y, Kaneko M, Takeuchi H, Tsuchida A, Kobayashi H, Kubota T: Effect of an antioxidant, ebselen, on development of chronic cerebral vasospasm after subarachnoid hemorrhage in primates. *Surg Neurol* 53:323–329, 2000
8. Inoha S, Inamura T, Ikezaki K, Nakamizo A, Amano T, Fukui M: Type V phosphodiesterase expression in cerebral arteries with vasospasm after subarachnoid hemorrhage in a canine model. *Neurol Res* 24(6):607–612, 2002
9. Janjua N, Mayer SA: Cerebral vasospasm after subarachnoid hemorrhage. *Curr Opin Crit Care* 9: 113–119, 2003
10. Johshita H, Kassell NF, Sasaki T, Nakagomi T, Ogawa H: Biphasic constriction of rabbit basilar artery following experimental subarachnoid haemorrhage: A morphometric study. *Surg Neurol* 37:106–114, 1992
11. Kamezaki T, Yanaka K, Nagase S, Fujita K, Kato N, Nose T: Increased levels of lipid peroxides as predictive of symptomatic vasospasm and poor outcome after aneurysmal subarachnoid hemorrhage. *J Neurosurg* 97: 1302–1305, 2002
12. Kim P, Schini VB, Sundt TM Jr, Vanhoutte PM: Reduced production of cGMP underlies the loss of endothelium-dependent relaxations in the canine basilar artery after subarachnoid hemorrhage. *Circ Res* 70(2):248–256, 1992
13. Longo M, Blandino A, Ascenti G, Ricciardi GK, Granata F, Vinci S: Cerebral angiography in the rat with mammographic equipment: A simple, cost-effective method for assessing vasospasm in experimental subarachnoid haemorrhage. *Neuroradiology* 44(8):689–694, 2002
14. Macdonald RL, Weir BKA: A review of hemoglobin and the pathogenesis of cerebral vasospasm. *Stroke* 22:971–982, 1991
15. Matz PG, Copin JC, Chan PH: Cell death after exposure to subarachnoid hemolysate correlates inversely with expression of CuZn-superoxide dismutase. *Stroke* 31: 2450–2459, 2000
16. Mayberg MR: Cerebral vasospasm. *Neurosurg Clin N Am* 9:615–627, 1998
17. Megyesi JF, Vollrath B, Cook DA, Findlay JM: In vivo animal models of cerebral vasospasm: A review. *Neurosurgery* 46 (2):448–460, 2000
18. Mori T, Nagata K, Town T, Tan J, Matsui T, Asano T: Intracisternal increase of superoxide anion production in a canine subarachnoid hemorrhage model. *Stroke* 32: 636–642, 2001
19. Nishizawa S, Yamamoto S, Tokoyama T, Uemura K: Dysfunction of NO induces protein kinase C activation resulting in vasospasm after SAH. *Neurol Res* 19:558–562, 1997
20. Ogihara K, Aoki K, Zubkov AY, Zhang JH: Oxyhemoglobin produces apoptosis and necrosis in cultured smooth muscle cells. *Brain Res* 889: 89–97, 2001
21. Ohta S, Nishihara J, Oka Y, Todo H, Kumon Y, Sasaki S: Possible mechanism to induce protein kinase C-dependent arterial smooth muscle contraction after subarachnoid hemorrhage. *Acta Neurochir (Wien)* 137:217–225, 1995
22. Osaka K: Prolonged vasospasm produced by the breakdown products of erythrocytes. *J Neurosurgery* 47:403–411, 1977
23. Sobey CG, Faraci FM: Subarachnoid haemorrhage: What happens to the cerebral arteries? *Clin Exp Pharmacol Physiol* 25:867–876, 1998
24. Stücker O, Pons C, Duverger JP, Drieu K: Effects of Ginkgo biloba extract (EGb 761) on arteriolar spasm in a rat cremaster muscle preparation. *Int J Microcirc Clin Exp* 16(2):98–104, 1996
25. Tosaka M, Hashiba Y, Saito N, Imai H, Shimizu T, Sasaki T: Contractile responses to reactive oxygen species in the canine basilar artery in vitro: Selective inhibitory effect of MCI-186, a new hydroxyl radical scavenger. *Acta Neurochir (Wien)* 144: 1305–1310, 2002
26. Weir B, Macdonald RL, Stoodley M: Etiology of vasospasm. *Acta Neurochir Suppl (Wien)* 72:27–46, 1999
27. Wilkins RH: Attempted prevention or treatment of intracranial arterial spasm: A survey. *Neurosurgery* 6(2):198–210, 1980
28. Yasargil MG: Clinical considerations, surgery of the intracranial aneurysms and result. In: *Microneurosurgery, Vol:II*, New-York: Thieme Stratton Inc, 1990: 17–18
29. Youmans JR: *Neurological surgery*. Philadelphia: WB Saunders Co, 1990: 1644–1660
30. Zubkov AY, Ogihara K, Bernanke DH, Parent AD, Zhang J: Apoptosis of endothelial cells in vessels affected by cerebral vasospasm. *Surg Neurol* 53: 260–266, 2000
31. Zubkov AY, Tibbs RE, Aoki K, Zhang JH: Morphological changes of cerebral penetrating arteries in a canine double hemorrhage model. *Surg Neurol* 54: 212–219, 2000
32. Zubkov AY, Nanda A, Zhang JH: Signal transduction pathways in cerebral vasospasm. *Pathophysiology* 9:47–61, 2003