

## Unilateral Transverse Sinus Aplasia: A Case Report

SÜLEYMAN BAYKAL, SAVAŞ CEYLAN, FADIL AKTÜRK, HASAN DİNÇ,  
KAYHAN KUZEYLİ, SONER DURU, ERAY SÖYLEV

Karadeniz Technical University, Medical Faculty, Department of Neurosurgery (SB, SC, SD, ES, KK, FA) and Radiology (HD), Trabzon - Türkiye

**Abstract :** A case of transverse sinus aplasia associated with torcular Herophili meningioma is presented. The angiography and magnetic resonance imaging findings are demonstrated.

**Key Words :** Angiography, Dural sinus, Magnetic Resonance Imaging, Meningioma.

### INTRODUCTION

The venous system of the brain was first studied angiographically by Moniz in 1927 (4). Kaplan et al. (3) studied variations of the cerebral dural sinuses in their autopsy series. Variations of the dural venous sinuses in the region of the torcular Herophili have been described by some authors (1,2,8).

We present a case of a transverse sinus aplasia associated with torcular Herophili meningioma. This anomaly will be considered along with a review of the relevant literature.

### CASE REPORT

This 64-year old man noted mild headache for four months. Physical examination revealed a mild ataxia.

The medical history included normal cervical lymph node biopsy for cervical lymphadenopathy in 1985.

Plain skull x rays demonstrated no abnormality. Computerized tomography (CT) showed a well demarcated, round, hyperdense tumour that was not enhanced after intravenous contrast medium ad-

ministration in the vicinity of the right lateral sinus and torcular Herophili. Magnetic resonance (MR) imaging demonstrated an isointense tumour on T1-weighted image (Fig. 1). On all MR images, there was no signal relating to the left lateral sinus (Fig.2).

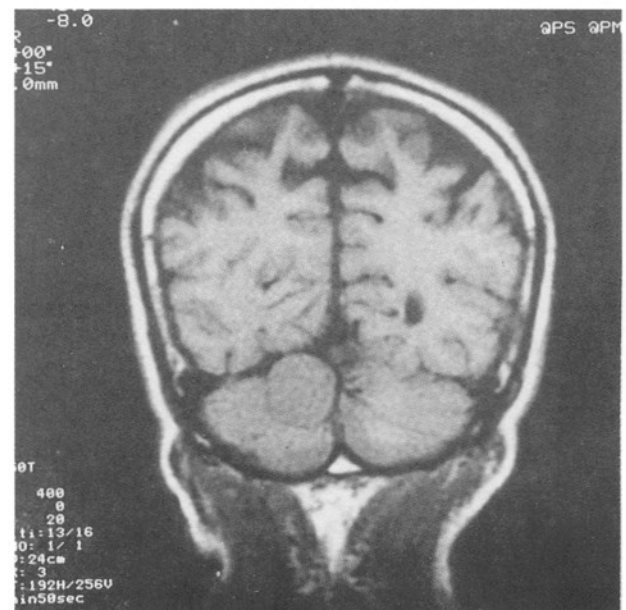


Fig. 1 : MR images, demonstrating the tumour on coronal T1-weighted image. Note also the intensity and location of the tumour.

Digital arterial subtraction angiography revealed an absence of left lateral sinus (Fig. 3). There was no tumour staining on angiographic images.

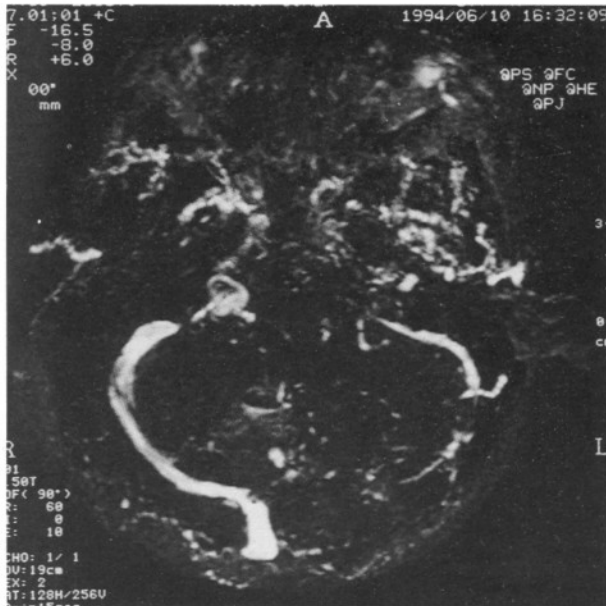


Fig. 2 : MR-angio image, demonstrating a venous sinus pattern. Note the absence of the left lateral sinus.

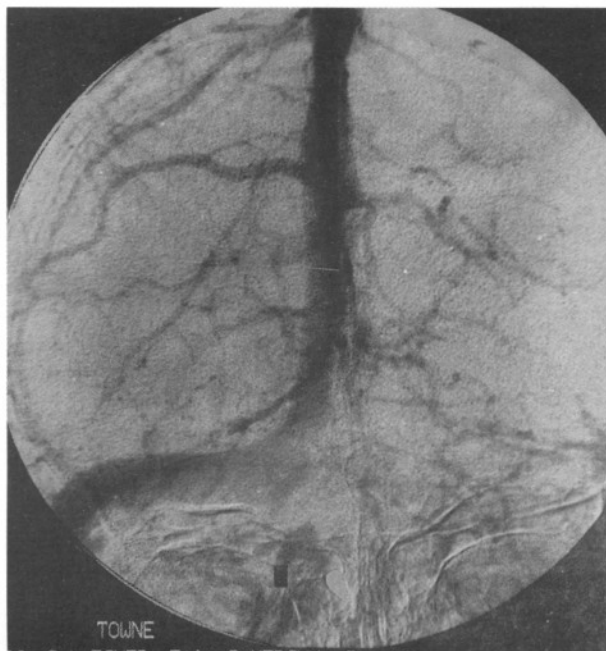


Fig. 3 : Angiogram in the venous sinus space showing the absence of filling of the left lateral sinus.

**Operation :** A craniectomy was performed. The tumour was exposed by elevating the posterior fossa dura. There was no transverse sinus on the left site.

The tumour was well-capsulated and avascular and attached to the right lateral sinus. It was evacuated by CUSA subtotally, because of the absence of the opposite transverse sinus and invasion of the right transverse sinus by the tumour.

The patient was discharged 11 days after surgery. The postoperative course was uneventful.

**Pathological examination.** Microscopic examination showed a benign tumour, meningioma.

### DISCUSSION

In about one-third of individuals, the superior sagittal sinus may diverge from the torcula and not drain into it. In this situation, the superior sagittal sinus is three times more likely to drain into the right transverse sinus. The straight sinus, in turn, drains into the left transverse sinus (5). Das and Hasan reported cases in which a lateral sinus was absent and found two occurrences in 200 cadavers examined (2). Bisaria reported some anatomical variations of venous sinuses in the region of the torcular Herophili in 110 adult cadavers (1). He classified these into three types: Type I those specimens in which the sagittal sinus drains into one lateral sinus and the straight sinus into the other, with no connection between the two., Type II those in which the superior sagittal sinus and the straight sinus fork, and the forks from both sinuses join to form the lateral sinuses., Type III those in which a confluence of sinuses exists. In the same study, in one specimen, the left transverse sinus began as a tentorial vein, whereas the superior sagittal sinus was continuous with the right transverse sinus and straight sinus. In no case was total aplasia of one transverse sinus, present (1). The transverse sinus itself may have multiple openings into the confluent of sinuses or there may be aplasia of one transverse sinus (9) as in our case.

Lateral sinus hypoplasia may be difficult to differentiate angiographically from lateral sinus thrombosis. For this reason, magnetic resonance imaging is an excellent tool for the evaluation of lateral sinus thrombosis or hypoplasia (7) as our case (Fig. 3).

Torcular meningiomas are a particularly difficult group of tentorial tumours. Avoiding complications after demonstration of the meningioma by CT and MRI requires angiographic demonstration of the venous drainage pattern (6). The surgical decision

and approach depend on the dural sinus drainage pattern. In our case, the decision for subtotal removal of the tumour was made on the basis of the absence of the opposite lateral dural sinus.

In conclusion, complete aplasia of the transverse sinus appears to be rare. The surgical importance of such an occurrence is obvious.

**Correspondence** : Dr. Süleyman Baykal  
KTÜ Tıp Fakültesi  
Nöroşirürji Anabilim Dalı  
61080, Trabzon - Türkiye  
Tel : 325 30 11/540

### REFERENCES

1. Bisaria KK: Anatomic variations of venous sinuses in the region of the torcular Herophili. *J Neurosurg* 62:90-95, 1985.
2. Das AC, Hasan M: The occipital sinus. *J Neurosurg* 33:307-311, 1970.
3. Kaplan HA, Browder J, Knightly JJ: Variations of the cerebral dural sinuses at the torcular herophili. *Am J Surg* 124 (4): 456-461, 1972.
4. Kapp JP, Schmidek HH: The cerebral venous system and its disorders. Grune and Stratton Inc. Orlando, 1984, pp:1-249.
5. Kido DK, Baker RA, Rumbaugh CL: Normal cerebral vascular anatomy, in Abrams HL (Ed), *Abrams Angiography, Vascular and Interventional Radiology*. Little, Brown and Company, Boston, 1983, pp 231-270.
6. Malis LI: Tentorial, Torcular, and Paratorcular Meningiomas, in Apuzzo MLJ (Ed), *Brain Surgery, Vol I*, New York, Churchill Livingstone, 1993 pp 231-47.
7. Mas JL, Meder JF, Meary E, Bousser MG: Magnetic resonance imaging in lateral sinus hypoplasia and thrombosis. *Stroke* (21(9): 1350-6, 1990.
8. Saxena RC, Beg MAQ: Double straight sinus: Report of six cases. *J Neurosurg* 39:540-542, 1973.
9. Silver JM, Wilkins RH: Persistent embryonic intracranial and extracranial vessels, in Wilkins RH and Rengachary SS (Eds), *Neurosurgery Update II, Vascular, Spinal, Pediatric, and Functional Neurosurgery*. McGraw-Hill Inc. New York, 1985, pp 50-59.