

Radiological and Scintigraphic Evaluation Versus Stereotaxic Biopsy for Intracranial Hypodense Lesions: A Comparative Study

İntrakranial Hipodens Lezyonlar için Radyolojik ve Sintigrafik Değerlendirmenin Stereotaksik Biyopsi ile Karşılaştırılması

ABSTRACT

AIM: Intracranial hypodense lesions include a wide group of pathologies with different structures and characters. Although the radiological imaging properties of these neoplastic and non-neoplastic lesions are similar, treatment modalities for each lesion differs due to histopathological structure.

MATERIAL and METHODS: In this study we have compared the results of radiological and scintigraphic evaluations with the results of stereotaxic biopsies to figure out the diagnostic impact of these non-invasive modalities. 16 patients who admitted to outpatient clinics with headache and/or seizure complaints were included in the study.

RESULTS: MR spectroscopic images diagnosed the lesions as accurately as stereotaxic biopsies.

CONCLUSION: Although stereotaxic biopsy keeps the label of "gold standard" when establishing a diagnosis for these lesions, modern radiological modalities are quite reliable.

KEYWORDS: Cerebral hypodense lesion, Stereotaxic biopsy, Proton MR spectroscopy

ÖZ

AMAÇ: İntrakraniyal hipodens lezyonlar, geniş bir spektrum gösteren, farklı yapı ve karaktere sahip bir grup patolojiden oluşur. Her ne kadar birçok neoplastik (düşük gradeli glial tümörler ve metastatik CA, vb.) ve non neoplastik patolojilerin (serebrit, enfarkt, gliozis, vb.) oluşturduğu bu lezyonlar benzer radyolojik görüntü özelliklerine sahip olsa da histolojik yapılarından dolayı tedavi yöntemleri oldukça farklılıklar göstermektedir.

YÖNTEM ve GEREÇ: Nöroloji / Nöroşirürji polikliniklerine baş ağrısı ve/veya bayılma yakınması ile baş vuran, BT görüntülemesinde hipodens lezyon saptanan toplam 16 olgu çalışmaya dahil edilmiştir. Kalsifikasyon, kist ve kanama bulguları içeren olgular çalışma dışı bırakılmıştır.

BULGULAR: MR spektroskopisi lezyonları stereotaksik biyopsi kadar doğru tanımladı.

SONUÇ: MRS'nin yüksek oranda tanı değerine sahip olduğu saptanmış olsa da, stereotaksik biyopsi tekniğinin, yüksek tanı değeri ve düşük morbitide/mortalite oranları ile halen bu grup lezyonlarda en uygun tanı yöntemi olarak geçerliliğini sürdürdüğü kanısındayız.

ANAHTAR SÖZCÜKLER: Serebral hipodens lezyon, Stereotaksik biyopsi, Proton MR spektroskopisi

Murat KUTLAY¹
Serdar KAYA²
Kıvanç TOPUZ³
Ahmet COLAK⁴
Nusret DEMİRCAN⁵
Kaan UNGÖREN⁶
Murat VELİOĞLU⁷

1,3,4,5,6 GATA Haydarpaşa Training Hospital, Neurosurgery Department, Istanbul, Turkey
2 GATA, Neurosurgery Department, Ankara, Turkey
7 GATA Haydarpaşa Training Hospital, Radiology Department, Istanbul, Turkey

Received : 12.04.2009

Accepted : 10.12.2009

Correspondence address:

Serdar KAYA

Phone : +90 216 542 28 15

E-mail : serdarockk@yahoo.com

INTRODUCTION

Intracranial hypodense lesions include a wide group of pathologies with different structures and characteristics (20). Although the radiological imaging properties of these neoplastic (gliomas, metastasis) and non-neoplastic (cerebritis, infarct, gliosis) lesions are similar, treatment modalities for each lesion differs due to the histopathological structure (20, 24). These intraaxial, minimally or non-enhancing lesions look hypodense on computed tomography (CT) without remarkable mass effect (Figure 1). Necroses, haemorrhages, cysts and calcifications may not be included in the list of differential diagnosis. Although the lesion borders, contrast enhancement and tissue characteristics may be well explained by magnetic resonance imaging (MRI), these non-specific findings will not help to ascertain the neoplastic character of the lesion or the specific diagnosis (20, 24). Thus the treatment modality cannot be easily assigned for such lesions. Modern radiological and scintigraphic imaging modalities (diffusion-weighted MRI, MR spectroscopy), perfusion-weighted MRI, functional MRI, molecular imaging; positron emission tomography [PET]), single photon emission computed tomography [SPECT]) supply morphological, functional and metabolic data for cerebral lesions.

Clinical symptoms and findings of intracranial hypodense lesions are usually similar. Complaints at admission include headache, seizure and neurological disturbances (20, 24). Current gold standard modality to establish a diagnosis for these lesions is histopathological evaluation by surgical biopsies; open or stereotaxic.

In this study we have compared the results of radiological (CT, MR, MRS) and scintigraphic (SPECT) evaluations with the results of stereotaxic biopsies to figure out the diagnostic impact of these non-invasive modalities.

MATERIALS and METHODS

Sixteen cases who had been admitted to neurology and neurosurgery outpatient clinics with headache and/or seizure complaints with normal neurological examination findings and hypodense lesions on CT images were included in the study. Fifteen were primary cases and one was a patient who was previously treated with surgery and

radiotherapy for glioma. Cases with calcification, cyst and haemorrhage findings on CT were excluded. Signed informed consents were obtained from each and every case included.

Our series consisted of 6 (37,5%) women and 10 (62,5%) men with supratentorial, intraparenchymal hypodense lesions. Mean age was 32.5 ± 8.7 years (range 21-44). Most frequent complaint was headache (10 cases, 62.5%) followed by seizure (5 partial, 3 generalized with a sum of 8 cases, 50%) and 2 cases (12.5%) had both two. Lesions were localized on right hemisphere in 9 cases (56.25%) and on left hemisphere in 7 cases (43.75%). Six cases (37.5%) had frontal, 4 cases (25%) had temporal, 4 cases (25%) had occipital and 2 cases (12.5%) had parietal lesions.

MR images were obtained with a 1.5-T MR system (Magnetom Vision; Siemens, Erlangen, Germany). Routine brain imaging sequence was carried out in axial, coronal, and sagittal plane. A turbo-spin echo pulse sequence was applied to obtain axial T1-weighted (repetition time, 400-600 milliseconds; echo time, 30-60 milliseconds) and T2-weighted (repetition time, 2800-4000 milliseconds; echo time, 80-120 milliseconds) images. A 256x256 matrix was used with a 5-mm section thickness. Contrast-enhanced T1-weighted images were obtained in all patients by using 0.1 mmol gadopentetate dimeglumine per kilogram of body weight (Figure 2). MR images were evaluated by the same neuroradiologist in terms of density (hypodense/isodense/hyperdense), intensity (hypointense/isointense/hyperintense), mass effect (remarkable/minimal/none) and contrast enhancement (remarkable/minimal/none). The neuroradiologist did not know the preoperatively established possible diagnoses. The distinction between "remarkable", "minimal" and "none" was made by means of visual assessment.

Radiological imaging properties and possible diagnoses were listed. List of possible diagnoses included infarct, gliosis, cerebritis, glioma and radiation necrosis.

Proton MR spectroscopic evaluation (MRS) was maintained for all cases (1.5-T Magnetom Vision; Siemens, Erlangen, Germany) N-acetyl aspartate (NAA), choline and creatinine peaks were obtained in this analysis (Figure 3). Possible diagnoses were established by the same neuroradiologist through the values of these metabolites. For cases with high

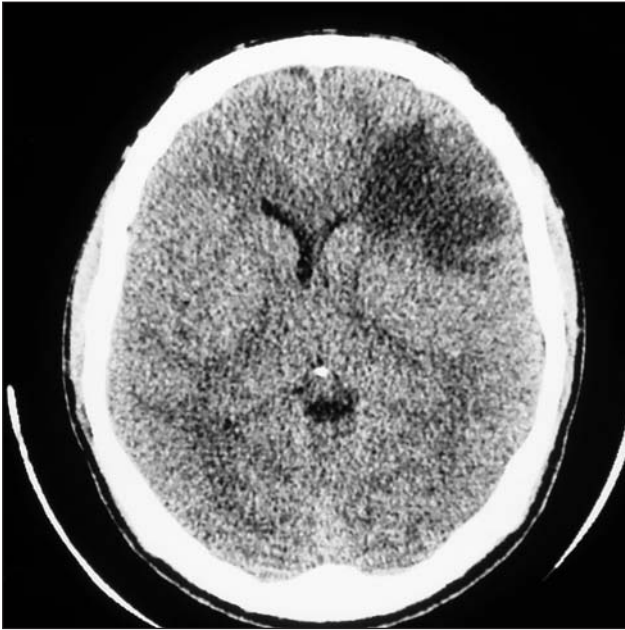

Figure 1: CT of sample case with hypodense lesion.

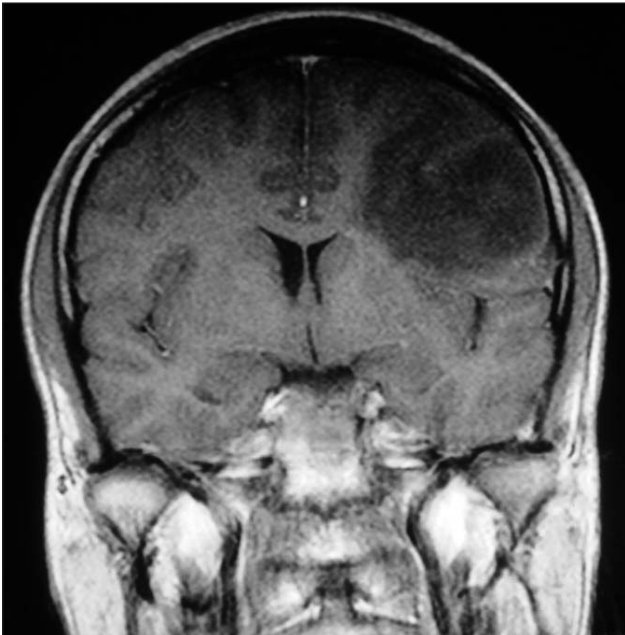

Figure 2: T1W MRI of sample case with no contrast enhancement and minimal mass effect.

choline and low NAA values glioma and cerebritis; and for cases with normal or low choline and low NAA values infarct and gliosis were possible diagnoses.

Eventually all cases underwent brain SPECT (Siemens E-CAM Plus gamma camera and fan beam collimator, Erlangen, Germany). Cases with possible infarct –by radiological evaluation- had

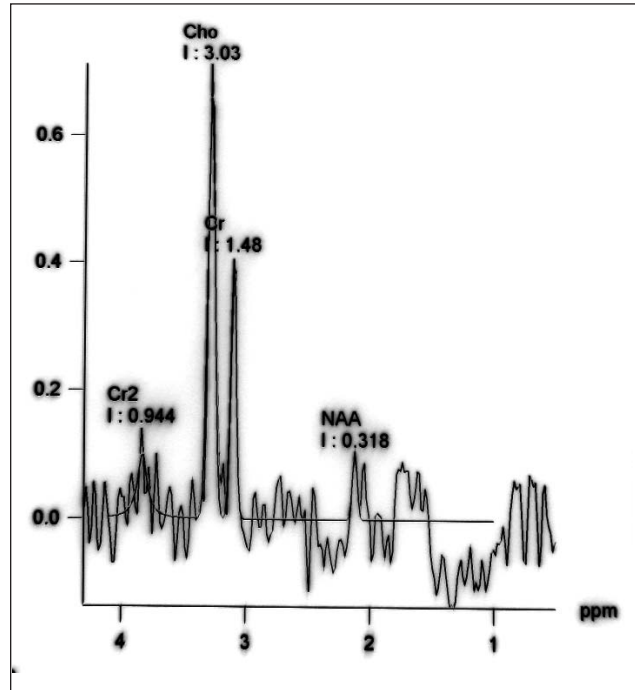


Figure 3: MRS analyses of the case with high choline and low NAA levels. Case was diagnosed as “Glioma” before stereotaxic biopsy and the diagnosis was confirmed consequently.

99mTechnetium-hexamethyl propylamine oxime (99m Tc-HMPAO) and cases with possible glioma and cerebritis had 99m Tc-sestamibi for qualitative SPECT analysis. Possible diagnosis for lesions with Tc-99m-HMPAO hypoactivity was infarct, and for lesions with Tc-99m-sestamibi hyperactivity was glioma. For cases with normal brain parenchyma activity no possible diagnosis was established.

Following these non-invasive evaluation processes, all cases underwent stereotaxic biopsy for histopathological diagnosis. The Leksell Model ‘G’ Stereotactic system (AB Elekta Instruments, Stockholm, Sweden) was used for all of our procedures. Following coordinate frame fixation under local anesthesia, intravenous contrast-enhanced MR images were obtained with 5-mm thick slices to determine the target coordinates. The patient was then transported to the operating room where the stereotactic procedure was performed under local anesthesia. A 5mm hole was made on the calculated entry point, multiple lesion samples were obtained from the planned depth and the operation was finished. Immediately after the operation all cases had CT scans to detect complications and to assess the adequacy of trajectory.

The final diagnosis, based upon paraffin-embedded tissue specimens with conventional and immunohistochemical analyses, was assessed by an experienced neuropathologist without the knowledge of preoperatively established possible diagnoses.

Statistical Package for Social Sciences for Windows 10,0 (SPSS) was used for statistical evaluation. Possible diagnoses assessed by radiological and scintigraphic evaluation were compared with histopathological diagnoses

RESULTS

All lesions were hypodense on CT images. 4 cases (25%) showed minimal contrast enhancement in which 2 had minimal mass effect. Of 12 non-enhancing cases only 2 had mild mass effect. For enhancing and/or mass effect showing cases possible diagnoses were glioma and cerebritis. One of these minimally enhancing cases has been treated with surgery and radiotherapy due to a glioma. Mass effect was not observed on CT scans. As a matter of course first possible diagnosis for this case was radiation necrosis. Other 10 cases did not show contrast enhancement and mass effect either. Possible diagnoses for these cases were infarct and gliosis but cerebritis and glioma diagnoses could not be eliminated.

On T1 weighted (T1W) MR images 12 (75%) cases had hypointense and 4 (25%) had isointense lesions. On T2W image 3 (18,75%) had hypointense and 13 (81,25%) cases had hyperintense lesions. 5 (31,25%) cases showed minimal contrast enhancement and 3 of these had minimal mass effect. 10 (62,25%) cases did not show contrast enhancement and mass effect. Possible diagnoses for these minimally enhancing cases were cerebritis and glioma. One of these cases had possible diagnosis of radiation necrosis and showed only minimal enhancement, thus possible diagnosis for this case persisted. For these 10 cases without contrast enhancement and mass effect possible diagnoses were infarct and gliosis but cerebritis and glioma could not be eliminated again.

During MRS analysis all cases showed low NAA levels. Choline levels were high in 10 cases, low in 4 cases and unchanged in 2. Creatine levels were low in 10 cases and normal in 4 cases. Possible diagnoses of 10 cases with high choline levels were cerebritis and glioma. In cases with normal or low choline

levels possible diagnoses were infarct and gliosis. In MRS analysis 4 (25%) cases had different possible diagnoses than of CT and MR evaluation. In these cases NAA and choline levels were low and possible diagnoses were cerebritis and glioma. Case 11 has previously been operated due to glioma and as a consequence, showed mild enhancement on MR images. MRS analysis showed high choline and low NAA levels so recurrence of glioma was offered as possible diagnosis and that was confirmed by histopathological evaluation.

In 3 cases that was possibly diagnosed as infarct by radiological evaluation brain SPECT analysis with ^{99m}Tc -HMPAO showed hypoactivity. These results offered infarct as possible diagnosis for mentioned cases. Other cases were studied with ^{99m}Tc -sestamibi. One of them showed hyperactivity and possible diagnosis for this case was glioma. This was 1 of 10 cases possibly diagnosed as glioma by radiological evaluation. The rest had normal brain activity and no possible diagnosis was established for these cases by brain SPECT.

Stereotaxic biopsies reached histopathological diagnosis in 15 of 16 patients (93,75%). 7 (43,75%) were low grade glioma, 3 (18,75%) were infarct, 2 (12,50%) were gliosis, 1 (6,25%) was high grade glioma, 1 (6,25%) was recurrent glioma and 1 (6,25%) was cerebritis. 1 (6,25%) case could not be diagnosed. During biopsy procedures no complications were experienced.

Five cases with histopathological diagnosis of glioma were operated. Histopathological evaluation of these patients following open surgery confirmed stereotaxic biopsy results. Other 4 cases stereotactically diagnosed as glioma received radiotherapy.

All of 5 cases with infarct and gliosis diagnoses showed no lesion progression within one-year follow-up.

The case with cerebritis diagnosis was treated with adequate antibiotics and follow-up MRI revealed regression of the lesion.

For the possible diagnoses of CT and MRI evaluations 10 of 15 were confirmed by histopathological results.

MRS diagnoses results were better. 14 of 15 possible diagnoses were confirmed by

histopathological evaluation. One case with low choline and NAA levels was thought to be infarct or gliosis but histopathological diagnosis was dysembryoplastic neuroepithelial tumor (DNET) (Table I).

Statistical analyses demonstrated CT and MRI evaluations to have 66.67% sensitivity and 62.50% specificity. MRS was shown to have 99.93% sensitivity and 87.50% specificity. Brain SPECT results showed 26.67% sensitivity and 25.00% specificity.

DISCUSSION

Intracranial hypodense lesions include a wide group of pathologies with similar radiological imaging properties but different structures and characteristics. These intraaxial, minimally or non-enhancing lesions look hypodense on CT without remarkable mass effect. Although lesion borders, contrast enhancement and tissue characteristics may be well explained by MRI, these non-specific findings will not help to ascertain the specific diagnosis (20, 24).

In a study with 314 glioma cases 58 of cases did not show enhancement on MRI and 30% of these cases were high-grade gliomas (19). In our study 5 of 10 non-enhancing lesions were low-grade gliomas. These lead to the inefficacy of standard MRI for diagnosis and grading of gliomas. Frank et al. analysed 50 cerebral lesions possibly diagnosed as glioma and compared diagnostic values of MRI, MRS and PET. In this study sensitivity of MRI was reported as 68% (7). Because histology and tumour grade strongly influence therapy, an accurate diagnostic modality is mandatory. Since late 1980's MRS is a widely used radiological modality. For many neurodegenerative diseases, for the response of the tumor to radio/chemotherapy and for radiologically unidentified lesions MRS supplies highly valuable data (5, 17). MRS offers a risk-free method for the diagnosis of brain lesions by providing biochemical information related to mitotic cell division (choline), displacement of neural tissue (NAA), energy metabolism (creatine) and necrosis (lipids) (22). But in previous studies it is also shown that different spectral patterns are not associated with particular tumor types (15). Highest reported sensitivity of MRS was 96% in the literature. Ricci et al. reported 8 cases with histopathological malignant

diagnosis but previously diagnosed as non-neoplastic by MRS (18). In the present study 14 of 15 cases had accurate discrimination of neoplastic/non-neoplastic disease. This means a sensitivity of 93%, compatible with previous reports.

High levels of choline are associated with malignant activity (23). In our study all glioma cases showed significant increase of choline.

Infarcts were reported to show decreased NAA levels and lower levels of NAA and creatine are associated with more severe infarct (6,13,16).

Though a promising advance, several limitations potentially compromise the efficacy of MRS as a diagnostic tool. Intraparenchymal calcification, adjacent bone tissue, necrosis and haemorrhage, tissue heterogeneity, partial volume effects and edema may alter the MRS signal causing in wrong diagnosis (8,22).

Functional imaging modalities, such as SPECT and PET, have received considerable attention in detecting and even in grading of gliomas (9). Newly developed tracers and gamma camera systems better describe the biological behaviour and the metabolic activity of tumors and enable the successful evaluation. Baillet and Ak have studies on ^{99m}Tc-sestamibi. They proved the relation of increased tracer uptake in high aneuploidy of DNA in tumor and so high degree of malignancy (1,3). Another study showed ^{99m}Tc-sestamibi SPECT has 73% sensitivity and 85% specificity (11). In our study 7 cases with benign lesions did not show ^{99m}Tc-sestamibi uptake. Only one case with glioblastoma presented uptake of the tracer. Another case radiologically diagnosed as radiation necrosis did not uptake ^{99m}Tc-sestamibi, but histopathological diagnosis was recurrence of glioma.

Patients initially treated by external radiotherapy for cerebral glioma inevitably develop clinical symptoms, generally neurological symptoms compatible with tumor recurrence or radiation-induced necrosis. It's often difficult to distinguish radiation necrosis and tumor recurrence. They could have the same clinical and imaging aspects but the distinction between these two causes of neurological deterioration is crucial for the subsequent therapeutic decision-making (2,4,12). In the present study MRS was successful in distinguishing radiation necrosis and recurrence of tumor.

Table 1: Results of all Evaluations (NE: Not Established)

Case #	Density	Intensity		Enhancement		Mass effect		Possible diagnoses	MRS				SPECT		Stereotaxic biopsy	
		T1W	T2W	CT	MRI	CT	MRI		Choline	Creatine	NAA	Possible diagnoses	Activity	Possible diagnoses		
1	Hypo	Iso	Hypo	—	—	—	—	Infarct, gliosis	↓	↓	↓	↓	Infarct, gliosis	Hypo	Infarct	Infarct
2	Hypo	Hypo	Hyper	—	—	—	—	Infarct, gliosis	↑	↓	↓	↓	Glioma, cerebritis	N	NE	Grade II Astrocytoma
3	Hypo	Hypo	Hyper	—	—	—	—	Infarct, gliosis	↑	N	↓	↓	Glioma, cerebritis	N	NE	Grade I Astrocytoma
4	Hypo	Hypo	Hyper	Minimal	Minimal	Minimal	Minimal	Glioma, cerebritis	↑	↓	↓	↓	Glioma, cerebritis	N	NE	Grade II Oligodendroglioma
5	Hypo	Hypo	Hyper	—	Minimal	Minimal	Minimal	Glioma, cerebritis	↑	↓	↓	↓	Glioma, cerebritis	Hyper	Glioma	High grade glioma
6	Hypo	Hypo	Hyper	—	—	—	—	Infarct, gliosis	↓	↓	↓	↓	Infarct, gliosis	N	NE	DNET
7	Hypo	Hypo	Hyper	—	—	—	—	Infarct, gliosis	↑	N	↓	↓	Glioma, cerebritis	N	NE	Grade I Astrocytoma
8	Hypo	Hypo	Hypo	—	—	—	—	Infarct, gliosis	↓	N	↓	↓	Infarct, gliosis	Hypo	Infarct	Infarct
9	Hypo	Hypo	Hyper	—	Minimal	Minimal	Minimal	Glioma, cerebritis	↑	↓	↓	↓	Glioma, cerebritis	N	NE	Grade I Oligodendroglioma
10	Hypo	Hypo	Hypo	—	—	—	—	Infarct, gliosis	↓	N	↓	↓	Infarct, gliosis	Hypo	Infarct	Infarct
11	Hypo	Hypo	Hyper	—	Minimal	Minimal	Minimal	Radiation necrosis, glioma	↑	↓	↓	↓	Radiation necrosis	N	NE	Glioma recurrence
12	Hypo	Hypo	Hyper	—	—	—	—	Infarct, gliosis	N	N	↓	↓	Infarct, gliosis	N	NE	Gliosis
13	Hypo	Hypo	Hyper	Minimal	Minimal	Minimal	Minimal	Glioma, cerebritis	↑	↓	↓	↓	Glioma, cerebritis	N	NE	Grade II Oligoastrocytoma
14	Hypo	Hypo	Hyper	Minimal	Minimal	Minimal	Minimal	Glioma, cerebritis	↑	↓	↓	↓	Glioma, cerebritis	N	NE	Cerebritis
15	Hypo	Hypo	Hyper	—	—	—	—	Infarct, gliosis	N	N	↓	↓	Infarct, gliosis	N	NE	Gliosis
16	Hypo	Hypo	Hyper	—	—	—	—	Infarct, gliosis	↑	↓	↓	↓	Glioma, cerebritis	N	NE	No diagnosis

For cases with infarct sensitivity of ^{99m}Tc-HMPAO was reported as 91% (21). In this study 3 of 3 (100%) cases with infarct showed hypoperfusion in ^{99m}Tc-HMPAO SPECT.

Image guided stereotaxic procedure is a sophisticated and qualified modality of diagnosing and treating intracranial lesions. It may be the gold standart to obtain a definite histopathological diagnosis in patients with unclear lesion origin with low mortality and morbidity rates. Complications include haemorrhage, seizures and broken instruments. Stereotaxic biopsy is known to result in a 7-15% failure rate due to sampling errors. Much as failure rate due to sampling errors increases in hypodense non-enhancing lesions, it was rather low in the present series (6,25%). Experience of the neurosurgeon will remarkably increase biopsy success (2,10,23,24).

CONCLUSION

Technological improvement turns all surgical applications into a less invasive fashion. For now it is not conceivable that MRS will replace the gold standard of image guided stereotaxic biopsy completely. However, MRS may be an alternative to make the diagnosis in patients with severe medical illness or older patients whom a stereotaxic biopsy to obtain a histological diagnosis is feasible but carries a high risk of adverse events.

REFERENCES

- Ak I, Gülbaş Z, Altınel F, Vardareli E: Tc-99m MIBI uptake and its relation to the proliferative potential of brain tumors. *Clin Nucl Med* 28:29-33, 2003
- Apuzzo MLJ, Chandrasoma PT, Cohen D: Computed imaging stereotaxy: Experience and perspective related to 500 procedures applied to brain masses. *Neurosurg* 20:930-937, 1987
- Baillet G, Albuquerque L: Evaluation of single-photon emission tomography imaging of supratentorial brain gliomas with technetium-99m sestamibi. *Eur J Nucl Med* 21(10):1061-1066, 1994
- Barai S, Bandopadhyaya GP, Julka PK, Naik KK, Haloi AK, Kumar R, Seith A, Malhotra A: Role of Tc-glucoheptonic acid brain single photon emission computed tomography in differentiation of recurrent brain tumour and post-radiation gliosis. *48(3):296-301, 2004*
- Castillo M, Kwoc L, Mukherji S: Clinical applications of MR spectroscopy. *AJNR* 17: 115-119, 1996
- Felber SR: H-1 magnetic resonance spectroscopy in intracranial tumors and cerebral ischemia. *Radiology* 33: 626-632, 1983
- Frank WF, Pauleit D: Multimodal metabolic imaging of cerebral gliomas: Positron emission tomography with fluoroethyl-L-tyrosine and magnetic resonance spectroscopy. *J Neurosurg* 102:318-327, 2005
- Krouer HG, Kim TA: Single-voxel proton MR spectroscopy of nonneoplastic brain lesions suggestive of a neoplasm. *AJNR* 25:346-355, 1994
- Kumar RA, Khandelwal N, Sodhi KS, Singh K, Pathak A, Mittal BR, RadotraBD, Suri S: Comparison Between Contrast-enhanced Magnetic Resonance Imaging and Technetium 99m Glucohepatonic Acid Single Photon Emission Computed Tomography With Histopathologic Correlation in Gliomas. *J Comput Assist Tomogr* 30:723-733, 2006
- Kutlay M, Colak A, Yildiz S, Demircan N, Akin ON: Stereotactic aspiration and antibiotic treatment combined with hyperbaric oxygen therapy in the management of bacterial brain abscesses. *Neurosurgery* 57:1140-1146, 2005
- Lamy LC, Dubois F, Blond S: Importance of cerebral tomoscintigraphy using technetium-labeled sestamibi in differential diagnosis of current tumor vs. radiation necrosis in supratentorial glial tumors in adults. *Neurochirurgie* 45(2):110-117, 1999
- Le Jeune FP, Dubois F, Blond S, Steinling M: Sestamibi technetium-99m brain single-photon emission computed tomography to identify recurrent glioma in adults: 201 studies. *J Neurooncol* 77(2):177-83, 2006
- Lin A, Bluml S, Mamelak AN: Efficacy of proton magnetic resonance spectroscopy in clinical decision making for patients with suspected malignant brain tumors. *J Neurooncol* 45:69-81, 1999
- Ostertag CB, Mennel HD, Kiessling M: Stereotactic biopsy of brain tumors. *Surg Neurol* 14:275-283, 1980
- Ott D, Henning J, Ernst T: Human brain tumors: Assessment with in vivo proton MR spectroscopy. *Radiology* 186:745-752, 1993
- Prost RBS, Haughton V, Li SJ: Brain tumors: Localized H-1 MR spectroscopy at 0,5 T. *Radiology* 204:235-238, 1997
- Rand SD, Prost R: Accuracy of single-voxel proton MR spectroscopy in distinguishing neoplastic from nonneoplastic brain lesions. *AJNR* 18:1695-1704, 1997
- Ricci PE, Pitt A, Keller PJ: Effect of voxel position on single-voxel MR spectroscopy findings. *AJNR* 21:367-374, 2000
- Scott JN, Brasher PM, Sevick RJ: How often are nonenhancing supratentorial gliomas malignant? A population study. *Neurology* 59:947-949, 2002
- Sencer S, İmer M, Sencer A, Karadereler S, Barlas O: Hypodense non-enhancing lesions: Histopathological diagnosis through CT-guided stereotactic brain biopsy. *Turkish Neurosurgery* 11:44-50, 2001
- Serena A, Nogueiras JM: Brain perfusion SPECT in the prognostic assessment of stroke. *Esp Med Nucl* 22(5):327-335, 2003
- Setzer M, Herminghaus S, Marquardt G, Tews DS, Pilatus U, Seifert V, Zanella F, Lanfermann H: Diagnostic impact of proton MR-spectroscopy versus image-guided stereotactic biopsy. *Acta Neurochir* 149:379-386, 2007
- Tadeshi G, Lundbom N, Raman R: Increased choline signal coinciding with malignant degeneration of cerebral gliomas: A serial proton MR spectroscopy imaging study. *J Neurosurg* 87:516-524, 1997
- Wilden JN, Kelly PJ: CT computerised stereotactic biopsy for low density CT lesions presenting with epilepsy. *J Neuro, Neurosurg, and Psychiatry* 50:1302-1305, 1987