

# Trigeminal Neuropathic Pain Following Honeybee Sting: A Case Report

## Arı Sokması Sonrası Trigeminal Nöropatik Ağrı: Olgu Sunumu

### ABSTRACT

The neurological complications of bee venom poisoning vary from optic neuritis to pontine hematoma. However, to our best knowledge, trigeminal neuropathic pain secondary to bee sting has not been reported previously in the literature. We report the case of a 52-year-old male patient with right-sided trigeminal neuropathic pain that began a month earlier, following a honeybee sting to the right forehead. The patient was successfully treated by CT-guided percutaneous trigeminal tractotomy. The present report demonstrated that a honeybee sting may result in trigeminal neuropathic pain and CT-guided percutaneous trigeminal tractotomy is effective in the treatment of such cases.

**KEYWORDS:** CT-guided tractotomy, Honeybee sting, Trigeminal neuropathic pain, Neurological complications

### ÖZ

Arı sokmasına bağlı nörolojik komplikasyonlar optik nöritten pontin hematoma kadar değişen klinik verebilirler. Ancak şimdiye kadar arı sokması sonrası trigeminal nöropatik ağrı gelişmesi literatürde sunulmamıştır. Olgumuzda, 52 yaşında erkek hastanın 1 ay önce yüzünün sağ tarafından arı sokmasını takiben, sağ tarafta trigeminal nöropatik ağrısının başlaması ve sonrasındaki tedavi protokolü sunulmuştur. Hasta BT yardımcı perkütanöz trigeminal traktotomi tekniği ile başarılı bir şekilde opere edilmiştir. Sunulan çalışmada arı sokması sonrası nöropatik ağrının gelişebileceği ve bu gibi vakalarda BT yardımcı perkütanöz trigeminal traktotominin etkili bir tedavi yolu olacağı gösterilmiştir.

**ANAHTAR SÖZCÜKLER:** BT-yardımlı traktotomi, Arı sokması, Trigeminal nöropatik ağrı, Nörolojik komplikasyonlar

Gokmen KAHİLOGULLARI<sup>1</sup>

Hasan Caglar UGUR<sup>2</sup>

Mehmet TATLI<sup>3</sup>

Yucel KANPOLAT<sup>4</sup>

<sup>1,2,4</sup> Ankara University, Faculty of Medicine, Department of Neurosurgery, Ankara, Turkey

<sup>3</sup> Dicle University, Faculty of Medicine, Department of Neurosurgery, Diyarbakir, Turkey

Received : 09.03.2009

Accepted : 20.07.2009

Correspondence address:

Gokmen KAHİLOGULLARI

E-mail : gokmenkahil@hotmail.com

## INTRODUCTION

According to the International Association for the Study of Pain, the term of 'neuropathic pain' refers to a group of painful disorders strictly characterized by severe pain caused by diseases of the central or peripheral nervous system (7,8,25,33). A recent proposal suggested that the definition should refer to an injury either in the peripheral or in the central nervous system or both, and it could be associated with various sensory and/or motor phenomena (7). When the pain is located in the head, the term of 'craniofacial neuropathic pain' is used to describe the main area involved in the syndrome (8).

It is known that multiple types of nerve injuries result in neuropathic pain, including infections, trauma, metabolic abnormalities, chemotherapy, radiation, surgery, neurotoxins, nerve compression and tumor infiltration (11). However, to date, trigeminal neuropathic pain caused by a honeybee sting has not been reported in the literature.

In the present paper, we reported a case of trigeminal neuropathic pain following a honeybee sting in a patient who was successfully treated by CT-guided percutaneous trigeminal tractotomy.

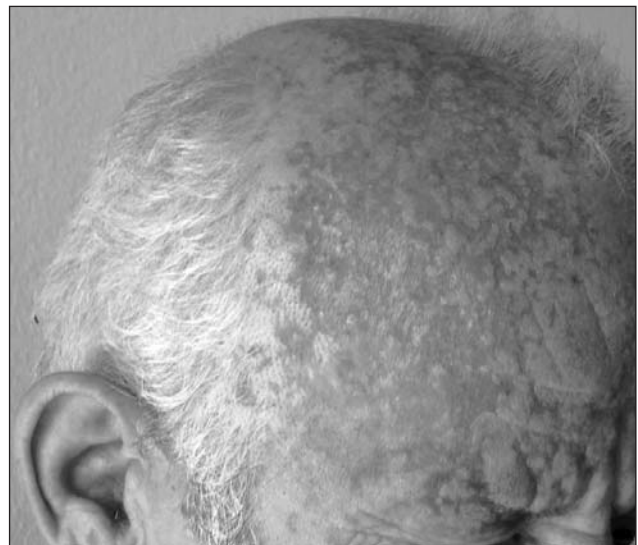## CASE REPORT

A 52-year-old man was admitted for a complaint of right-sided unremitting, severe facial pain. He had been stung on the right forehead by a honeybee a month before admission and received various drugs such as carbamazepine, tricyclic antidepressants and gabapentin. In addition, his face had been swollen but the swelling had resolved after three days. Ten day later, he had begun to suffer from hypoesthesia and burning sensation on the right side of his face. The pain was neuropathic with a paroxysmal pattern. On examination, we detected a hyperemia located on the first and second subdivisions of the right trigeminal nerve. VAS (Visual analogue scale) was 80 before the operation. Pseudobulloid-knobby lesions with a red-brown color were also detected on the same areas (Figure 1). All laboratory tests were within normal limits. His neuroradiological findings were normal. The neurological and physical findings were consistent with trigeminal neuropathic pain. After the diagnosis, a carbamazepine (800 mg/day) and gabapentin (900 mg/day) combination was started for a month, but the clinical consequences were

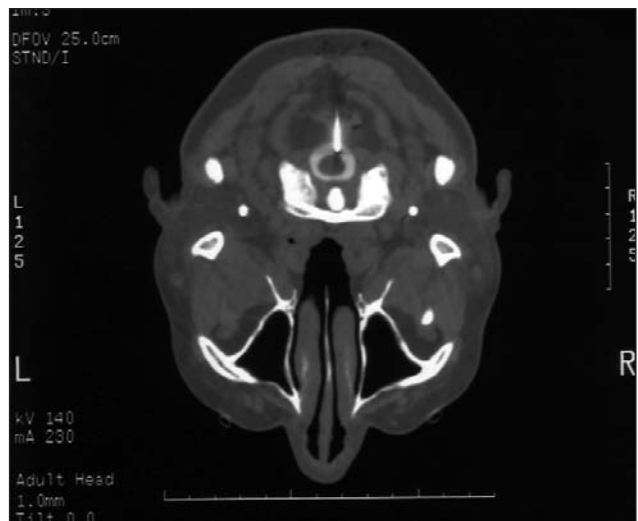
disappointing. He therefore underwent CT-guided percutaneous trigeminal tractotomy 45 days after the bee sting (Figure 2). The operation was uneventful. After the operation, the neuropathic pain disappeared whereas hypoesthesia remained on the areas of first and second subdivisions of the right trigeminal nerve, and the burning sensation around the right ear persisted. VAS score was 30 after the operation.

## DISCUSSION

The main clinical manifestations of bee venom poisoning are local allergic reactions at the site of the sting such as edema, erythema and burn-like



*Figure 1: The patient's pseudobulloid-knobby lesions with red-brown color on the right side of his face.*



*Figure 2: The location of the needle-electrode system in this case for the CT-guided percutaneous trigeminal tractotomy procedure (axial CT section).*

sensation, generalized reactions which include pruritis, urticaria, angio-edema and, in extreme cases, anaphylactic shock (10). However, some unusual neurological complications such as myasthenia gravis, peripheral neuritis, encephalomyelitis, optic neuritis, cerebral infarction, parkinsonism, pontine hematoma, thalamic and mesencephalic hemorrhages as well as the Guillain-Barre syndrome related to stings have been also reported in the recent literature (1,2,4,9,14,22,29-32).

In spite of above-mentioned neurological manifestations, trigeminal neuropathic pain secondary to bee sting has not been reported previously. This is the first report of trigeminal neuropathic pain following a honeybee sting. The patient was treated by CT-guided percutaneous trigeminal tractotomy. The surgical result was satisfactory as in other conditions such as atypical facial pain (19). Because of the normal radiological and laboratory findings, the patient's history and neurological features, we assume that bee venom can cause trigeminal neuropathic pain. We consider it important that the general public and physicians should be aware of the serious complications of bee sting.

It is known that the main toxin in bee venom is mellitin, a strongly basic compound with strong surface activity. It is believed that its hemolytic effect is related to its effect on increasing permeability in erythrocytes and other cells. Three other polypeptide toxins (apamine, mast cell-degranulating peptide, and minimine) have also been identified. To some authors (24), the mechanism after nerve injury involves impaired function of both small unmyelinated fibers and large myelinated fibers, and hyperalgesia occurs with the sensitization of peripheral C nociceptors while other authors (28) postulate potential cross reactivity between venom constituents and central nervous system myelin as the mechanism for the reaction. On the other hand, no recommendations have been made regarding venom testing for insect venom exposure. The reactions such as acute encephalomyelitis and the Guillain-Barre syndrome have been described following one or two insect stings, but their mechanisms are not evident. The authors have reported that anti-myelin antibodies have been detected on several occasions, but the importance of their presence is unclear (28).

The main clinical features of neuropathic pain are a combination of symptoms and signs such as pain in areas with sensory loss, hyperexcitability and sympathetic involvement as well as summation of pain. Although textbooks and articles explain a lot of facial pain types (11,15,23), Burchiel (5,6) stated that trigeminal neuropathic pain is unintentional and seen with incidental trauma, non-triggerable, and unremitting unilateral facial pain. Its pathophysiology is explained with painful nerve injury of the distal trigeminal nerve. In our case, the pathogenesis of the trigeminal neuropathic pain may be explained with bee venom neurotoxicity.

Medical treatments and surgical procedures can be used for trigeminal neuropathic pain. Tricyclic antidepressants, gabapentin, intrathecally local anaesthetics and corticosteroids are the medical treatments used. In the surgical approach, peripheral neurectomy, percutaneous gangliolysis, motor cortex stimulation, stereotactic trigeminal nucleotomy, stimulation of the Gasserian ganglion and trigeminal rootlets are used for trigeminal neuropathic pain (3,12,13,16,18,20,21,26,27). However, we performed CT-guided trigeminal tractotomy for the treatment of this special case. The procedure is not only an effective procedure in denervating pain areas of the 5th, but also for pain areas of the 7th, 9th, and 10th nerves and nucleus caudalis (17).

Our surgical timing may be considered as early surgery and might be criticized. Nevertheless, we feel it had to be performed because the pain was unbearable and unremitting.

## CONCLUSION

In conclusion, the present report demonstrated that a honeybee sting may result in trigeminal neuropathy and/or neuropathic pain in the first and second branches of trigeminal nerve. In addition, it showed that CT-guided percutaneous trigeminal tractotomy may be effective in the treatment of trigeminal neuropathic pain syndrome caused by unusual cause like a honeybee sting.

## REFERENCES

1. Ashworth B: Encephalopathy follows a sting. *J Neurol Neurosurg Psychiatry* 27: 542-546, 1964
2. Boz C, Velioglu S, Ozmenoglu M: Acute disseminated encephalomyelitis after bee sting. *Neurol Sci* 23: 312-315, 2003

3. Brown JA, Pilitsis JG: Motor cortex stimulation for central and neuropathic facial pain: A prospective study of 10 patients and observations of enhanced sensory and motor function during stimulation. *Neurosurgery* 56: 290-297, 2005
4. Brumlik J: Myasthenia gravis associated with wasp sting. *JAMA* 235: 2120-2121, 1976
5. Burchiel KJ: Trigeminal neuropathic pain. *Acta Neurochir Suppl (Wien)*. 58: 145-149, 1993
6. Burchiel KJ: A new classification for facial pain. *Neurosurgery* 53: 1164-1167, 2003
7. Cavenagh J, Good P, Ravenscroft P: Neuropathic pain: Are we out of the woods yet? *Intern Med J* 36: 251-255, 2006
8. Colombo B, Annovazzi PO, Comi G: Neuropathic cranial pain. *Neurol Sci Suppl* 24: 132-137, 2003
9. Crawley F, Schon F, Brown MM: Cerebral infarction: A rare complication of wasp sting. *J Neurol Neurosurg Psychiatry* 66: 550-551, 1999
10. Day JM: Death due to cerebral infarction after wasp stings. *Arch Neurol* 7: 184-186, 1962
11. Dworkin RH: An overview of neuropathic pain: syndromes, symptoms, signs, and several mechanisms. *Clin J Pain* 18: 343-349, 2002
12. Ebel H, Rust D, Tronnier V, Boker D, Kunze S: Chronic presentral stimulation in trigeminal neuropathic pain. *Acta Neurochir (Wien)* 138: 1300-1306, 1996
13. Elias WJ, Burchiel KJ: Trigeminal neuralgia and other neuropathic pain syndromes of the head and face. *Curr Pain Headache Rep* 6: 115-124, 2002
14. Goldstein NP, Rucker W, Klass DW: Encephalopathy and papilledema after bee sting. *JAMA* 188: 1083-1084, 1964
15. Graff-Radford S: Facial pain. *Curr Opin Neurol* 13: 291-296, 2000
16. Johnson MD, Burchiel KJ: Peripheral stimulation for treatment of trigeminal neuralgia and trigeminal posttraumatic neuropathic pain: a pilot study. *Neurosurgery* 55: 135-142, 2004
17. Kanpolat Y, Deda H, Akyar S, Caglar S, Bilgic S: CT-guided trigeminal tractotomy. *Acta Neurochir (Wien)* 100: 112-114, 1989
18. Kanpolat Y, Savas A, Bekar A, Berk C: Percutaneous controlled radiofrequency trigeminal rhizotomy for the treatment of idiopathic trigeminal neuralgia: 25-year experience with 1600 patients. *Neurosurgery* 48: 524-534, 2001
19. Kanpolat Y, Savas A, Ugur HC, Bozkurt M: The trigeminal tract and nucleus procedures in treatment of atypical facial pain. *Surg Neurol Suppl* 64: 96-100, 2005
20. Law JD, Sweet J, Kirsch WM: Retrospective analysis of 22 patients with chronic pain treated by peripheral nerve stimulation. *J Neurosurg* 52: 482-485, 1980
21. Liu H, Tsai S, Kao M, Hu JS: Botulinum toxin a relieved neuropathic pain in a case of post-herpetic neuralgia. *Pain Medicine* 7: 89-91, 2006
22. Maltzman JS, Lee AG, Miller NR: Optic neuropathy occurring after bee and wasp sting. *Ophthalmology* 107: 193-195, 2000
23. Maxwell RE: Clinical diagnosis of trigeminal neuralgia and differential diagnosis of facial pain, in Rovit RL, Murali R, Jannetta PJ (Eds). *Trigeminal neuralgia*. Baltimore, Williams and Wilkins, 1990: 53-77
24. Means ED, Barron K, Van Dyne BJ: Nervous system lesions after sting by yellow jacket. A case report. *Neurology* 23: 881-890, 1973
25. Merskey H, Bogduk N: Classification of chronic pain. Descriptions of chronic pain syndromes and definitions of pain terms. 2nd ed. Seattle: IASP Press, 1994: 209-214
26. Meyerson BA, Lindblom U, Linderth B, Lind G, Heerogods P: Motor cortex stimulation as treatment of trigeminal neuropathic pain. *Acta Neurochir Suppl (Wien)* 58: 150-153, 1993
27. Rasche D, Ruppolt M, Stippich C, Unterberg A, Tronnier VM: Motor cortex stimulation for long-term relief of chronic neuropathic pain: a 10 year experience *Pain* 121: 43-52, 2006
28. Reisman RE: Unusual reactions to insect stings. *Curr Opin Allergy Clin Immunol* 5: 355-358, 2005
29. Remes-Troche JM, Tellez-Zenteno JF, Rojas-Serrano J, Senties-Madrid H, Vega-Boada F, Garcia-Ramos G: Thalamic and mesencephalic hemorrhages after multiple honeybee stings: a life-threatening apitherapy complication. *Eur Neurol* 49: 188-189, 2003
30. Riggs JE, Ketonen LM, Bodensteiner JB, Benesch CG: Wasp sting-associated cerebral infarction: A role for cerebrovascular sympathetic innervation. *Clin Neuropharmacol* 16: 362-365, 1993
31. Schiffman JS, Tang RA, Ulysess E, Dorotheo N, Singh SS, Bahrani HM: Bilateral ischemic optic neuropathy and stroke after multiple bee stings. *Br J Ophthalmol* 88: 1596-1598, 2004
32. Starr JC, Brasher GW: Wasp sting anaphylaxis with cerebral infarction. *Ann Allergy* 39: 431-433, 1977
33. Zakrzewska JM: Classification issues related to neuropathic pain. *J Orofac Pain* 18: 325-331, 2004