

Received: 01.01.2011 / Accepted: 19.08.2011

DOI: 10.5137/1019-5149.JTN.4079-11.0

# Endovascular Treatments for Distal Posterior Cerebral Artery Aneurysms

## *Distal Posterior Serebral Arter Anevrizmalarının Endovasküler Tedavisi*

Qi LUO, Honglei WANG, Kan XU, Jinlu YU

*First Hospital of Jilin University, Department of Neurosurgery, Changchun, P.R. China*

Correspondence address: Jinlu YU / E-mail: jinluyu@hotmail.com

### ABSTRACT

**AIM:** The purpose of the current study was to evaluate the methods and results of endovascular treatments for distal posterior cerebral artery (PCA) aneurysms.

**MATERIAL and METHODS:** We studied 10 patients admitted to our hospital, of which 6 had aneurysms at the P2 segment (2 were saccular, 2 were fusiform, 2 were dissecting), 1 had a dissecting aneurysm at the P2-P3 junction and 3 had dissecting aneurysms at the P3 segment. Coil embolization was used for saccular aneurysms to retain parent arteries, stent was used for fusiform aneurysm to reconstruct the parent arteries, coil embolization in combination with parent artery occlusion was used for dissecting aneurysms at P2 segment or P2-P3 junction, aneurysm embolization in combination with parent artery occlusion by Glubran glue was used for dissecting aneurysms at the P3 segment.

**RESULTS:** Nine patients got a score of 5, one patient got a score of 4. DSA follow up in nine accepted the review (one patient with fusiform aneurysm at the P2 segment was lost). No reoccurrence was found.

**CONCLUSION:** The results of this study suggested that to achieve a satisfying prognosis, the types and locations of the aneurysms should be considered when performing the endovascular treatment for distal PCA aneurysms.

**KEYWORDS:** Distal posterior cerebral artery, Aneurysm, Endovascular treatments

### öz

**AMAÇ:** Endovasküler yoldan tedavi edilen distal posterior Serebral arter anevrizmalarının değerlendirilmesi.

**YÖNTEM ve GEREÇLER:** Posterior serebral arter anevrizması olan 10 hasta çalışmaya alındı. Anevrizmalardan 6'sı P2 bölümündeydi (Bunların 2'si sakküler, 2'si fusiform, 2'si disekan anevrizma şeklindeydi). Biri P2-P3 bileşkesinde disekan bir anevrizma, son 3'ü ise P3 bölümünde ve 3'ünde disekan anevrizma şeklindeydi. Kese şeklinde olan anevrizmalarda ana arter korunarak koil embolizasyonu, fusiform anevrizmalarda ana arter korunarak ana artere stent yerleştirilip ana arter rekonstrüksiyonu sağlandı. P2 bölümündeki veya P2-P3 birleşim noktasındaki disekan anevrizmalarda koil embolizasyonu ile parent arterin oklüzyonu sağlanmıştır. P3 bölümünden kaynaklanan disekan anevrizmalarda Glubran Zamki ile tıkanma sağlanmıştır.

**BULGULAR:** Hastaların 9'unda 5 skoru sağlandı, bir hastada ise 4 skoru sağlandı. Hastaların 9'una kontrol anjiyografisi yapıldı. Rekürrens saptanmadı. P2 segmentinde fusiform anevrizması olan bir hasta kaybedildi.

**SONUÇ:** Distal posterior serebral arter anevrizması olan hastalarda anevrizmanın tipi ve yerleşimi göz önüne alındığında endovasküler tedavi tatmin edici ve başarılı bir prognoz sağlamaktadır.

**ANAHTAR SÖZCÜKLER:** Distal posterior serebral arter, Anevrizma, Endovasküler tedavi

### INTRODUCTION

PCA aneurysms are uncommon, with an occurrence rate of less than 1% of intracranial aneurysms (6). Various shapes, including saccular, fusiform and dissecting aneurysms may occur in distal PCA, and may affect the whole artery (15,28,32). All of them make the treatment difficult. PCA is divided into the proximal segment and the distal segment by the confluence of the posterior communicating artery (20). Most aneurysms in PCA were reported in the distal segment of PCA (5,6,28). Aneurysms at the distal PCA are located deep and their complex peripheral anatomy makes the craniotomy clipping treatment very difficult with serious complications and high morbidity (34). The endovascular treatment under the guidance of digital subtraction angiography (DSA)

provided a safer and less invasive way with less adverse effects on the nerves and perforating branch arteries (18). However, the endovascular treatment experience is still lack of a well understanding, because the distal PCA aneurysms are uncommon. We studied 10 patients who were diagnosed as distal PCA aneurysms and accepted the endovascular treatment. The treatment for each case as well as the prognosis was summarized.

### MATERIAL and METHODS

#### 1. Baseline data

Ten patients were enrolled in the study. Of these ten patients (3 male and 7 female, age range 18-66 years old, mean age 47.1 years old), seven were found due to subarachnoid

hemorrhage (SAH) and three were admitted to the hospital because of headache. The PCA aneurysms were at the P2 segment in six patients, the P2-P3 junction in one case, and P3 segment in three cases. Two cases were diagnosed as PCA aneurysms accompanied with moyamoya disease (MMD). Of the ten aneurysms, 5 were smaller than 1.5cm, 4 were between 1.5cm and 2.4cm, another case was bigger than 2.5cm. Considering the shapes of the aneurysms, two of them were saccular, two were fusiform, and 6 were dissecting aneurysms. According to the Hunt-Hess grading criterion, the Grades of all the seven case with SAH before the operation were lower than Grade III. The two cases with headache had no neural dysfunction. Another patient with headache was misdiagnosed as cerebral tumor and accepted the exploratory craniotomy. Slight hemiparesis of the limbs were left after the operation (Gos score 4), but she can take care of herself.

## 2. Neurosurgical management

Surgeries were performed under intubation general anesthesia. Heparin was given immediately after the insertion of the sheath via Seldinger femoral artery puncture, with a first dosage of 5000U and an additional heparin (1000U) per hour later. Heparin (5000U / L) was also supplemented in the dropping salt solution (9). DSA was performed to localize the aneurysm and find the best angle for embolization during the surgery. Three-dimensional reconstruction technology was applied if necessary. Different treatments were selected based on the locations and shapes of the aneurysms. Generally speaking, for patients with saccular aneurysms, a coil was used to embolize the aneurysm with preservation of the parent artery. For patients with fusiform aneurysms, a Neuroform (Boston Scientific, Fremont, Calif) stent was used for reconstruction of the aneurysm cavity. For patients with dissecting aneurysm at P2 segment or P2-P3 junction, coil embolization of aneurysms and occlusion of the parent artery were performed. For patients with dissecting aneurysms at P3 segment, Glubran # 2 plastic (GEM srl, Viareggio, Italy) was used to embolize the aneurysms and occluding the affected parent artery.

## 3. Postoperative treatments

DSA was performed immediately after the surgery to observe the aneurysm and the compensatory collateral circulation of the affected arteries. Subcutaneous injection of low molecular weight heparin was performed for 5 days as an anticoagulant therapy (17). Neurological examinations were performed, including sensations, movements and visual abilities. For patients accompanied with SAH, lumbar drainage was kept for 7 days after surgery and nimodipine was pumped for 3 weeks intravenously (16). For patients with fusiform aneurysms who had accepted stent implantation, clopidogrel (75mg once daily for 3 months) and aspirin (100mg once daily for 6 months) were given to prevent thrombosis in the stent.

## RESULTS

### 1. Postoperative evaluations

1.1 Saccular aneurysms were found in two patients at the

P2 segment just beside the at the artery bifurcation accompanied with MMD. One patient got a visual field defect in the left eye after the operation due to the embolization of the branch derived from the affected artery. The other recovered well.

- 1.2 Fusiform aneurysms were found in two patients at the P2 segment. They recovered quite well after stent implantation.
- 1.3 Dissecting aneurysms at the P2 segment and the P2-P3 junction were found in three cases. They accepted the coil embolization and parent artery occlusion treatment. The treatments were succeeded but the postoperative visual field defect occurred in 2 patients.
- 1.4 The three patients with dissecting aneurysms at P3 segment were treated with 1: 3 Glubran # 2 glue embolization of aneurysm and parent artery occlusion, and recovered well.

### 2. Postoperative follow up

#### 2.1 DSA examinations

DSA follow up (range, 6 month ~ 1 year) was performed after the operation. Nine of the ten patients with distal aneurysms of the PCA accepted the review by DSA (one patient with fusiform aneurysm at the P2 segment was lost). No reoccurrence was found.

#### 2.2 GOS scoring

Neurological functions follow up was performed (range, 6 month ~ 1 year). The results were as follows: nine patients got a score of 5, one patient got a score of 4. Unfortunately, the three cases with visual defect did not recover (Table I).

## DISCUSSIONS

The junction of the PCA and the posterior communicating artery is the demarcation point between the proximal P1 segment and the distal P2-P4 segments. It is difficult to perform the craniotomy to treat the distal aneurysm due to the surrounding arteries supplying the brain stem and cranial nerves (11,13,22,25,35). On the contrary, endovascular treatment under the guidance of DSA is a minimally invasive alternative to cure the aneurysms with little effect on the branches supplying the nerves (6).

Treatments for distal PCA aneurysms have been challenging because of the various locations and types. In the literature, several investigators state that young patients with fusiform or big aneurysms are more common, and most of them located at the P2 segment (9,15,28,30,33). However, some other authors agreed that most of the saccular aneurysms are at the P2 segment while fusiform and dissecting ones can be found at all the segments from P2 to P4, and most of the patients are mid-aged (1,11,26). In our series, the mean age of the enrolled patients was 47.1 years. Six patients had aneurysms at the P2 segment including two saccular aneurysms, two fusiform and two dissecting aneurysms. One patient had

dissecting aneurysms at the P2-P3 segment. Three cases of dissecting aneurysms were located in the P3 segment. Different treatments have been employed depending on the locations and shapes of the aneurysms, including pure embolization, embolization accompanied with occlusion or stent reconstruction of the parent artery. This article reviewed 10 cases of distal PCA aneurysms during 5 years, to evaluate the methods and results of endovascular treatments.

The occurrence of the two aneurysms at the artery bifurcation of P2 segment was thought to be associated with MMD. Due to the complication of MMD, the posterior cerebral artery became the only blood supply for the whole brain and therefore, took a higher blood load which makes it susceptible to form saccular aneurysms. One patient was treated with coil embolization of the aneurysm with preservation of the parent artery. The other patient was a little complicated. Due to the presence of hematoma and pseudoaneurysm, it was difficult to embolize the real aneurysm tightly. The coil stuck in the pseudoaneurysm during the operation, so we

had to go on embolizing the pseudoaneurysm until it was strong enough to be outstretched into and embolize the real aneurysm (8,23). Unfortunately, the patient was left with a visual field defect because of the accidental embolization of an artery branch. Postoperative follow-up demonstrated that no recurrence was observed, and the visual defect did not recover either. Coil embolization accompanied with occlusion of the parent artery was a good choice to cure the saccular aneurysm (Figure 1A-F).

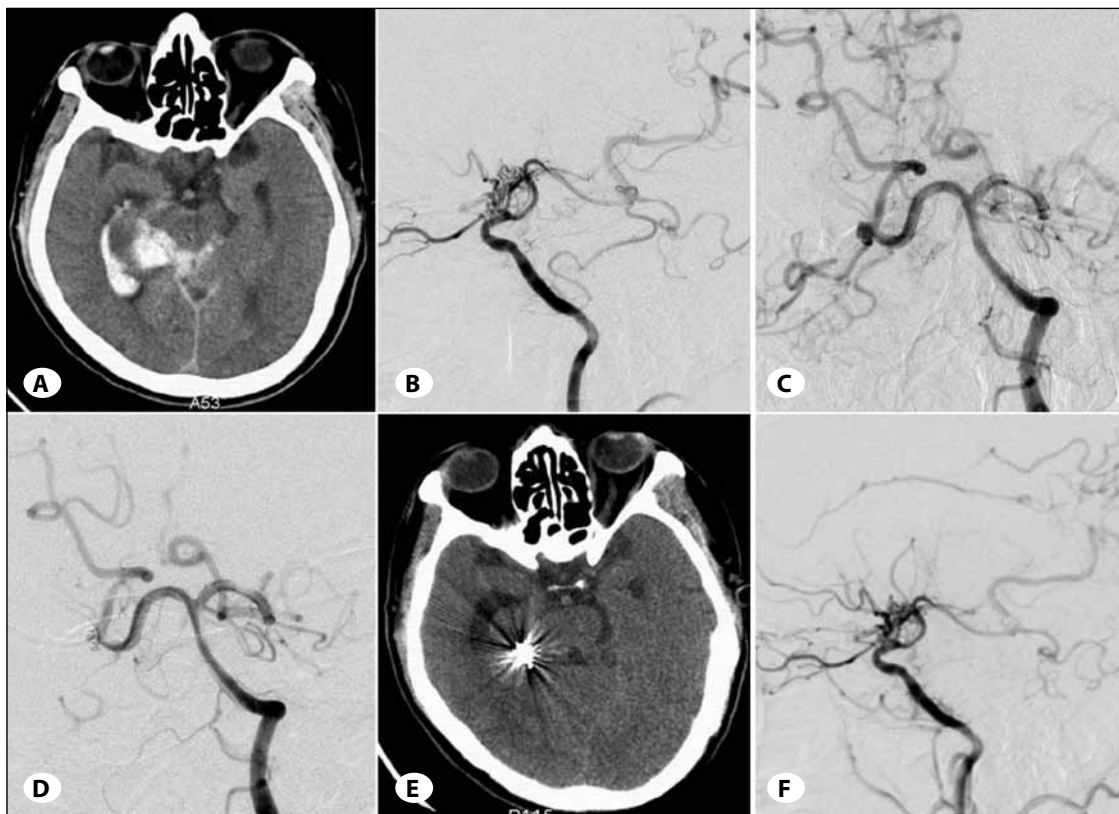
Fusiform aneurysms derived from the P2 segment of the PCA may be caused by atherosclerosis, dissection or infection (27, 31). The risk of hemorrhage in aneurysms caused by atherosclerosis is much higher than that of the dissecting aneurysms and aneurysms caused by infection (4,29,31). In this study, no obvious reasons were found in the two cases with fusiform aneurysms, so conservative treatments were not recommended. Available endovascular treatments for fusiform aneurysm include the reconstruction of the

**Table I:** Clinical Information of the 10 patients Enrolled in the Study

Case	gender/age	Presentation	Hunt-Hess Grade	Associated disease	Locations	Shapes	diameter (mm)	Treatment	Prognosis
1	F/56	SAH	II	MMD	Left PCA, P2	Saccular	4.2mm	Embolize the aneurysm by coils	GOS 5
2	M/53	SAH	II	MMD	Right PCA, P2	Saccular	4.5mm	Embolize the aneurysm by coils	GOS 5+Visual defect
3	F/42	SAH	II	None	Right PCA, P2	Fusiform	4.8mm	Neuroform (3mm×15mm)	GOS 5
4	F/66	SAH	II	None	Right PCA, P2	Fusiform	4.5mm	Neuroform (3mm×15mm)	GOS 5
5	M/18	SAH	II	None	Left PCA, P2	Dissecting	21mm	Embolize the aneurysm and the parent artery by coils	GOS 5+Visual defect
6	M/27	Headache	I	None	Left PCA, P2	Dissecting	16mm	Embolize the aneurysm and the parent artery by coils	GOS 5+Visual defect
7	F/41	Headache	I	None	Right PCA, P2-P3 junction	Dissecting	20mm	Embolize the aneurysm and the parent artery by coils	GOS 5
8	F/56	SAH	II	None	Left PCA, P3	Dissecting	2.5mm	Embolize the aneurysm and the parent artery by Glubran	GOS 5
9	F/55	SAH	II	None	Left PCA, P3	Dissecting	15mm	Embolize the aneurysm and the parent artery by Glubran	GOS 5
10*	F/57	Headache	I	None	Left PCA, P3	Dissecting	26mm	Embolize the aneurysm and the parent artery by Glubran	GOS 4

F, female; M, male. SAH, subarachnoid hemorrhage. MMD, moyamoya disease. PCA, posterior cerebral artery.

\*Case 10 was misdiagnosed as cerebral tumor and accepted the exploratory craniotomy. Slight hemiparesis of the limbs were left after the operation, but she can take care of herself before embolization treatment.



**Figure 1:** A case of saccular aneurysm at the P2 segment **A)** CT showed the bleeding and the hematoma behind the ambient cistern, the blood broke into the temporal horn of the lateral ventricle. **B)** DSA revealed the moyamoya disease. **C)** DSA demonstrated the irregular saccular aneurysm at the P2 segment of PCA which was considered to be accompanied with pseudoaneurysm; **D)** DSA imaging: The aneurysm was embolized completely; however, no contrast media was shown in the branched beside the aneurysm. **E)** Postoperative CT examination showed radio artifact of the coils, the hematoma was absorbed. **F)** DSA scan six months after the operation demonstrated that no aneurysm or re-flow in the branches beside the aneurysm as observed.

affected artery cavity using stents, reconstruction with stent in combination with coil embolization and coil embolization accompanied with occlusion of the parent artery (14,21,24). In both patients of our study, the arteries distal to the aneurysms were quite clear. Considering that the cerebral tissue may not be able to afford the ischemia if the parent artery was occluded, we chose the stent reconstruction therapy (7,12). Anticoagulant therapy was used to prevent thrombosis in the stent. Postoperative follow up showed that no further extension of the artery emerged. In conclusion, stent reconstruction therapy was recommended the patients with aneurysms at the P2 segment, if there was no stenosis in the parent artery and the distal arteries compensated well (Figure 2A-F).

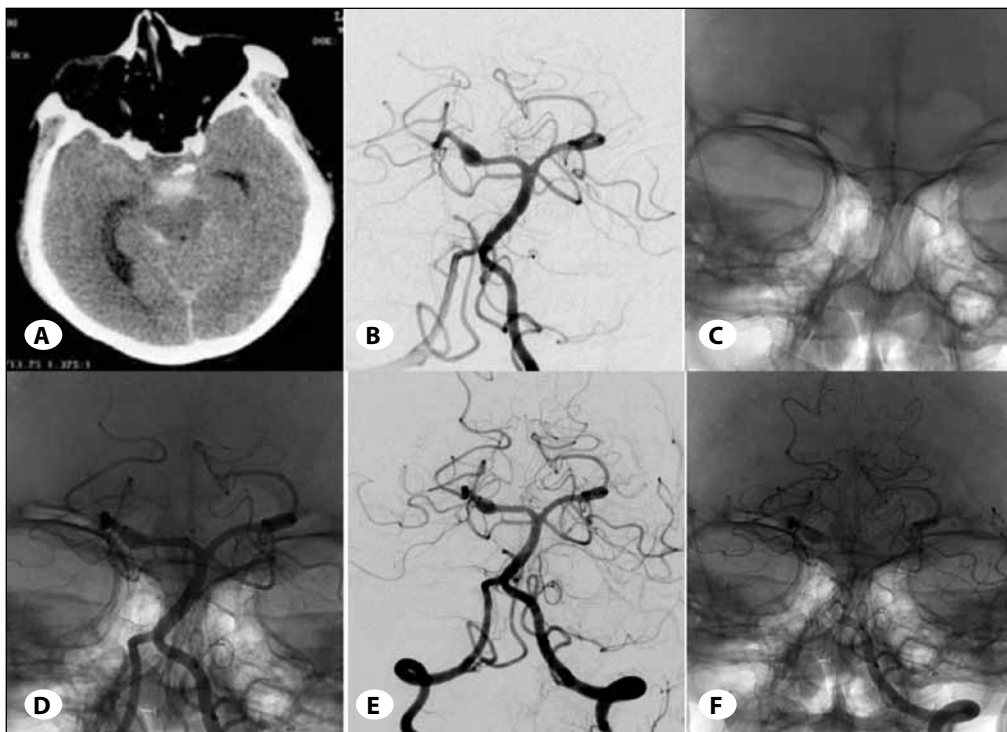
There were 3 cases of dissecting aneurysms at the P2 segment and the P2-P3 junction and 3 cases at the P3 segment in our series. The size of the aneurysms are usually quite big and the parent arteries are often narrow (11,15,30,32,33). However, the collateral circulations distal to the PCA are quite rich, such as the ventricle and the cortical branch of the other PCA, branches of the posterior choroid artery, branches of the middle and anterior cerebral arteries, branches of the circumflex arteries. Blood supply of the distal brain tissue can

be compensated by the opening of the collateral circulations (3,6,10,20,33), so we can embolize aneurysm and the parent artery in the operation (9, 21,28,30, 32, 33, 34) according to the anatomic character. It should be emphasized that one should never affect the artery distal to the aneurysm, which is critical to establish collateral circulation for compensation. The visual defect was considered to be related to the inadequate compensate circulation (2,6,19,20,33,36). In terms of details, for aneurysms derived from the P2 segment/P2-P3 junction, the blood pressure was quite high due to its proximity to the start point of the PCA, we would love to use coils to embolize the aneurysms and the parent artery. For aneurysms derived from P3 segment, due to the lower blood pressure, Glubran#2 gel was used to embolize aneurysms in combination with artery occlusion. All the patients achieved good prognosis except the two who got visual defect. The method was therefore effective for the dissecting aneurysms (Figures 3A-E, 4A-H).

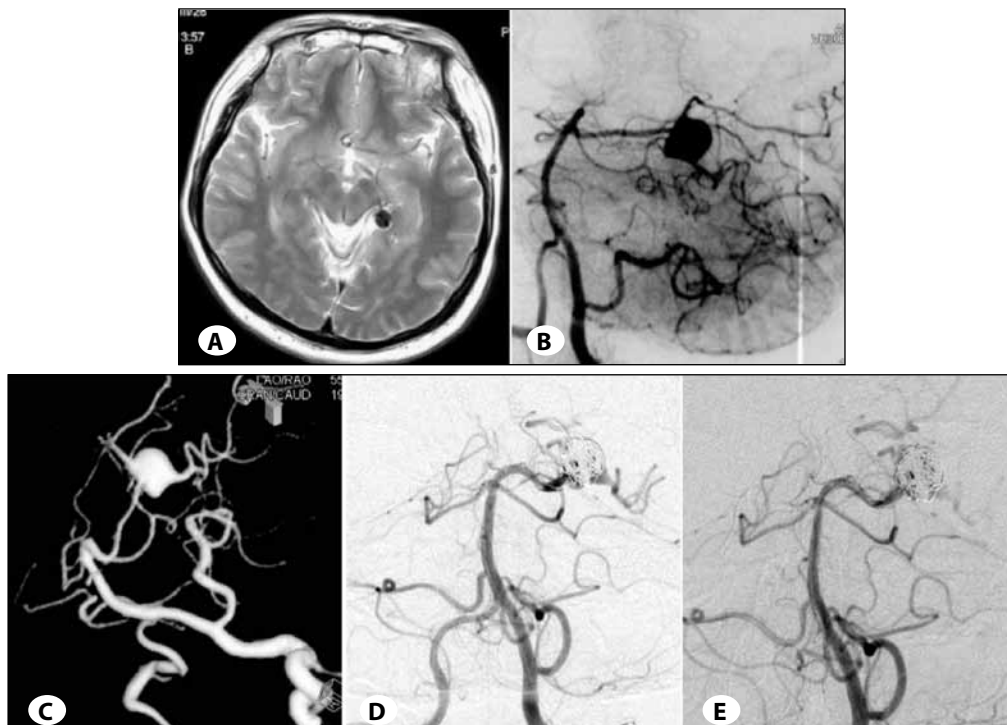
## CONCLUSIONS

Taken together, to achieve a satisfying prognosis, the types and locations of the aneurysms should be considered when performing the endovascular treatment for distal

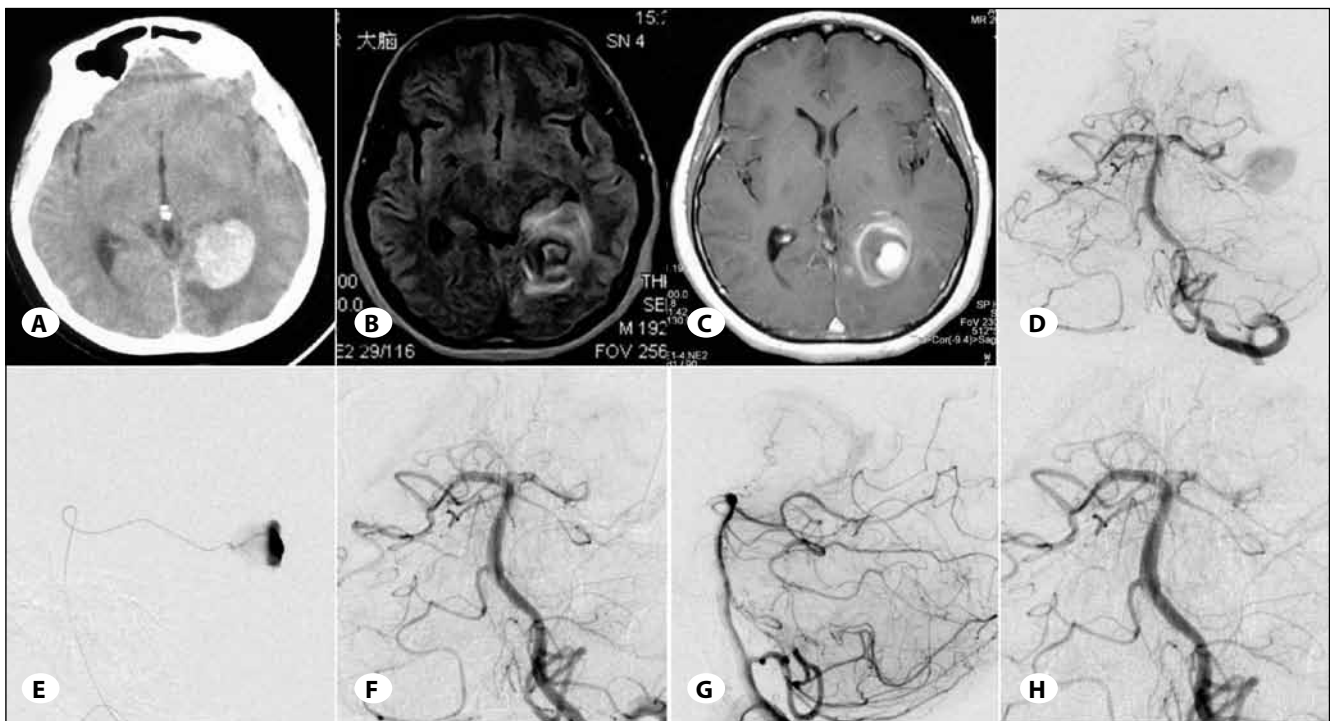




**Figure 2:** An fusiform aneurysm at the P2 segment **A)** CT examination demonstrated blood in the interpeduncular cistern and right to the ambient cistern. **B)** preoperative DSA examination revealed the presence of a fusiform aneurysm at the P2 segment of the right PCA. **C)** DSA showed the 4 mark points for releasing of the Neuroform stents(arrow). **D)** DSA shows the released stents in the aneurysm. **E)** No further expansion of aneurysm was observed during the postoperative DSA examination. **F)** postoperative DSA examination shows the stents are still in the aneurysm and the marker points are clear (arrow).



**Figure 3:** A dissecting aneurysm at the P2 segment **A)** Flow-void effect in the T2-weighted MRI examination suggesting the presence of aneurysm. **B)** The dissecting aneurysms at the P2 segment of PCA was shown in DSA imaging. **C)** The three-dimensional reconstruction of DSA images clearly demonstrated the presence of aneurysm, as well as the branch vessel derived from aneurysm. **D)** DSA examination showed aneurysm had already embolized; **E)** postoperative DSA demonstrated no aneurysm recurrence 6 months later.



**Figure 4** Dissecting aneurysm at the P3 segment **A)** preoperative CT demonstrates high-density in the triangle area of the left lateral ventricle and the patient was misdiagnosed as meningioma; **B** and **C)** Flow-void effect of the T2 weighted MRI images suggested the diagnosis of meningioma. C, Enhanced MRI showed the “bull’s-eye sign”. **D)** Preoperative DSA shows a dissecting aneurysm located in the P3 segment of the PCA. **E)** intraoperative DSA image reveals micro-catheter embolization of the aneurysm super-selectively; **F)** postoperative DSA image shows no contrast agent in the original aneurysm. The aneurysm was embolized completely. **G** and **H)** Six months later, DSA examination shows no aneurysm recurred.

PCA aneurysms. For patients with saccular aneurysms, coil embolization with preservation of the parent artery was recommended. For patients with fusiform aneurysms, stent reconstruction was better. For patients with dissecting aneurysm, aneurysms embolization accompanied with parent arterial occlusion was a good choice.

#### REFERENCES

1. Biondi A, Jean B, Vivas E, Le Jean L, Boch AL, Chiras J, Van Effenterre R: Giant and large peripheral cerebral aneurysms: Etiopathologic considerations, endovascular treatment, and long-term follow-up. *AJNR Am J Neuroradiol* 27:1685-1692, 2006
2. Ciceri EF, Klucznik RP, Grossman RG, Rose JE, Mawad ME: Aneurysms of the posterior cerebral artery: Classification and endovascular treatment. *AJNR Am J Neuroradiol* 22:27-34, 2001
3. Coert BA, Chang SD, Do HM, Marks MP, Steinberg GK: Surgical and endovascular management of symptomatic posterior circulation fusiform aneurysms. *J Neurosurg* 106:855-865, 2007
4. Day AL, Gaposchkin CG, Yu CJ, Rivet DJ, Dacey RG Jr: Spontaneous fusiform middle cerebral artery aneurysms: Characteristics and a proposed mechanism of formation. *J Neurosurg* 99:228-240, 2003
5. Drake CG, Amache AL: Aneurysms of the posterior cerebral artery. *J Neurosurg* 30: 468-474, 1969
6. Ferrante L, Acqui M, Trillo G, Lunardi P, Fortuna A: Aneurysms of the posterior cerebral artery: Do they present specific characteristics. *Acta Neurochir (Wien)* 138: 840-852, 1996
7. Gobin YP, Viñuela F, Gurian JH, Guglielmi G, Duckwiler GR, Massoud TF, Martin NA: Treatment of large and giant fusiform intracranial aneurysms with Guglielmi detachable coils. *J Neurosurg* 84: 55-62, 1996
8. Gupta R, Thomas AJ, Masih A, Horowitz MB: Treatment of Extracranial carotid artery pseudoaneurysms with stent grafts: Case series. *J Neuroimaging* 18: 180-183, 2008
9. Hallacq P, Piotin M, Moret J: Endovascular occlusion of the posterior cerebral artery for the treatment of p2 segment aneurysms: Retrospective review of a 10-year series. *AJNR Am J Neuroradiol* 23:1128-1136, 2002
10. Hanel RA, Boulos AS, Sauvageau EG, Levy EI, Guterman LR, Hopkins LN: Stent placement for the treatment of nonsaccular aneurysms of the vertebrobasilar system. *Neurosurgical Focus* 18:1-9, 2005
11. Hernesniemi J, Vapalahti M, Niskanen M, Tapaninaho A, Kari A, Luukkonen M, Puranen M, Saari T, Rajpar M: One-year outcome in early aneurysm surgery: A 14 years experience. *Acta Neurochir (Wien)* 122: 1-10, 1993

12. Higashida RT, Smith W, Gress D, Urwin R, Dowd CF, Balousek PA, Halbach VV: Intravascular stent and endovascular coil placement for a ruptured fusiform aneurysm of the basilar artery. Case report and review of the literature. *J Neurosurg* 87: 944-949, 1997
13. Honda M, Tsutsumi K, Yokoyama H, Yonekura M, Nagata I: Aneurysms of the posterior cerebral artery: Retrospective review of surgical treatment. *Neurol Med Chir (Tokyo)* 44: 164-169, 2004
14. Khayata MH, Aymard A, Casasco A, Herbreteau D, Woimant F, Merland JJ: Selective endovascular techniques in the treatment of cerebral mycotic aneurysms. Report of three cases. *J Neurosurg* 78 : 661-665, 1993
15. Kitazawa K, Tanaka Y, Muraoka S, Okudera H, Orz Y, Kyoshima K, Kobayashi S: Specific characteristics and management strategies of cerebral artery aneurysms: Report of eleven cases. *J Clin Neurosci* 8: 23-26, 2001
16. Klimo Jr P, Kestle J, MacDonald JD, Schmidt RH: Marked reduction of cerebral vasospasm with lumbar drainage of cerebrospinal fluid after subarachnoid hemorrhage. *J Neurosurg* 100: 215-224, 2004
17. Lubicz B, Bandeira A, Bruneau M, Dewindt A, Balériaux D, De Witte O: Stenting is improving and stabilizing anatomical results of coiled intracranial aneurysms. *Neuroradiology* 51: 419-425, 2009
18. Massoud TF, Guglielmi G, Viñuela F, Duckwiler GR: Saccular aneurysms in moyamoya disease: Endovascular treatment using electrically detachable coils. *Surg Neurol* 41: 462-467, 1994
19. Milisavljević M, Marinković S, Lolić-Draganić V, Djordjević L: Anastomoses in the territory of the posterior cerebral arteries. *Acta Anat (Basel)* 127: 221-225, 1986
20. Milisavljević M, Marinković S, Marinković Z, Malobabic S: Anatomic basis for surgical approach to the distal segment of the posterior cerebral artery. *Surg Radiol Anat* 10: 259-266, 1988
21. Mori K, Yamamoto T, Maeda M: Dissecting aneurysm confined to the anterior cerebral artery. *Br J Neurosurg* 16: 158-164, 2002.
22. Ng PY, Yeo TT: Petrosal approach for a large right posterior cerebral artery (P2) aneurysm. *J Clin Neurosci* 7:445-446, 2000
23. Nussbaum ES, Madison MT, Myers ME, Goddard J, Janjua T: Dissecting aneurysms of the posterior inferior cerebellar artery: Retrospective evaluation of management and extended follow-up review in 6 patients. *J Neurosurg* 109: 23-27, 2008
24. Pozzati E, Andreoli A, Limoni P, Casmiro M: Dissecting aneurysms of the vertebrobasilar system: Study of 16 cases. *Surg Neurol* 41: 119-124, 1994
25. Rhoton AL Jr: The supratentorial arteries. *Neurosurgery* 51(4 Suppl): S53-120, 2002
26. Roh HG, Kim SS, Han H, Kang HS, Moon WJ, Byun HS: Endovascular treatment of posterior cerebral artery aneurysms using detachable coils. *Neuroradiology* 50: 237-242, 2008
27. Sakamoto S, Shibukawa M, Kiura Y, Tsumura R, Okazaki T, Matsushige T, Kurisu K: Traumatic anterior communicating artery pseudoaneurysm with cavernous sinus fistula. *Acta Neurochir (Wien)* 151: 1531-1535, 2009
28. Sakata S, Fujii K, Matsushima T, Fujiwara S, Fukui M, Matsubara T, Nagatomi H, Kuromatsu C, Kamikaseda K: Aneurysm of the posterior cerebral artery: Report of eleven cases--surgical approaches and procedures. *Neurosurgery* 32:163-167,1993
29. Saket RR, Razavi MK, Sze DY, Frisoli JK, Kee ST, Dake MD: Stent-graft treatment of extracranial carotid and vertebral arterial lesions. *J Vasc Interv Radiol* 15: 1151-1156, 2004
30. Sanai N, Tarapore P, Lee AC, Lawton MT: The current role of microsurgery for posterior circulation aneurysms: A selective approach in the endovascular era. *Neurosurgery* 62: 1236-1249, 2008
31. Scott RM, Smith ER: Moyamoya disease and moyamoya syndrome. *N Engl J Med* 19:1226-1237, 2009
32. Taylor CL, Kopitnik TA Jr, Samson DS, Purdy PD: Treatment and outcome in 30 patients with posterior cerebral artery aneurysms. *J Neurosurg* 99:15-22, 2003
33. Umredkar A, Gupta SK, Khandelwal N, Chhabra R, Mathuriya SN, Pathak A, Tiwari MK, Mukherjee KK, Mohindra S, Singla N, Salunke P: Intracerebral infarcts following clipping of intracranial aneurysms: Incidence, clinical correlation and outcome. *Br J Neurosurg* 24:156-162, 2010
34. Uygur E, Atilla K, Levent G, Deniz B, Mustafa AS, Murad B: Subtemporal approach for a P2-P3 junction aneurysm of the posterior cerebral artery. *J Clin Neurosci* 14: 494-497, 2007
35. Van Rooij WJ, Sluzewski M, Beute GN: Endovascular treatment of posterior cerebral artery aneurysms. *AJNR Am J Neuroradiol* 27: 300-305, 2006
36. Wakhloo AK, Mandell J, Gounis MJ, Brooks C, Linfante I, Winer J, Weaver JP: Stent-assisted reconstructive endovascular repair of cranial fusiform atherosclerotic and dissecting aneurysms: Long-term clinical and angiographic follow-up. *Stroke* 39: 3288-3296, 2008